

Clinical report

Laparoscopic left lateral hepatectomy: the first case at Thammasat University, Thailand

Chatchai Mingmalairak

Department of Surgery, Faculty of Medicine, Thammasat University, Klongluang, Pathumthani 12120, Thailand

Background: A large incision of opened hepatectomy may cause many complications. Minimally invasive surgery of liver is challenging.

Objective: To present the first case of a benign liver tumor, hemangioma, operated with a novel technique of laparoscopic hepatectomy in Thailand.

Method: We report a 48-year-old female patient with chronic epigastric pain. A study of esophago-gastroduodenoscopy was normal. Ultrasound examination showed a mass of 6.5 cm in a left lobe of a liver. MRI and RBC scans showed hemangioma. Laparoscopic left lateral hepatectomy was performed.

Result: Duration of the operation was 4 hours with approximately 300 cc of blood loss. Post-operative recovery was good. The patient could return home within 5 days after the operation. There were no complications.

Conclusion: Laparoscopic left lateral hepatectomy for benign tumor case may be appropriate.

Keywords: Laparoscopic hepatectomy, left lateral hepatectomy, liver hemangioma.

Minimally invasive surgery is an alternative that patients and surgeons prefer where possible and effective. Since initiation of laparoscopic cholecystectomy (LC) by Hashizume et al. in 1987 [1], laparoscopic techniques have been applied to other organs such as hernia, thyroid, spleen, prostate, uterus, lung, kidney and liver. The first laparoscopic hepatectomy case was reported by Buell et al. in 1994 [2]. It was a laparoscopic wedge resection staging of lymphoma [3, 4]. Since then, various other operations have been reported. This report presents the first case of laparoscopic left lateral hepatectomy at Thammasat University Hospital, Thailand.

Case report

A female 48-year-old patient without any chronic illness came to the Thammasat University Hospital with a history of chronic epigastric dull pain for 6 months. The patient had been treated as dyspepsia but did not improve. Endoscopic examination of upper GI tract was performed and result was normal. Ultrasound showed a hyper-echoic mass of 6.5 cm

at the left lateral lobe of liver. Hemangioma was suspected. Additional examination with magnetic resonance imaging (MRI) and red blood cell (RBC) scan was performed (**Figs. 1, 2**). These confirmed hemangioma. Liver function test (LFT) results were within normal range. Tumor makers, such as alpha fetoprotein (AFP), carcinoembryonic antigen (CEA), carbohydrate antigen (CA) 19-9, were within the normal ranges. Hepatitis B and C virus were not found. The patient was diagnosed with symptomatic hemangioma of the left lateral lobe of the liver. The patient was prepared for the operation since symptoms remained.

Surgical Procedure

The patient was operated under general anesthesia. Nasogastric (NG) tube and a Foley catheter were inserted. The patient was placed on her back with arms kept close to the torso. The surgeon and the laparoscope holder stood on the right side of the patient. An assistant and a nurse, who passed instruments, stood on a left side. A 10 mm trocar was inserted at a midpoint between navel and xiphoid. Then, the other 4 trocars, comprised of a 10 mm trocar for retraction, clipper and dissector, and the other 3 trocars of 3 and 5 mm for grasper, were used (**Fig. 3**).

Correspondence to: Dr. Chatchai Mingmalairak, Department of Surgery, Faculty of Medicine, Thammasat University, Pahonyothin Rd., Klongluang, Pathumthani 12120, Thailand; E-mail: chatchaiming@yahoo.com

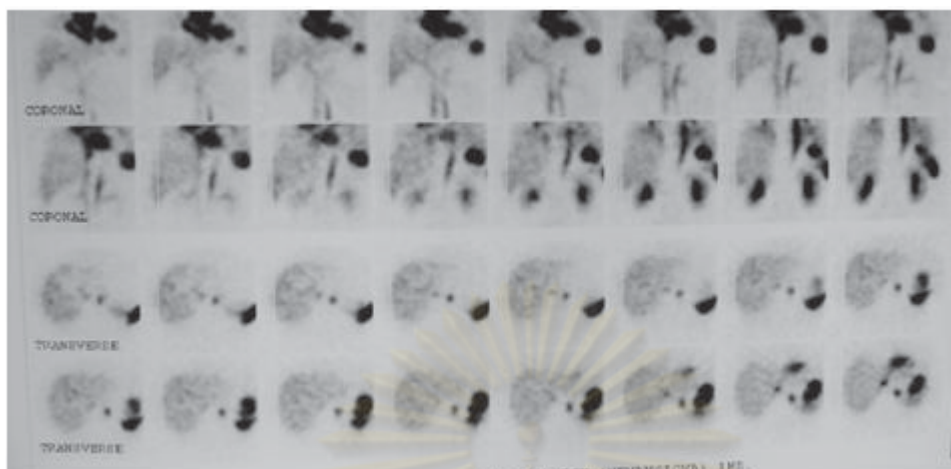


Fig. 1 RBC scan showed pooling of radioactive substance at the left lateral segment of liver.

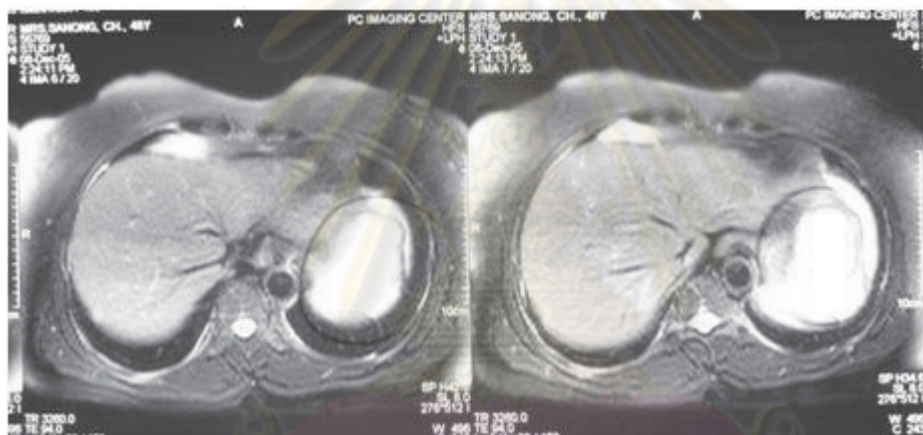


Fig. 2 MRI of liver suspected hemangioma at the left lateral segment of liver.

Pneumoperitoneum was performed with carbon dioxide using intraperitoneal pressure of 12 mm Hg. The Glisson capsule was identified and opened at both anterior and posterior ends by using electro-cautery. Then, dissection was performed to remove the liver mass by using a harmonic scalpel with another hand holding the suction to draw out the blood. When the blood vessels were found, an endo-clip of 10 mm was used to clamp the vessel before it was cut. The dissection was continued gently until the mass was separated completely. Raw surface bleeding was stopped by using an argon-plasma coagulator. After the final inspection, the specimen was put into a plastic bag and taken out through a new incision at a left groin area. A Jackson-Pratt drain was inserted through the 5 mm port hole at the surgical site to finish the operation. Duration of the operation was 4 hours with blood loss of approximately 300 cc. There was no immediate complication during the operation.

Post Operative Course

The patient could be extubated immediately after the operation and she was sent to ICU for observation for one night. All vital signs were within normal ranges. The patient could urinate well. On the next day, NG tube and Foley catheter were removed and the patient was discharged from the ICU and sent into a ward. The patient could stand up, start walking and sip water. When she could walk and eat normally, no bile or blood leaked through the Jackson Pratt Drain, the drain was removed. The patient could return home in day 5 after the date of the operation. On one week and one month follow-up the patient's condition was normal without any complication. Abdominal pain was improved. Post-operative and follow-up LFT results were within normal ranges. The pathological diagnosis of the tumor mass was cavernous hemangioma.

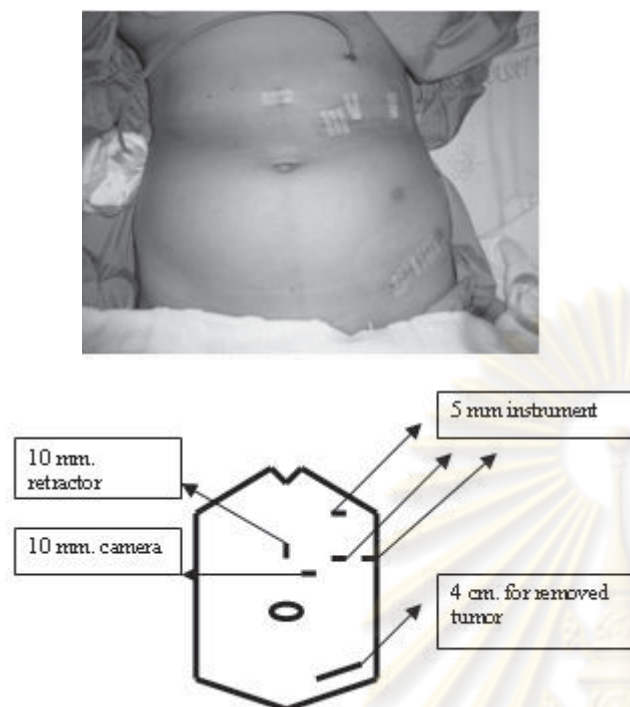


Fig. 3 Port placement of the present patient.

Discussion

Increasing experience has rapidly reduced the high operative mortality of hepatectomy from 25 % down to 5 % [4]. This is due to better surgical technique, care of critical patients, general anesthesia and advanced knowledge of blood supply of the liver following the Couinaud segments principle [5]. Operative blood loss, the major factor affecting the result of the operation, has been greatly reduced. Laparoscopic hepatectomy has been developed and initiated for 10 years. The first report was one of laparoscopic hepatic wedge resection for lymphoma staging in 1994 from the University of Maryland, USA [4]. Since then, there have been a number of reports of laparoscopic hepatectomy from many medical centers. Various techniques have been introduced for total laparoscopic operations [6, 7], which are appropriate for wedge, partial resection and left lateral hepatectomy. At present, hand-assisted laparoscopic hepatectomy [2] can be used for major resection. Thoracoscopic hepatectomy [8] is a new technique appropriate for lesions of the upper part of the liver [9], conditions where one needs to open the diaphragm. Indications in earlier reports advise laparoscopic operation in benign lesions and is contraindicated in malignant lesions and cirrhosis [1, 10]. Earlier reports prefer to place the patients on their side [11]. Currently,

however, the operation can be done with the patient lying on their backs [2]. The position of the surgeon is opposite to the side of the liver to be dissected.

“Opened technique” in inserting the port is suggested. For cirrhosis patients, it is recommended to open the first port under the navel to avoid perforation into the umbilical vein [1]. For normal patients, the first port should be opened at the position above the navel to reduce the distance between the port and the liver where the laparoscope might not be able to reach. In some series, a hand assisted device is utilized to assist vascular control and to facilitate hemostasis.

Utilizing a laparoscopic ultrasound probe [12] may be necessary for detecting tumors in different positions than those detected by computer tomography (CT) or MRI. Moreover, it can be used to assess how the tumor mass relates to the hepatic vein, vena cava and portal structure to allow dissection within 1 cm margin and avoid injury to vital organs [2].

Previous studies showed evidence that operative mortality rate was related to blood loss during operation [5]. Thus, bleeding control is of utmost importance. In Europe and Japan, vascular control is frequently done at the portal triad and hepatic outflow by using an umbilical tie [4]. In USA, hepatic vein control and porta-hepatis control are not utilized. The hand inside the abdomen might be used to do the Pringle maneuver when bleeding is a problem [2].

Major problems are bleeding and bile leakage. It is recommended to use an ultrasonic dissector [13]. The dissector can dissect blood vessels and small bile ducts of less than 2 mm [14]. An endovascular articulating stapler is used to dissect and tie blood vessels and bile ducts of greater sizes [3, 15, 16]. There are also other tools that have been developed. Some of these are: Liga Sure electrosurgical vessel-sealing device (Valleylab-Tyco Healthcare, Boulder, USA) [17], microwave coagulator (Alfreda Inc, Osaka, Japan) [13], laparoscopic coagulation shears (Ethicon Endo Surgery Inc, Cincinnati, USA) and FB 3.0 floating ball (Tissue Link Medical, Dover, USA) [10]. For blood oozing from the raw surface, argon beam coagulator (Bircher Inc, Tokyo, Japan) is used. There have been many reports of bile leakage; It is recommended to coat the liver cut surface with fibrin glue by using spray technique [2]. In the patient of this study, a harmonic scalpel was used in dissecting and 10 mm endo-clip was used to clamp the vein. As veins were not of the large size, stapler was not used

and argon beam was used to stop the raw surface blood oozing, no bleeding or bile leakage was found after operation.

Using carbon dioxide for creating pneumoperitoneum in liver operations, where the hepatic vein may be cut, causes concern over air embolism occurrence [14]. There was a report of air embolism in laparoscopic hepatectomy in pigs using intraperitoneal pressure of 12 mm Hg. In this experiment, no air embolism was found in the group of opened surgery [19]; but in human, such complication have not been reported yet. It is a common belief that the pressure of 12-15 mm Hg should be low enough in the human body since carbon dioxide can dissolve rapidly in the blood stream. Thus, the complication improbably occurs in humans [2]. However, in the group requiring dissection of moderate or larger size hepatic veins (or persistent foramen ovale), the airless lifting system technique should be used instead [1, 18].

The specimen should be placed in a plastic bag before removal [1]. In the hand-assisted group, it could be removed through the port hand-assist devices [2].

However, in all of the laparoscopic surgery groups, it could be removed in two different ways. The first way is to widen the wound at the subcostal port, and the second way is to make a new incision in the groin area to avoid disturbance of respiratory muscles. In this patient, the specimen had been removed through the groin (**Fig. 3**). Only slight pain could be felt when the patient breathed or coughed. Also, the patient could stand up and walk without pain.

Major complications from laparoscopic hepatectomy were bleeding, bile leakage, gas embolism, intestinal damage and hypercapnia [1]. There was also a diaphragmatic hernia resulting from injury during microwave-assisted laparoscopic hepatectomy was reported [20].

Previous publications on laparoscopic hepatectomy are reviewed and summarized in **Table 1**. Most of them were partial hepatectomy cases. Only a few series were major hepatic resection, except the hand-assisted group which preferred for major hepatic resection. The conversion rate and complications concerning hepatic resection were low.

Table 1. Review of laparoscopic hepatectomy.

| Studies | Cherqui, et al. [11] | Dulucq, et al. [21] | Kaneko, et al. [6] | Hashizume, et al. [1] | Buell, et al. [2] | Mala, et al. [22] | Cai, et al. [23] | Lesurtel, et al. [7] |
|--------------------------|----------------------|---------------------|--------------------|-----------------------|-------------------|-------------------|------------------|----------------------|
| Technique | total | total | total | total | hand-assisted | total | total | total |
| Number of patients | 30 | 31 | 52 | 70 | 100 | 53 | 62 | 18 |
| Benign | 18 | 16 | 12 | 23 | 65 | 6 | 23 | 12 |
| Malignant | 12 | 15 | 40 | 47 | 35 | 47 | 39 | 6 |
| Operative time (min) | 214 87 | 115 (45-210) | 182 38 | - | 140 | 187 (80-334) | 146 (40-305) | 202 48 |
| Blood loss (ml) | 300 (0-1500) | 210 (0-700) | 350 210 | - | - | 700 (100-5000) | 458 (10-2000) | 236 155 |
| Partial hepatectomy | 21 | 17 | 32 | 35 | 69 | 38 | 28 | - |
| Major hepatectomy | 1 | 10 | - | 30 | 31 | - | 2 | - |
| Lef tlateral hepatectomy | 8 | 4 | 20 | 5 | - | 15 | 28 | 18 |
| Postoperative stay (day) | 9.6(3-40) | 11(4-40) | 14.9 7.1 | - | 3 | 3.5(1-14) | 7(1-15) | 8 3 |
| Conversion rate | 2(6.7%) | 3(9.7%) | 1(1.9%) | 3(4.3%) | 0 | 3(6%) | 2(3.2%) | 2(11.1%) |
| Complication rate | 1(6.3%) | 5(16.1%) | 3(5.8%) | 2(4.2%) | 23(23%) | 8(15.1%) | 2(3.2%) | 0 |
| death | 0 | 0 | 0 | 1 | 1 | 0 | 0 | 0 |

There are comparative studies between open and laparoscopic hepatectomy. Lesurtel et al. [7] reported a comparison between laparoscopic left lateral hepatectomy and open left lateral hepatectomy in 18 patients. Laparoscopic hepatectomy took longer than the opened left lateral hepatectomy (202 versus 145 minutes, $p < 0.001$), but the loss of blood was lower (236 versus 429 ml, $p < 0.05$) with statistical significance. Thus, laparoscopic left lateral hepatectomy was considered a safe operation. Morino et al. [24] reported rates of mortality and morbidity in both groups. However, the laparoscopic approach reduced blood loss and postoperative hospital stay, suggesting that laparoscopic surgery was a good alternative to open surgery for liver resections (in selected patients). Moreover, Kaneko et al. [6] showed that the operative time and blood loss in laparoscopic surgery might decrease after 5 years of experience with statistical significance.

In conclusion, laparoscopic left lateral hepatectomy for benign tumor case may be appropriate.

References

1. Hashizume M, Shimada M, Sugimachi K. Laparoscopic hepatectomy: new approach for hepatocellular carcinoma. *J Hepatobiliary Pancreat Surg.* 2000;7:270-5.
2. Buell JF, Koffron AJ, Thomas MJ, Rudich S, Abecassis M, Woodle ES. Laparoscopic liver resection. *J Am Coll Surg.* 2005;200:472-80.
3. Consten EC, Gagner M. Perioperative outcome of laparoscopic left lateral liver resection is improved by using staple line reinforcement technique: a case report. *J Gastrointest Surg.* 2005;9:360-4.
4. Buell JF, Thomas MJ, Doty TC, Gersin KS, Merchen TD, Gupta M, et al. An initial experience and evolution of laparoscopic hepatic resectional surgery. *Surgery.* 2004;136:804-11.
5. Smyrniotis V, Farantos C, Kostopanagiotou G, Arkadopoulos N. Vascular control during hepatectomy: review of methods and results. *World J Surg.* 2005;29:1384-96.
6. Kaneko H, Takagi S, Otsuka Y, Tsuchiya M, Tamura A, Katagiri T, et al. Laparoscopic liver resection of hepatocellular carcinoma. *Am J Surg.* 2005;189:190-4.
7. Lesurtel M, Cherqui D, Laurent A, Tayar C, Fagniez PL. Laparoscopic versus open left lateral hepatic lobectomy: a case-control study. *J Am Coll Surg.* 2003;196:236-42.
8. Teramoto K, Kawamura T, Takamatsu S, Noguchi N, Nakamura N, Arai S. Laparoscopic and thoracoscopic partial hepatectomy for hepatocellular carcinoma. *World J Surg.* 2003;27:1131-6.
9. Teramoto K, Kawamura T, Takamatsu S, Nakamura N, Kudo A, Noguchi N, et al. Laparoscopic and thoracoscopic approaches for the treatment of hepatocellular carcinoma. *Am J Surg.* 2005;189:474-8.
10. Kaneko H. Laparoscopic hepatectomy: indications and outcomes. *J Hepatobiliary Pancreat Surg.* 2005;12:438-43.
11. Cherqui D, Husson E, Hammoud R, Malassagne B, Stephan F, Bensaid S, et al. Laparoscopic liver resections: a feasibility study in 30 patients. *Ann Surg.* 2000;232:753-62.
12. Soyer P, Mosnier H, Choti MA, Rymer R. Intraoperative and laparoscopic sonography of the liver. *Eur Radiol.* 1997;7:1296-302.
13. Toyama Y, Miyake R, Son K, Yoshida S, Usuba T, Nojiri T, et al. Three-Port laparoscopic partial hepatectomy using an ultrasonically activated device (USAD). *J Hepatobiliary Pancreat Surg.* 2006;13:317-22.
14. Huang MT, Lee WJ, Wang W, Wei PL, Chen RJ. Hand-assisted laparoscopic hepatectomy for solid tumor in the posterior portion of the right lobe: initial experience. *Ann Surg.* 2003;238:674-9.
15. Kaneko H, Otsuka Y, Takagi S, Tsuchiya M, Tamura A, Shiba T. Hepatic resection using stapling devices. *Am J Surg.* 2004;187:280-4.
16. Linden BC, Humar A, Sielaff TD. Laparoscopic stapled left lateral segment liver resection-technique and results. *J Gastrointest Surg.* 2003;7:777-82.
17. Constant DL, Slakey DP, Campeau RJ, Dunne JB. Laparoscopic nonanatomic hepatic resection employing the LigaSure device. *JLS.* 2005;9:35-8.
18. Kurosaki I, Yamamoto S, Kitami C, Yokoyama N, Nakatsuka H, Kobayashi T, et al. Video-assisted living donor hemihepatectomy through a 12-cm incision for adult-to-adult liver transplantation. *Surgery.* 2006;139:695-703.
19. Schmandra TC, Mierdl S, Bauer H, Gutt C, Hanisch E. Transoesophageal echocardiography shows high risk of gas embolism during laparoscopic hepatic resection under carbon dioxide pneumoperitoneum. *Br J Surg.* 2002;89:870-6.
20. Sugita M, Nagahori K, Kudo T, Yamanaka K, Obi Y, Shizawa R, et al. Diaphragmatic hernia resulting from injury during microwave-assisted laparoscopic hepatectomy. *Surg Endosc.* 2003;17:1849-50.

21. Dulucq JL, Wintringer P, Stabilini C, Berticelli J, Mahajna A. Laparoscopic liver resections: a single center experience. *Surg Endosc.* 2005;19:886-91.
22. Mala T, Edwin B, Rosseland AR, Gladhaug I, Fosse E, Mathisen O. Laparoscopic liver resection: experience of 53 procedures at a single center. *J Hepatobiliary Pancreat Surg.* 2005;12:298-303.
23. Cai XJ, Yu H, Liang X, Wang YF, Zheng XY, Huang DY, et al. Laparoscopic hepatectomy by curettage and aspiration. Experiences of 62 cases. *Surg Endosc.* 2006;20:1531-5.
24. Morino M, Morra I, Rosso E, Miglietta C, Garrone C. Laparoscopic vs open hepatic resection: a comparative study. *Surg Endosc.* 2003;17:1914-8.



ศูนย์วิทยุทรัพยากร
จุฬาลงกรณ์มหาวิทยาลัย