

## Treatment of asymptomatic primary angle closure

Visanee Tantisevi\*

**Tantisevi V. Treatment of asymptomatic primary angle closure. Chula Med J 2004 Oct; 48(10): 687 - 93**

*Angle closure glaucoma has many forms of manifestation. In severe cases, the patients present with acute attack of intense pain in the eye, blurred vision and sometimes, systemic symptoms. This often leads the affected persons to seek immediate medical services. On the other hand, chronic progressive form of the disease advances quietly and usually prevents the patients from seeking early treatment. In our report, a middle-aged woman came in with the problems that were not related to her angle structure in which later identified as primary angle closure. Her angle structure needed further investigations to show what would be the responsible mechanisms as well as interventions to reduce the risks of glaucoma. Primary angle closure can be asymptomatic that rarely leads the patient to recognize the problem. Hereby, this is an example of clinical forms that should prompt the physician to look for the underlying mechanisms and the attempts to prevent possible developing glaucoma.*

**Keywords :** *Primary angle closure, Asymptomatic, Occludable angle, Treatment.*

Reprint request : Tantisevi V. Department of Ophthalmology, King Chulalongkorn Memorial Hospital, Bangkok 10330, Thailand.

Received for publication: July 13, 2004.

**วิศน์ ตันติเสวี. การดูแลรักษาผู้ป่วยมุมตาปิดแบบปฐมภูมิที่ไม่แสดงอาการ. จุฬาลงกรณ์เวชสาร 2547 ต.ค; 48(10): 687 - 93**

กลุ่มโรคต้อหินชนิดมุมตาปิดสามารถแสดงอาการได้หลายรูปแบบ บางรายที่เป็นรุนแรงผู้ป่วยมาด้วยอาการของต้อหินมุมปิดเฉียบพลัน มีอาการปวดตามาก ตามัว และอาจมีอาการทางระบบอื่นร่วมด้วย อาการเหล่านี้มักจะทำให้ผู้ป่วยเข้ารับการรักษาโดยทันที ในขณะที่บางครั้งต้อหินชนิดมุมตาปิดเรื้อรังจะดำเนินโรคแบบค่อยเป็นค่อยไปอย่างเงียบ ๆ ทำให้ผู้ป่วยไม่ได้รับการดูแลรักษาตั้งแต่ในระยะเริ่มต้น ในรายงานผู้ป่วยฉบับนี้ เป็นรายงานผู้ป่วยหญิงวัยกลางคนที่มาพบแพทย์ด้วยอาการทางตาที่ไม่เกี่ยวกับลักษณะโครงสร้างมุมตา ซึ่งตรวจพบในเวลาต่อมาพบว่าเป็น มุมตาปิดแบบปฐมภูมิ จึงต้องตรวจสอบค้นต่อไปเพื่อแสดงให้เห็นว่าเกิดจากกลไกใด และในผู้ป่วยรายนี้ต้องการการรักษาเพื่อลดโอกาสการเกิดต้อหิน จะเห็นได้ว่ามุมตาปิดแบบปฐมภูมิอาจไม่แสดงอาการ ซึ่งทำให้ผู้ป่วยไม่ทราบถึงปัญหา ลักษณะทางคลินิกต่อไปนี้เป็นอีกหนึ่งตัวอย่างที่ผู้ให้การดูแลควรมองหากกลไกสาเหตุและหาทางป้องกันภาวะต้อหินอันอาจเกิดตามมาได้ในอนาคต

**คำสำคัญ :** มุมตาปิดแบบปฐมภูมิ, ไม่แสดงอาการ, มุมตาที่ถูกบดบังได้, การดูแลรักษา

Angle closure glaucoma is a major problem in Asia. Many epidemiology studies have suggested that people in Asia, particularly Chinese descendents, have higher incidence of angle closure glaucoma than the white or the black. <sup>(1-6)</sup> Recently in Thailand, a population-based survey in the suburban area of Bangkok showed interesting number of subjects with occludable angle and angle closure glaucoma. <sup>(7)</sup> The finding implies that there is considerable number of people who we should be aware of having the disorder beyond routine detection in clinical practices.

Apart from relative papillary block, several mechanisms are involved with the disease, for examples, plateau iris configuration and forward lens movement. In Asians, crowding of anterior segment is also implicated. <sup>(8-10)</sup> Usually, there are several mechanisms contributing to angle closure structure. Practically, we might not be able to achieve a successful treatment merely through eradicating only one mechanism responsible for the disease.

### Case study

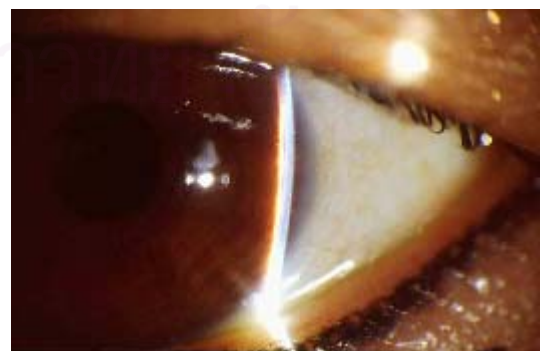
A 44-year-old Thai woman came to see a doctor with a problem of occasional blurred vision in her left eye to which usually improved after blinking. She never experienced other eye symptoms. She did have an underlying medical problem of asthma for 30 years for which Theo-dur® and Dimetapp® were prescribed. The symptoms improved, and all tablets were subsequently withdrawn. Not long before this visit, allergic rhinitis was diagnosed and Rhinocort aqua was then commenced. This had been treated for 2 months. Also, she developed menopause for which was treated with Premarin 0.3 mg/day.

Physical examination revealed a healthy-looking middle-aged woman. Her visual acuity was 20/40 and 20/20 after pinhole in her right eye, whereas in her left eye, 20/20-2. Her refraction disclosed +1.50-0.75 x 64° in the right and +1.50-1.00 x 100° in the left. External eye examination was unremarkable. Corneas were clear with no punctuate keratopathy in both eyes.

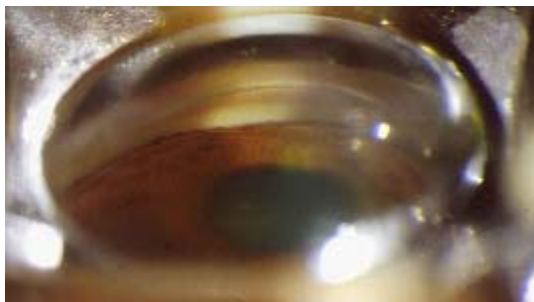
Apparently, her anterior chambers were bilaterally markedly shallow, both central and peripheral. (Figure 1)

Measurement of intra-ocular pressure (IOP) revealed 21 and 22 mmHg in the right and the left eye, respectively. Gonioscopic examination in darkened room with minimal light intensity slit beam showed anterior chamber (A/C) angle grade 0 (Modified Shaffer's grading system) in all quadrants of both eyes. (Figure 2) After indentation was performed, A/C angle turned into grade 3 without peripheral anterior synechiae (PAS). (Figure 3)

Her vertical cup/disc (C/D) ration was 0.4 in the right, 0.3 in the left. (Figure 4,5) Vitreous and retina were unremarkable. Visual field 24-2 SITA fast of both eyes showed unremarkable results.



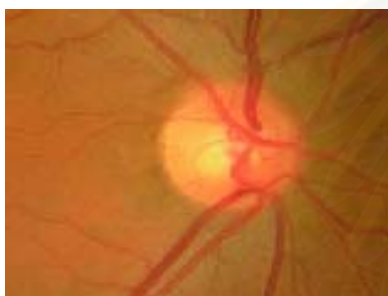**Figure 1.** Slit lamp examination revealed shallow peripheral anterior chamber depth



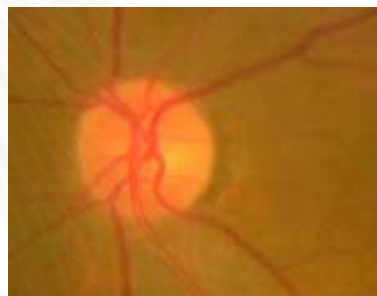
**Figure 2.** On gonioscopy, no apparent angle structure was identified. According to modified Shaffer's Grading System, this could be graded 0.



**Figure 3.** After indentation, angle was wider open and pigmented trabecular meshwork could be disclosed without peripheral anterior synechiae. (PAS)



**Figure 4.** Right optic disc showed vertical 0.4 C/D. However, no localized rim loss was identified.



**Figure 5.** Left optic disc showed vertical 0.3 C/D. Neural rim showed no notching.

She was then diagnosed of having dry eye symptom and occludable angle. The latter was followed by a description issued by the committee of epidemiology of angle closure glaucoma. Management for her primary problem included a prescription of artificial tear, and laser peripheral iridotomy (LPI) for the unveiled problem.

The patient agreed to have LPI performed.

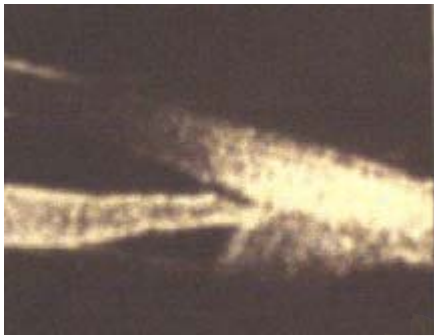
Later, after LPI was successfully done in both eyes, the eyes were re-checked.

IOPs were recorded as 21 mmHg in the right and 26 mmHg in the left.

Gonioscopy then revealed A/C angle was still grade 2, with indentation the angle could be wider

open and iris curvature appeared rather flat. No PAS was identified. As the angle appeared occludable early than usual in this woman who had no apparent family history of angle closure glaucoma, our attempt was to find out the most likely underlying mechanism of the anatomical predisposition. Although LPI was performed to ensure relative papillary blockage, the most probable main cause of hidden trabecular meshwork in the eye, would have been eliminated, many more mechanisms would be responsible for the disease, some of them are common, namely:

1. Plateau iris configuration or syndrome
2. Forward lens movement



**Figure 6.** Plateau iris configuration was shown by UBM after laser iridotomy had been performed.

Additionally, the followings should also be brought into consideration:

3. Anophthalmos
4. Post-iridial mass

Further investigations entailed for investigation. Ultrasound Biomicroscopy (UBM) was done and the results are shown in Figure 6.

A and B-scan ultrasonography also revealed 21.86 and 21.83 mm of axial length in the right and left eye, respectively. Scleral thickness was comparable to norms.

## Discussion

According to the definition of angle closure described by Foster PJ,<sup>(11)</sup> our patient is one of those who are with primary angle closure.

From all the investigation results, the most striking mechanism that should be responsible for the occludable angle in this woman was “plateau iris configuration”.<sup>(12)</sup> However, appositional angle identified by gonioscopy, relative pupillary block was the most probable cause. Laser iridotomy was subsequently suggested. As our patient also had a

very shallow central A/C depth identified by UBM, forward lens movement was another possibility.<sup>(12-13)</sup> The measured axial length, refraction and scleral thickness did not meet the criterion of anophthalmic eye. And there was no abnormal mass behind the iris identified by UBM. The latter two possible mechanisms were therefore ruled out.

Plateau iris configuration is a disorder characterized by anteriorly positioned ciliary body, which pushes the peripheral iris further forward toward the trabecular meshwork resulting in narrowing of anterior chamber angle.<sup>(12)</sup> This distinguished anatomical character usually leads to later development of angle closure glaucoma. Management of this disorder is directed towards widening of the angle in order to prevent forthcoming of anterior synechiae. Apart from the first attempt of laser iridotomy,<sup>(14-16)</sup> laser iridoplasty to shrink and thin down the peripheral iris tissue is also necessary.<sup>(17-19)</sup>

Many observations reported the role of lens in association with angle closure. Not only the thickness of everyday growing lens compromising A/C depth as well as A/C angle width in crowded anterior segment, but also the anatomical position has been implicated. For over half of the last decade, several ophthalmologists have advocated lens removal even in clear lenses. Cataract removal and goniosynechiaelysis is another suggestion in angle closure where PAS is present less than 6 months.<sup>(20)</sup>

In our case, though plateau iris configuration was identified through UBM after laser iridotomy was done, re-examination revealed the angle was not widely open according to the plane of the iris draping along the bulging lens surface. Therefore, the next plan of management was laser iridoplasty in order to

widen the angle. As the patient had no problem with her vision and she was seeking medical advice with symptoms not related to her angle structure, despite rise-up eye pressure, lens removal was considered too invasive an option. Nevertheless, our plan of care was discussed in depth with her. After a detailed discussion, she opted for conservative treatment with anti-glaucoma medication rather than taking a surgical operation. Regular follow-up of A/C angle figure and IOP was recommended.

### Conclusion

This is a case of asymptomatic primary angle closure. If left untreated, glaucoma would soon ensue. Underlying mechanisms should be actively corrected to prevent possible acute attack or chronic development. In some situations, sequential or combined managements are needed. Also, regular follow-ups are necessary.

**Conflict of interest:** declared none

### References

- Congdon N, Wang F, Tielsch JM. Issues in the epidemiology and population-based screening of primary angle-closure glaucoma. *Surv Ophthalmol* 1992 May-Jun;36(6):411-23
- Salmon JF, Mermoud A, Ivey A, Swanevelde SA, Hoffman M. The prevalence of primary angle-closure glaucoma and open angle glaucoma in Mamre, western Cape, South Africa. *Arch Ophthalmol* 1993 Sep; 111(9): 1263 - 9
- Quigley HA. Number of people with glaucoma worldwide. *Br J Ophthalmol* 1996 May; 80(5): 389 - 93
- Foster PJ, Baasanhu J, Alsbirk PH, Munkhbayar D, Uranchimeg J, Johnson GJ. Glaucoma in Mongolia. A population-based survey in Hovsgol province, northern Mongolia. *Arch Ophthalmol* 1996 Oct;114(10): 1235 - 41
- Seah SK, Foster PJ, Chew PT, Jap A, Oen F, Fam HB, Lim AS. Incidence of acute primary angle-closure glaucoma in Singapore. An island-wide based survey. *Arch Ophthalmol* 1997 Nov;115(11):1436 - 40
- Foster PJ, Johnson GJ. Glaucoma in China: how big is the problem?. *Br J Ophthalmol* 2001 Nov; 85(11): 1277 - 82
- Bourne RR, Sukdom P, Foster PJ, Tantisevi V, Jitapunkul S, Lee PS, Johnson GJ, Rojanapongpun P. Prevalence of glaucoma in Thailand: a population based survey in Rom Klao District, Bangkok. *Br J Ophthalmol* 2003 Sep; 87(9):1069 - 74
- Ningli W, Wenbin Z, Tiancai Y, Qiang Y, Mingying L, Meihua L. Studies of primary angle-closure glaucoma in China. *Yan Ke Xue Bao* 1997 Sep;13(3): 120 - 4
- Marchini G, Pagliaruso A, Toscano A, Tosi R, Buenelli C, Bonomi L. Ultrasound biomicroscopic and conventional ultrasonographic study of ocular dimensions in primary angle-closure glaucoma. *Ophthalmology* 1998 Nov; 105(11): 2091 - 8
- Wang N, Ouyang J, Zhou W, Ye T, Zeng M, Chen J. Multiple patterns of angle closure mechanisms in primary angle-closure glaucoma in Chinese. *Zhonghua Yan Ke Za Zhi* 2000 Jan;36(1): 46 - 51, 5, 6
- Foster PJ, Buhrmann R, Quigley HA, Johnson GJ.

- The definition and classification of glaucoma in prevalence surveys. *Br J Ophthalmol* 2002 Feb; 86(2): 238 - 42
12. Pavlin CJ, Ritch R, Foster FS. Ultrasound biomicroscopy in plateau iris syndrome. *Am J Ophthalmol* 1992 Apr 15;113(4): 390 - 5
13. Garudadri CS, Chelerkar V, Nutheti R. An ultrasound biomicroscopic study of the anterior segment in Indian eyes with primary angle-closure glaucoma. *J Glaucoma* 2002 Dec;11(6): 502 - 7
14. Tomey KF, Traverso CE, Shamma IV. Neodymium-YAG laser iridotomy in the treatment and prevention of angle-closure glaucoma. A review of 373 cases. *Arch Ophthalmol* 1987 Apr; 105(4): 476 - 81
15. Thomas R, Arun T, Muliylil J, George R. Outcome of laser peripheral iridotomy in chronic primary angle closure glaucoma. *Ophthalmic Surg Lasers* 1999 Jul-Aug; 30(7): 547 - 53
16. Nolan WP, Foster PJ, Devereux JG, Uranchimeg D, Johnson GJ, Baasanhu J. YAG laser iridotomy treatment for primary angle closure in east Asian eyes. *Br J Ophthalmol* 2000 Nov; 84(11): 1255 - 9
17. Chew PT, Yeo LM. Argon laser iridoplasty in chronic angle closure glaucoma. *Int Ophthalmol* 1995;19(2):67 - 70
18. Ritch R, Liebmann JM. Argon laser peripheral iridoplasty. *Ophthalmic Surg Lasers* 1996 Apr; 27(4): 289 - 300
19. Ritch R, Tham CC, Lam DS. Long-term success of argon laser iridoplasty for the management of plateau iris syndrome. *Ophthalmology* 2004 Jan; 111(1): 104 - 8
20. Teekhasaene C, Ritch R. Combined phacoemulsification and goniosynechialysis for uncontrolled chronic angle closure glaucoma after acute angle-closure glaucoma. *Ophthalmology* 1999 Apr;106(4): 669 - 75