

Laparoscopic adrenalectomy : First 50 cases in King Chulalongkorn Memorial Hospital

Apirak Santi-ngamkun* Supoj Ratchanon*

Krishna Aksornnit* Sarat Sunthornyothin**

Santi-ngamkun A, Ratchanon S, Aksornnit K, Sunthornyothin S. Laparoscopic adrenalectomy : First 50 cases in King Chulalongkorn Memorial Hospital. Chula Med J 2005 Jun; 49(6): 325 - 32

- Background** : *Since the first laparoscopic adrenalectomy was reported in 1992, it has been generally accepted as the standard treatment for benign adrenal lesions.*
- Objective** : *To evaluate the effectiveness and safety of this technique from the experiences of the first 50 cases.*
- Design** : *Descriptive study*
- Setting** : *Division of Urology, Department of Surgery, Faculty of Medicine, Chulalongkorn University.*
- Materials and Methods** : *Records of every patient who received laparoscopic adrenalectomy at King Chulalongkorn Memorial Hospital from 2000 until 2004 were reviewed. We examined the patients' characteristics, intraoperative time and blood loss including post operation courses and complications.*

* Department of Surgery, Faculty of Medicine, Chulalongkorn University

** Department of Medicine, Faculty of Medicine, Chulalongkorn University

Results : A total of 50 patients who had unilateral laparoscopic adrenalectomy. The mean age was 42.9 years. Indications were primary aldosteronism ($n = 34$), pheochromocytoma ($n = 7$), Cushing's syndrome ($n = 6$), paraganglioma ($n = 1$) and nonfunctioning tumor ($n = 2$). The mean operative time was 128.5 min and estimated blood loss was 124.4 ml. Conversion to open adrenalectomy was performed in 2 cases from bleeding and adhesion respectively. Two major complications were colonic injury and ischemic stroke. No death occurred in our series.

Conclusions : Laparoscopic adrenalectomy is a safe and effective minimally invasive surgical operation for the treatment of various adrenal diseases. It produces a lot of benefits for the patients with less pain and faster recovery. Therefore, we recommend it to every patient with benign adrenal lesions of small and median size.

Keywords : Laparoscopic adrenalectomy.

Reprint request : Santi-ngamkun A. Department of Surgery, Faculty of Medicine,
Chulalongkorn University, Bangkok 10330, Thailand.

Received for publication. January 15, 2005.

อภิรักษ์ สันติงามกุล, สุพจน์ รัชชานนท์, กฤษณะ อักษรนิตย์, สารัช สุนทรโยธิน. รายงานผู้ป่วย 50 รายแรก ในโรงพยาบาลจุฬาลงกรณ์ที่ได้รับการผ่าตัดต่อมหมวกไต โดยวิธีส่องกล้องผ่านหน้าท้อง. จุฬาลงกรณ์เวชสาร 2548 มิ.ย; 49(6): 325 - 32

- เหตุผลของการทำวิจัย** : การผ่าตัดต่อมหมวกไต โดยวิธีส่องกล้องผ่านหน้าท้องได้เริ่มเมื่อปี 2537 และได้รับความนิยมเพิ่มขึ้นจนเป็นมาตรฐานของการผ่าตัดต่อมหมวกไตในสถาบันชั้นนำของโลกในปัจจุบัน
- วัตถุประสงค์** : รายงานประสิทธิภาพ และความปลอดภัยของวิธีการผ่าตัดนี้ ในผู้ป่วย 50 รายแรก
- รูปแบบการวิจัย** : การศึกษาเชิงพรรณนา
- สถานที่ทำการศึกษา** : หน่วยศัลยศาสตร์ระบบทางเดินปัสสาวะ ภาควิชาศัลยศาสตร์ คณะแพทยศาสตร์ จุฬาลงกรณ์มหาวิทยาลัย
- ตัวอย่างและวิธีการศึกษา** : สืบค้นจากประวัติผู้ป่วยที่ได้รับการผ่าตัดต่อมหมวกไต โดยวิธีส่องกล้องผ่านหน้าท้อง ตั้งแต่ปี 2543 จนถึงปี 2548 โดยพิจารณาชนิดของโรคต่อมหมวกไต รายงานในการผ่าตัด และผลของการผ่าตัด รวมถึงภาวะแทรกซ้อนที่เกิดขึ้น
- ผลการศึกษา** : ผู้ป่วย 50 ราย มีอายุเฉลี่ย 42.9 ปี เป็นผู้ป่วย primary aldosteronism 34 ราย pheochromocytoma 7 ราย Cushing's syndrome 6 ราย paragangliona 1 ราย และเนื้องอกที่ไม่สร้างฮอว์โมน 2 ราย เวลาเฉลี่ยที่ในการผ่าตัด 128.5 นาที เลือดออกขณะผ่าตัดโดยเฉลี่ย 124.4 มิลลิลิตร และผู้ป่วยจำเป็นต้องรับการเปลี่ยนเป็นผ่าตัดชนิดเปิดหน้าท้อง 2 ราย เนื่องจากเลือดออก 1 ราย และพังผืดติดเส้นเลือดดำของไต 1 ราย ภาวะแทรกซ้อนที่สำคัญ คือบาดเจ็บต่อลำไส้ใหญ่ 1 ราย และอัมพฤกษ์ของแขนขวา 1 ราย ไม่มีผู้ป่วยเสียชีวิตจากการผ่าตัด
- สรุป** : การผ่าตัดต่อมหมวกไต โดยวิธีส่องกล้องผ่านหน้าท้อง เป็นวิธีที่มีประสิทธิภาพ และปลอดภัยในการรักษาโรคของต่อมหมวกไต ผลข้างเคียงต่ำ และสามารถลดการเจ็บปวดของแผล และกลับสู่ภาวะปกติได้เร็ว จึงเป็นวิธีที่น่าจะแนะนำในผู้ป่วยทุกรายที่เป็นเนื้องอกของต่อมหมวกไตชนิดที่ไม่ใช่เนื้อร้ายและขนาดไม่ใหญ่มาก
- คำสำคัญ** : การผ่าตัดต่อมหมวกไตโดยการส่องกล้อง

Since it was first described in 1992 by Gagner M⁽¹⁾, laparoscopic adrenalectomy has become widely used as a treatment of all adrenal pathology. Several studies have reported that the morbidity of the procedure is lower than of open adrenalectomy⁽²⁻⁴⁾, including terms of recovery and cosmetic reasons. Despite a lack of high level of evidence, it seems that laparoscopic adrenalectomy has become the procedure of choice for the treatment of small and medium-size benign lesions of adrenal gland⁽⁵⁾. The objectives of the present study were to review the outcomes of laparoscopic adrenalectomy since year 2000 and to evaluate its effectiveness in the treatment of various adrenal pathologies

Patients and Methods

A retrospective analysis of medical records of 50 patients who underwent laparoscopic adrenalectomy was conducted by two surgeons. All 50 cases (32 women 18 men) who received laparoscopic adrenalectomy between April, 2000 and

December, 2004 at King Chulalongkorn Memorial Hospital were reviewed. All patients have a complete endocrine evaluation before surgery by endocrinologists. The patients' characteristics are shown in table 1. The medical records were reviewed to assess patient demographics, operative parameters and postoperative events.

Surgical technique : The patient was placed in lateral decubitus position. Three to four trocars were used on the left side and four on the right side. The first trocar was a 12 mm Hanson type, used as the opening technique at the mid-clavicular line, 3 inches cephalad to naval level (Fig 1). Pneumoperitoneum was created with carbon dioxide and maintained at 15 mmHg. End-tidal CO₂ was monitored by anesthesiologist.

On the right side, the peritoneum was incised parallel to the liver and upper pole of kidney then turned along the vena cava. The fourth trocar was usually placed at epigastrium to retract the right hepatic lobe upward and locked to the abdominal side wall. On the left side the colonic flexure and spleen were displaced cranially. On each side, the adrenal vein was dissected and controlled with titanium clips, then the adrenal gland was mobilized, small veins were clipped or cauterized. The adrenal gland was placed in a bag and removed via the scope port.

Table 1. Patient characteristics and the surgical variables.

| Patient characteristics | |
|-------------------------|-------------|
| No | 50 |
| mean (SD) age.years | 42.9 (11.9) |
| Sex M/F | 18/32 |
| Side R/L | 22/28 |
| Disease: | |
| Primary aldosteronism | 34 |
| Cushing's | 6 |
| Pheochromocytoma | 7 |
| paraganglioma | 1 |
| Nonfunctioning | 2 |

Results

Forty-eight of the 50 cases received a successfully operation. Conversion to open surgery was necessary in 2 cases (4 %) due to bleeding in one case (15 cm pheochromocytoma attached to renal vein), another case was from severe intraperitoneal adhesion. No death occurred in the series. The mean

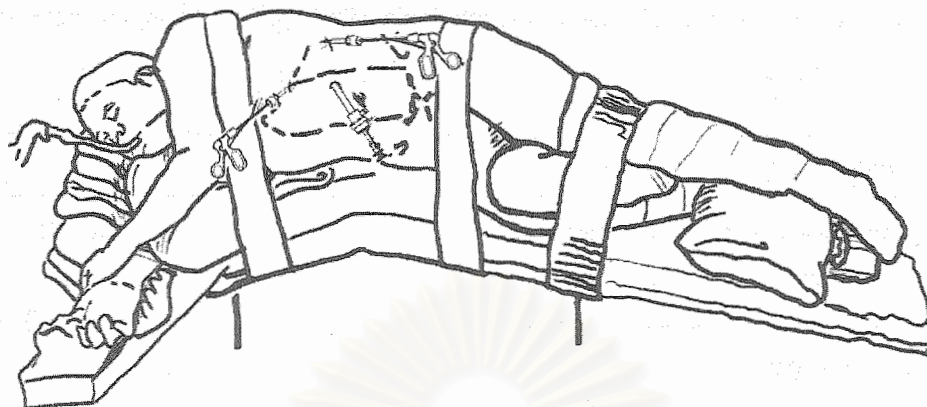


Figure 1. Position of the patients and instruments sites for the left laparoscopic adrenalectomy.

operative time was 128.5 min (70- 210min); right side 120.7 min and left side 134.6 min.

Estimated blood loss was 124.4 ml, right 115.5 ml, left 131.5 ml; no patient required blood transfusion (Table 2).

Postoperative complications were observed in 12% of the patients. The most common complication was subcutaneous emphysema, but all of them resolved in 3 days. In 1 case was a colonic injury

which required suturing for repair; the patient could be discharged from the hospital after 10 days of observation. There was a case of pheochromocytoma which developed into ischemic stroke from intraoperative hypotension and had right arm paralysis, CT-scan showed lacuna infarction. However, the patient recovered fully after 2 weeks of rehabilitation. One case of subcutaneous hematoma required observation for one week.

Table 2. Intra-operative characteristics and post-operative complication (* excluding the converse-to-open cases).

| Operative characteristics | |
|---|----------------|
| Mean mins. Operative time (range)* | 128.5 (70-220) |
| Mean ml. estimated blood loss (range)* | 124.4 (20-500) |
| Conversion rate. N(%): | 2 (4 %) |
| Bleeding | 1 (2 %) |
| Adhesion | 1 (2 %) |
| No. complication* : | 6 (12 %) |
| Colonic injury | 1 (2 %) |
| Ischemic stroke (Transient right arm paralysis) | 1 (2 %) |
| Subcutaneous emphysema | 3 (6 %) |
| Hematoma at port site | 1 (2 %) |

Table 3. Post-operative characteristics and pathological finding (* excluding the converse-to-open cases).

| Postoperative characteristics | |
|---|---------------|
| Mean mg. morphine sulfate equivalents(range)* | 4.9 (0-21) |
| Mean days to full oral intake (range)* | 2.3 (1.14) |
| Mean days of postop. Hospital stay (days)(range)* | 4.25 (2-17) |
| Pathological findings: | |
| Mean size of tumor specimen (cm) | 2.8 (0.25-15) |
| No. adenoma | 48 |
| No. hyperplasia | 2 |

Table 1 shows the patients' characteristics. Most of the cases are primary aldosteronism (34 cases), others are 6 cortisol-producing adenoma, 7 pheochromocytoma and 2 incidentaloma. One case of paraganglioma was found at left renal hilar with increased catecholamine secretion.

Postoperative characteristics are shown in table 3. All types of opiate analgesia were converted to morphine equivalent ; the mean given dosage was 4.9 mg (0-21 mg). Seventeen patients did not require opiate analgesia, just only acetaminophen or NASID. The mean post-operative hospital stay was 4.25 days (range 2-17 days).

Discussion

Our accumulated data since 1992 indicate that in terms of feasibility, safety and recovery, laparoscopic adrenalectomy is a reproducible procedure. Even though there are insufficient well designed studies, Laparoscopic adrenalectomy has become the procedure of choice for a large number of surgeons worldwide. As the results of the comparative level 3b studies were almost consistent,

the Oxford Center for Evidence Based Medicine considered laparoscopic adrenalectomy as intermediate (grade B)⁽⁵⁾. Nevertheless, the overall results argue that laparoscopic adrenalectomy has a positive impact on the outcome of adrenal surgery beyond the conventional opened adrenalectomy of reduced pain and faster recovery, besides a better cosmetic appearance.

Laparoscopic adrenalectomy is performed in a variety of adrenal diseases. Primary aldosteronism has been the most common indication in most series.⁽⁵⁾ According to the first 50 cases of our experience, we found primary aldosteronism 34 of 50 cases; aldosterone-producing adenomas were predominant except only two cases of adrenal hyperplasia. Laparoscopic surgery is therefore procedure of challenge, it decreases manipulation of the tumor during dissection and improves ability to visualize the contiguous anatomy. However, it should be performed with care because of vulnerable hemodynamic changes. In the present study, conversion to an open adrenalectomy was performed in 2 cases, both were pheochromocytoma in nature,

due to intraoperative bleeding and adhesion to the renal vein. One case of laparoscopic adrenalectomy for pheochromocytoma suffered transient right arm paralysis from lacuna infarction, which was possibly related to intraoperative hypotension after the adrenal vein was ligated.

Transperitoneal laparoscopic approach is the procedure of choice for all our cases. A clearer exposure, a larger working space and a lack of balloon inflation could make the operation perform smoothly. No study has shown that retroperitoneal approach can surpass intraperitoneal approach in all expectations.

A. Assalia (2004) reported a meta-analysis data of 2550 laparoscopic adrenalectomy cases, from January 1990 to October 2003, it was shown that the mean operating time was 156 min with 3.6 % conversion rate and 3.3 days of hospitalization⁽⁵⁾. Compare to the present study, our operating time was 128.5 min and conversion rate was 4 %. The hospital stay in our data was much longer, possibly from lower hospital charge and longer preoperative process. However, the complication rate and the estimated blood loss volume were comparable to that of most recent series.⁽⁶⁻¹⁰⁾ Most postoperative complication were minor and able to recover after a short period of observation. Two major complications were colonic injury and ischemic stroke. In the former cases, the ascending colon was accidentally injured with electrical cauterization and required suturing repair, in a case of laparoscopic right adrenalectomy for Cushing's syndrome, no postoperative leakage was found. In the latter, ischemic stroke was caused by transient intraoperative hypotension and the patient recovered after 2 weeks of rehabilitation.

As widely demonstrated, laparoscopic

procedures provide good postoperative comfort and require less analgesic medication. Early oral intake and ambulation are possible in most patients and complete recovery needs short time. From our ongoing experience, 31 of 50 cases needed parenteral opiate analgesia. Most of them required only small dosage of analgesia. It was shown that the severity of pain was minimal. Diet was started on the first day and full oral intake in two days, except in the case that the patient had colonic injury.

Conclusion

Laparoscopic adrenalectomy is safe and effective a minimally invasive therapeutic option for patients with various adrenal diseases. It has the advantage of causing less pain and fast recovery. According to our experience, we recommend it for all patients with benign lesions of small and medium - size. However, special care should be considered for large pheochromocytoma and malignancy.

References

1. Gagner M, Lacey A, Bolte E. Laparoscopic adrenalectomy in Cushing's syndrome and pheochromocytoma. *N Engl J Med* 1992 Oct; 327(14):1003
2. Prinz RA. A comparison of laparoscopic and open adrenalectomies. *Arch Surg* 1995 May;130(5): 489 - 94
3. Brunt LM, Doherty GM, Norton JA, Soper NJ, Quasebarth MA, Moley JF. Laparoscopic adrenalectomy compared to open adrenalectomy for benign adrenal neoplasms. *J Am Coll Surg* 1996 Jul;183(1):1 - 10
4. Thompson GB, Grant CS, van Heerden JA,

- Schinkert RT, Young WF Jr, Farley DR, Ilstrup DM. Laparoscopic versus open posterior adrenalectomy: a case-control study of 100 patients. *Surgery* 1997 Dec;122(6):1132 - 6
5. Assalia A, Gagner M. Laparoscopic adrenalectomy. *Br J Surg* 2004 Oct; 91(10): 1259 - 74
6. Kebebew E, Siperstein AE, Duh QY. Laparoscopic adrenalectomy: the optimal surgical approach. *F Leparoendosc Adv Surg Tech A* 2001 Dec; 11(6): 409 - 13
7. Suzuki K, Kageyama S, Hirano Y, Ushiyama T, Rajamahanty S, Fujita K. Comparison of 3 surgical approaches to laparoscopic adrenalectomy: a nonrandomized, background matched analysis. *J Urol* 2001 Aug; 166(2): 437 - 43
8. Toniato A, Piotto A, Pagetta C, Bernante P, Pelizzo MR. Techniques and results of laparoscopic adrenalectomy. *Langenbecks Arch Surg* 2001 Apr; 386(3): 200 - 3
9. Valeri A, Borrelli A, Presenti L, Lucchese M, Manca G, Tonelli P, Bergamini C, Borrelli D, Palli M, Saieva C. The influence of new technologies on laparoscopic adrenalectomy: our personal experience with 91 cases. *Surg Endosc* 2002 Sep;16(9): 1274 - 9
10. Propiglia F, Garrone C, Giraudo G, Destefanis P, Fontana D, Morino M. Transperitoneal laparoscopic adrenalectomy: experience in 72 procedures. *J Endourol* 2001 Apr;15(3): 275 - 9

สถาบันวิทยบริการ
จุฬาลงกรณ์มหาวิทยาลัย