

Necrotizing fasciitis: a case report and review

Prakobkiat Hirunwiwatkul*

Hirunwiwatkul P. Necrotizing fasciitis: a case report and review. Chula Med J 2002 Aug; 46(8): 659 - 68

A 62-year-old man presented to his physician with pain and swelling on the left side of his anterior chest wall, neck and upper back. He got increased swelling, pain, erythema and subcutaneous emphysema of his left side of the anterior chest wall, neck and upper back which later extended to the right side of his neck. Necrotizing fasciitis was diagnosed. He was admitted and computed tomography was done to delineate the anatomy, evaluate the extent of the infection, and evaluate whether or not operative debridement and pus drainage was adequate. He was taken into the operating room for debridement. Extensive necrosis of the skin, subcutaneous tissue and muscle with a large amount of pus collection in retropharyngeal and parapharyngeal space was encountered. Muscle debridement extended posteriorly from the pectoralis major to the paraspinalis muscles. Multiple operative debridements were performed over several days. The patient did not develop septic shock or required any ventilatory support due to early recognition and aggressive treatment. However, tracheostomy was done to prevent the rupture of retropharyngeal abscess during intubation.; operative debridement under general anesthesia were expected to be performed several times. Split-thickness skin grafts were placed on the 61st day of hospitalization. The patient eventually recovered and was discharged on the 69th day of hospitalization.

Key words : Necrotizing fasciitis, Deep neck infection.

Reprint request : Hirunwiwatkul P. Department of Otolaryngology, Faculty of Medicine,
Chulalongkorn University, Bangkok 10330, Thailand.

Received for publication. May 15, 2002.

ประกอบเกียรติ หิรัญวิวัฒน์กุล. รายงานผู้ป่วย necrotizing fasciitis. จุฬาลงกรณ์เวชสาร 2545 ๓.ค; 46(8): 659 - 68

ผู้ป่วยชายไทยอายุ 62 ปี มาพบแพทย์ด้วยอาการปวด บวม บริเวณคอ หน้าอก และหลังส่วนบนด้านซ้าย ต่อมาอาการปวด บวมเป็นมากขึ้น แดงและคล้ำได้เป็นเหมือนฟองอากาศใต้ผิวหนังบริเวณคอ หน้าอก และหลังส่วนบนด้านซ้าย และลุกลามไปยังคอด้านขวา ได้รับการวินิจฉัยว่าเป็น Necrotizing fasciitis และรับไว้รักษาตัวในโรงพยาบาล ผู้ป่วยได้รับการตรวจเอกซเรย์คอมพิวเตอร์ (Computed tomography) เพื่อให้ทราบถึงกายวิภาคและขอบเขตของการติดเชื้อ และเพื่อประเมินว่าการผ่าตัดรักษา (ตัดเนื้อตายและระบายหนอง) ที่ทำแล้วเพียงพอหรือไม่ ผลการผ่าตัดพบเนื้อตายของผิวหนัง เนื้อเยื่อใต้ผิวหนัง กล้ามเนื้อ และมีหนองจำนวนมากในช่องหลังคอกหอยและช่องด้านข้างคอกหอย (retropharyngeal and parapharyngeal space) กล้ามเนื้อที่ตายได้รับการตัดออกตั้งแต่ด้านหน้า บริเวณกล้ามเนื้อ pectoralis major ไปถึงกล้ามเนื้อด้านข้างของกระดูกสันหลัง ผู้ป่วยได้รับการผ่าตัดอีกหลายครั้งเพื่อตัดเนื้อตายและระบายหนอง ผู้ป่วยไม่มีอาการช็อกติดเชื้อ หรือการหายใจล้มเหลวจนต้องใช้เครื่องช่วยหายใจ เนื่องได้รับการดูแลรักษาทันเวลาและเพียงพอ อย่างไรก็ตามผู้ป่วยได้รับการเจาะคอเพื่อป้องกันการแตกของหนองในช่องหลังคอกหอย และเนื่องจากผู้ป่วยจำเป็นต้องได้รับการดมยาสลบผ่าตัดอีกหลายครั้ง ผู้ป่วยได้รับการผ่าตัดประณีต (Split-thickness skin graft) ในวันที่ 61 ของการอยู่โรงพยาบาล และได้ออกจากโรงพยาบาลในวันที่ 69

คำสำคัญ : Necrotizing fasciitis, Deep neck infection.

Necrotizing fasciitis⁽¹⁻³⁾ is potentially a fatal soft-tissue infection that occurs rarely in the head and neck region. It spreads rapidly through the fascial planes. It is characterized by soft tissue necrosis. It is a surgical emergency since it is often related to a high mortality rate especially in the elderly and immunocompromised patients. It may occur as a consequence of infection caused by *Streptococcus pyogenes* or as a result of a polymicrobial synergistic infection caused by aerobic, anaerobic, gram positive and gram negative organisms.⁽⁴⁾ Broad-spectrum parenteral antibiotics and surgical debridement are the mainstays of treatment. In the reviewed literature, necrotizing fasciitis of the neck is usually associated with surgery or trauma. Less frequently, an orodental or pharyngeal infection is the underlying cause.^(5,6)

Necrotizing cellulitis and fasciitis may be difficult to recognize, especially when the skin necrosis is not obvious. The diagnosis must be suspected when there are signs of severe sepsis (accelerated heart or respiratory rates, oliguria, mental confusion) and/or some of the following local symptoms or signs, namely: severe spontaneous pain, indurated edema, bullae, cyanosis, skin pallor, absence of lymphangitis, skin hypoesthesia, crepitation, muscle weakness and foul smell of exudates. A recent case-control study demonstrated that using ibuprofen increased the risk of cellulitis that complicated chickenpox in children. The risk of streptococcal necrotizing fasciitis increases when the patient has a contact with other patients infected by the same streptococcus.⁽⁷⁾

Seventy-one percent of the patients with positive tissue culture had multibacterial infections.⁽⁸⁾ There was an increase in mortality in cases of *beta*-Streptococcus infections with the following categories:

1) patient history (intravenous drug use; age <1 or >60 years), 2) comorbid conditions (cancer, renal disease, and congestive heart failure), 3) characteristics of clinical course (trunk involvement, positive blood cultures, peripheral vascular disease, and positive cultures for *beta*-streptococcus or anaerobic bacteria), and 4) quantitative timeline of clinical course (time: injury to diagnosis, diagnosis to treatment). Clearly, the mortality and morbidity associated with necrotizing fasciitis can be decreased with clinical awareness, early diagnosis, adequate surgical debridement, and intensive nursing care.

Cellulitis and necrotizing fasciitis can be distinguished by the depth of the cutaneous lesion and classically by the different bacteria implicated,⁽⁹⁾ MRI, when available, is a good technique to reveal the depth of the infection and necrosis. Surgery usually confirms the diagnosis and allows debridement of necrotized tissues. These dramatic infections have two clinical aspects,⁽¹⁰⁾ namely: superficial and deep. The hypodermic tissue necrosis is limited and does not affect the fascia. It is caused by the thrombosis of local vessels, followed by skin necrosis. Necrotizing fasciitis is more dramatic and much less frequent. Streptococcus is involved in most of the cases for both diseases, even if this is difficult to demonstrate.

Brun-Buisson C *et al.* classified necrotizing fasciitis into 3 major forms⁽¹¹⁾ : 1) Streptococcal fasciitis, caused by *beta*-hemolytic streptococci; it often follows a minor trauma, and increasingly associated to a streptococcal toxic shock syndrome (STTS); 2) Clostridial gangrene (often polymicrobial when developed on a open wound or after surgery); and 3) Synergistic gangrene due to mixed aerobic-anaerobic flora. Other apparently "primitive" necrotizing

fasciitis, caused by specific organisms, may occur in debilitated patients. The prognosis depends on age, comorbidity, and above all on the severity of the sepsis. Initial resuscitation involves controlling the hypotension and organ dysfunction which are associated with severe sepsis, and is usually dominated by severe hypovolemia. Penicillin G remains the key antibiotic for streptococcal and clostridial fasciitis, with a broad spectrum including enterobacteriaceae, streptococci and enterococci, and anaerobes (including *Bacteroides* spp.) in other types or when the etiology is unknown. In patients presenting with STSS, a combination of clindamycin (or rifampin) to penicillin is recommended,

Because of their effect on exotoxin production, administration of non-specific immunoglobulins also appears to improve the outcome of the affected patients. Early surgical debridement largely influences the prognosis. The prevention of complications associated with long-term intensive care, including early nutritional support and prevention of a thromboembolic disease are also important.

Hyperbaric oxygen therapy has not proved effective. However, there are two main reasons that support the use of hyperbaric oxygen (HBO₂)⁽¹²⁾: the polymorphism of the bacterial flora with a predominance of anaerobes, either strict or aerotolerant; and the tissue necrosis due to an extensive disseminated microvascular obstruction within the infected area. Association of HBO₂ to antibiotics and surgery is based on strong pathophysiological findings as well as on evidences from animal studies. Clinical evidence in human is still lacking, even published data support its use in severe cases.

The boundary of retropharyngeal space is the following: anterior border is buccopharyngeal fascia; posterior border, the alar part of deep cervical fascia. The superior border is the base of skull. Inferior border is the first and the second thoracic spine. The medial border is the midline raphe of the retro-pharyngeal fascia. Retropharyngeal abscess is usually found in children more than adult. In pediatrics, origin of the infection may be the infection of the nose, adenoid and paranasal sinus. In adult, it usually results from regional trauma, foreign body, and secondary infection from other neighboring spaces (parapharyngeal space, masticator space).

The parapharyngeal space is an upside-down pyramidal shaped space. Its base is on the base of skull and its apex is on the hyoid bone. The boundary of the parapharyngeal space is the following: its lateral border lies medial pterygoid muscles. The medial border is superior pharyngeal constrictor muscle. Its anterior border is pterygomandibular raphe. The postero-medial border is the prevertebral fascia which communicates freely with the retropharyngeal space. Parapharyngeal space infection was characterized by a triad: severe trismus, swelling behind the angle of the mandible, and bulging of the lateral pharyngeal walls.

Case report

A Thai 62-yr-old man presented with a complaint of swelling on his left neck for 4 days. He also had a low graded fever and a sore throat. Three days earlier he went to see a doctor at a private hospital and got 4 items of medicine: (Diclofenac sodium (25mg) 1x 3 pc; Norgesic 1x3 pc; Lorazepam (0.5mg) 1x1 hs, Felodipine (10mg) 1x1). He took all




Figure 1. Lesions on patient's neck and chest (day of admission)

of the medicine but did not feel better. The left neck swelling got worse and inflammation spread to left anterior chest wall, upper back and later extending to right-sided neck. He felt dysphagia especially with solid food.

Past history: He got pulmonary tuberculosis and has been treated with antituberculous drugs for 1 year.

Physical examination:

Vital signs: BT = 37.0 °C, BP = 130/80, PR = 90/minute, RR = 20/minute

Neck: Swelling with no fluctuation on both sides of the neck, more on the left side (Figure 1)

Oral cavity & Oropharynx: No trismus. Bulging of posterior and lateral pharyngeal wall, more on the left side. No dental caries.

Indirect laryngoscopy: pooling of saliva, normal movement of both true vocal cords.

Back: Swelling with tenderness on upper back (left side)

Lab:

CBC: Hct 37 %, WBC 11,150 (N 88 %, L 12),

Plt 257,000

Blood sugar 407, Na 122, K 4.5, Cl 88, CO₂ 26

BUN/Cr 37/1.5

Anti HIV negative

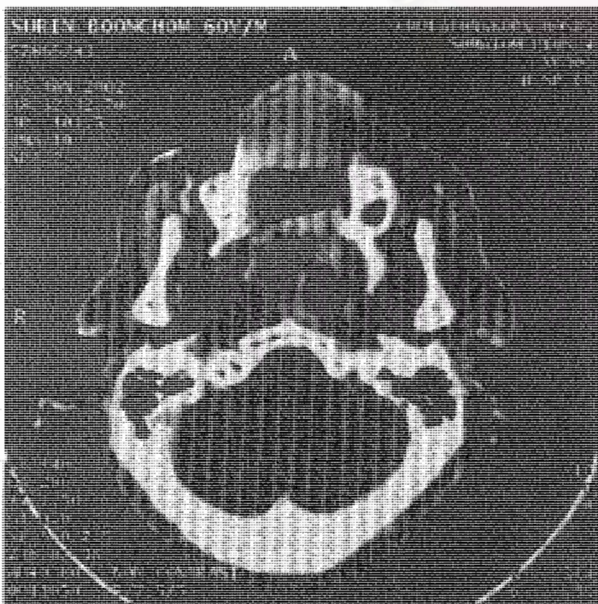


Figure 2. Thickening of prevertebral soft tissue and large amount of abnormal air bubbles in retropharyngeal and bilateral parapharyngeal spaces.

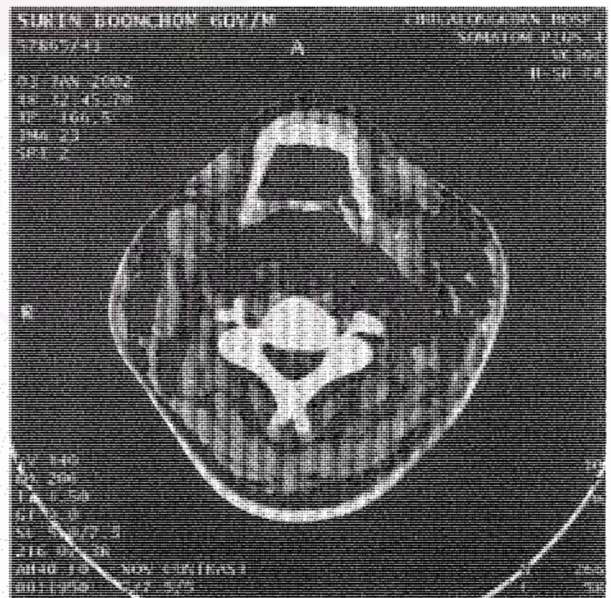


Figure 3. Thickening of prevertebral soft tissue and large amount of abnormal air bubbles in retropharyngeal space, extended to subcutaneous tissue of neck.

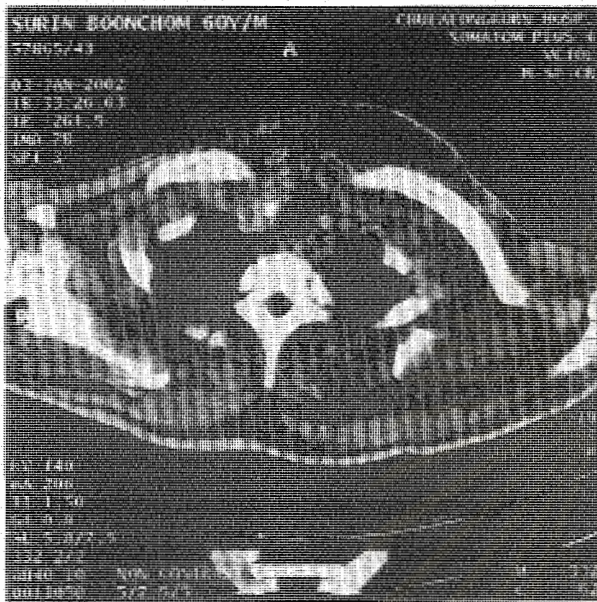

Figure 4. Extensive extension as following: inferiorly, to the level of thoracic inlet, anteriorly extended to subcutaneous tissue of lower anterior neck and anterior chest wall at level of manubrium sterni; posteriorly, extended to back muscles on the left side.

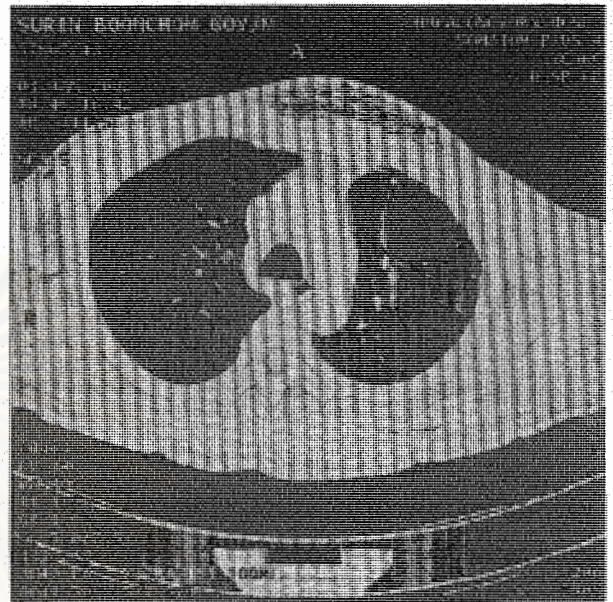


Figure 5. A cystic lesion at anterior segment of left upper lobe.

ECG:

Suspected left ventricular hypertrophy. Minor left axis deviation. S waves up to V6. Prolonged QT.

CT scan of larynx, infrahyoid neck and chest: (Figure 2-5) (day of admission)

The study reveals thickening of prevertebral soft tissue and containing large amount of abnormal air bubbles which shows extensive extension, more on the left side as following: superiorly, extended to the bilateral parapharyngeal spaces; inferiorly to the level of thoracic inlet; anteriorly, extended to subcutaneous tissue of lower anterior neck and anterior chest wall at level of manubrium sterni; posteriorly extended to back muscles on the left side.

The lesion shows heterogeneous slightly enhancement and causing anterolaterally displacement of the left carotid space. There are two necrotic lymph nodes at level IIa of right side that measured about 2 cm in short axis and level IIb of left side that measured about 0.7 cm in short axis, respectively. No evidence of osteolytic lesion is seen.

There is a 5x4x6 cm cystic lesion at anterior segment of left upper lobe and another two small cystic lesions at superior segment of left lower lobe with evidence of adjacent lung atelectasis.

Impression: Finding suggestive of gas forming infectious process within the prevertebral space with extensively extension as described with evidence of two necrotic lymph nodes at level IIb on the right side

and level IIa on the left side which measured about 2 cm and 0.7 cm in short axis, respectively.

A 5x4x6 cm cystic lesion at anterior segment of left upper lobe and two small cystic lesions at superior segment of left lower lobe with evidence of adjacent lung atelectasis, possibly lung cysts.

Nephrologist was consulted. Rising of BUN/Cr and hyponatremia indicated dehydration with prerenal azotemia. Hydration with normal saline was given. Fluid and volume management was treated with monitoring of urine output (via Foley's catheter) and central venous pressure (via Cavafix's catheter). Later when patient's condition was stable, oral sodium chloride (NaCl) supplement with nasogastric tube feeding was given. The patient's electrolyte and BUN/Cr improved and returned to normal within 2 weeks.

Endocrinologist was consulted. High blood sugar (407) indicated diabetes mellitus. Regular insulin was given.

General surgeon was consulted to take care of the abscess beneath left deep back muscle and join in the surgical team.

Operation: Tracheostomy + Operative debridement on both necks, left chest wall and back.

Emergency tracheostomy under local anesthesia was done to prevent the rupture of retropharyngeal abscess during intubation and multiple times of operative debridement under general anesthesia were expected.

Operative findings: Necrotic fascia with pus and air bubble on neck (left > right) and upper left anterior chest wall. Pus collection in left retropharyngeal space and both parapharyngeal spaces. Necrotic tissue beneath trapezius muscle (left) extending to subscapular area (left).

Operative procedure: Multiple parallel horizontal incisions on both necks and upper left anterior chest wall. Pus was removed and normal saline was used to irrigate in abscess cavity. Tube drains were inserted.

Pus taken and sent to Gram's stain, acid-fast bacilli, culture and susceptibility test.

- Gram negative bacilli organism and numerous PMN was found. *Klebsiella* sp. is likely.
- No organism on acid-fast stain.
- Anaerobic culture/susceptibility: negative
- Aerobic culture/susceptibility: *Klebsiella pneumoniae*. Heavy growth. It is sensitive to: ampicillin, cefazolin, cotrimoxazole, amoxicillin/clavulanic acid, gentamicin, netilmicin, amikacin, ciprofloxacin, vancomycin, sulperazone, tazocin, cefotaxime, ceftriazone, ceftacidime, imipenem, cefpirome, meropenem, cefepime

The given antibiotics were: ceftriaxone, gentamicin and metronidazole.

The patient did not develop septic shock or any ventilatory support due to early recognition and aggressive treatment. Operative debridement was performed once daily under general anesthesia. Computed tomography was repeated to access whether the operative debridement and pus drainage was adequate.

CT scan of larynx, infrahyoid neck and chest: (follow up)

The study shows soft tissue density lesions in bilateral nasal cavities and both maxillary sinuses, which are not seen on previous study, likely obstructed secretion. Four retained tube drains are observed in bilateral parapharyngeal and retropharyngeal spaces.

Much decrease in the amount of air in bilateral parapharyngeal and retropharyngeal spaces is seen. There is soft tissue swelling with fluid density, likely secretion occupying in the nasopharyngeal down to the oropharyngeal airway, almost causing obliteration of the airway. A tracheostomy tube is retained in place. Evidence of air is still observed in bilateral submandibular and buccal spaces, decreasing particularly on the right side. Decreased amount of air in left posterior cervical space is also noted. Evidence of open-skin drainage is visualized at bilateral neck from the level of angle of mandible down to cricoid cartilage, at the left sided back and left anterior chest wall. Decreased amount of air in the subcutaneous tissue along lateral aspect of bilateral sternocleidomastoid muscles is detected down to the subcutaneous tissue of back and anterior chest wall. There are round-oval shaped pockets of collection surrounded by rim enhancement, probably representing of abscess, the largest one, 1.8x2 cm in size, is located at posterior aspect of right mandibular angle. Other smaller ones are seen at left posterior cervical space at the level of hyoid bone. The chest study shows moderate amount of pleural effusion, bilaterally accompanying by minimal atelectasis. A large cavity and adjacent fibroreticular infiltration is observed in left upper lung, likely TB of indetermined stage, unchanged. Calcified aorta is detected, atherosclerosis change. The mediastinum appears unremarkable. No lymphadenopathy is demonstrated. Impression: Being compared to the previous study, decrease in amount of air in deep neck spaces and subcutaneous tissue of the neck, chest wall and back as described with evidence of retained tube drains, tracheostomy tube and open-skin drainages.

Multiple pockets of collection with rim enhancement, probably abscesses at posterior aspect of right angle of mandible and left posterior cervical space. Increase in amount of soft tissue swelling and secretion in nasopharyngeal and oropharynx and also increased amount of secretion in bilateral nasal cavities and right maxillary sinus.

Evidence of bilateral pleural effusion, accompanying by minimal atelectasis which is not seen in the previous study.

Atherosclerosis change of the thoracic aorta is noted.

Also noted is a cavity with fibroreticular infiltration at left upper lung, likely TB.

Histopathological report :

Gross examination: Specimen consists of an irregular dark brown tissue, measuring 1.2 x 0.7 x 0.3 cm

Microscopic examination: Section of fascia and striated muscle are diffusely infiltrating by numerous acute inflammatory cells. Some reveals foci of necrosis.

Diagnosis: Soft tissue (left neck) – Acute necrotizing inflammation

Multiple operative debridements were performed about 30 days until the condition of the wound infection improved, i.e., having no pus or necrotic tissue detected. Wet dressing was done twice a day after the operative debridement under general anesthesia. Wound on the back was sutured and a vacuum drain was inserted. Vacuum drain in wound on the back was removed on the 36th day of hospitalization. Tracheostomy tube was also removed on the 37th day of hospitalization because general anesthesia was not needed.




Figure 6. Patient's neck and chest wound (day of discharge).

Split-thickness skin grafts over left neck and chest wound were placed on the 61st day of hospitalization. The patient eventually recovered and was discharged on the 69th hospital day. (Figure 6)

Discussion

Necrotizing fasciitis is a life threatening bacterial infection of the fascial planes; it is relatively rare in the head and neck region. The hallmark of the disease is its extremely rapid progressive involvement of the superficial fascias and deep dermal layers of the skin, with resultant vasculitis and necrosis. Primary odontogenic infection due to aerobes and obligate anaerobes and trauma are frequently responsible for the condition but in this case there is no evidence of dental caries or any history of trauma. However, the patient got diclofenac sodium which is non-steroidal anti-inflammatory drug. This may be an aggravating factor of infection.⁽⁷⁾ Similarly, affected individuals

often have an underlying systemic disease, the most common of which is diabetes mellitus. Subcutaneous emphysema with crepitation on palpation found in soft tissue is reliable. Skin was tender, edema and reddish. Blister, bulla or slough may occur in 48 hours. Subcutaneous tissues are pale, edematous with fatty liquefaction. Significant morbidity and mortality attend necrotizing fasciitis when treatment is delayed, due to toxemia, dehydration and severe biochemical disturbances. Mortality rate is as high as 50 %.⁽¹³⁻¹⁵⁾ Prompt diagnosis, adequate resuscitation, thorough and frequent surgical debridement remains the cornerstone to a successful outcome.⁽¹⁶⁾ Not only thorough surgical debridement, treatment usually involves appropriate antimicrobial therapy, control of systemic disease. Debridement is recommended daily until the wound stabilizes. Complications include respiratory failure, delirium, mediastinitis, pericardial tamponade, DIC and neuropathy.

The interval between diagnosis and radical debridement appears to be the crucial factor in terms of prognosis, since early diagnosis and prompt, radical surgery improves the survival rate.⁽¹⁷⁾ Surgery is suggested after a short therapeutic test, if erythema does not regress after a few hours of antibiotic therapy. Surgery consists in excision of all the necrotic tissue. Deep necrotizing fasciitis calls for a really dramatic surgery with a high level of mortality and heavy functional sequels.

References

1. Cunningham JD, Silver L, Rudikoff D. Necrotizing fasciitis: a plea for early diagnosis and treatment. Mt Sinai J Med 2001 Sep-Oct; 68 (4-5):253 - 61

2. Derancourt C. Management of necrotizing cellulitis and fasciitis. *Ann Dermatol Venereol* 2001 Mar; 128(3 Pt 2):452 - 7
3. Kovacs LH, Kloeppel M, Papadopoulos NA, Reeker W, Biemer E. Necrotizing fasciitis. *Ann Plast Surg* 2001 Dec; 47(6):680 - 2
4. Cherneski CL, Embil JM. Necrotizing fasciitis. *Saudi Med J* 2001 Jul; 22(7):565 - 8
5. Francque SM, Van Laer C, Struyf N, Vermeulen P, Corthouts B, Jorens PG. Perforating oesophageal carcinoma presenting as necrotizing fasciitis of the neck. *Eur J Gastroenterol Hepatol* 2001 Oct; 13(10): 1261 - 4
6. Khan A, Ahmad N. Necrotising fasciitis managed without any surgical intervention. *Eye* 2001 Dec; 15(Pt 6):811 - 2
7. Roujeau JC. Necrotizing fasciitis. Clinical criteria and risk factors. *Ann Dermatol Venereol* 2001 Mar; 128(3 Pt 2):376 - 81
8. Childers BJ, Potyondy LD, Nachreiner R, Rogers FR, Childers ER, Oberg KC, Hendricks DL, Hardesty RA. Necrotizing fasciitis: a fourteen-year retrospective study of 163 consecutive patients. *Am Surg* 2002 Feb; 68(2):109 - 16
9. Cazorla C. What data is needed today to deal with cellulitis and necrotizing fasciitis?. *Ann Dermatol Venereol* 2001 Mar; 128(3 Pt 2): 443 - 51
10. Lortat-Jacob A. Subcutaneous infection and necrotizing fasciitis of the limbs in adults. Surgical treatment. *Ann Dermatol Venereol* 2001 Mar; 128(3 Pt 2):404 - 10
11. Brun-Buisson C. The therapeutic approach to necrotizing fasciitis. *Ann Dermatol Venereol* 2001 Mar; 128(3 Pt 2):394 - 403
12. Mathieu D. Hyperbaric oxygen for the treatment of necrotizing fasciitis. *Ann Dermatol Venereol* 2001 Mar; 128(3 Pt 2):411 - 8
13. Tung-Yiu W, Jehn-Shyun H, Ching-Hung C, Hung-An C. Cervical necrotizing fasciitis of odontogenic origin: a report of 11 cases. *J Oral Maxillofac Surg* 2000 Dec; 58(12): 1347 - 53
14. Loomis PW, Campbell HR. Fatal cervical necrotizing fasciitis (a report of two cases of confirmed odontogenic origin and one of possible odontogenic origin). *J Forensic Sci* 2001 Jul; 46(4):959 - 61
15. Sharkawy A, Low DE, Saginur R, Gregson D, Schwartz B, Jessamine P, Green K, McGeer A. Severe group a streptococcal soft-tissue infections in ontario: 1992- 1996. *Clin Infect Dis* 2002 Feb; 34(4):454 - 60
16. Ugboko VI, Assam E, Oginni FO, Amole AO. Necrotising fasciitis of the head and neck: a review of the literature. *Niger J Med* 2001 Jan - Mar; 10(1):6 - 10
17. Heitmann C, Pelzer M, Bickert B, Menke H, Germann G. Surgical concepts and results in necrotizing fasciitis. *Chirurg* 2001 Feb; 72(2): 168 - 73