

CHAPTER IV



RESULTS

The observation of each muscle in this study is generally arranged in four parts. A general description of a muscle, the descriptions of the internal tendons of origin and of insertion, and the arrangement and course of the muscle fibers.

Temporalis Muscle of Dog

General Description

The temporalis muscle is the biggest and strongest muscle of mastication of dog (Figs. 2 and 3). It arises from the orbital ligament, the external frontal crest, the lateral surface of the zygomatic arch and the temporal fossa. This muscle inserts on the coronoid process of the mandible and the ventral margin of the masseteric fossa. It blends with the masseter muscle at the zygomatic arch.

Internal Tendons of Origin

001723

Formula: Ao

The aponeurosis of origin, Ao (Fig. 6), is thick and oval in shape. It arises from the zygomatic process, sagittal crest and external occipital protuberance, then extends downwards to the orbital ligament and the nuchal crest, superiorly; the superior surface of the zygomatic arch, inferiorly.

Fig. 2 The lateral surface of the isolated temporalis
muscle of dog. Ao, aponeurosis of origin.

Fig. 3 The medial surface of the isolated temporalis
muscle of dog. Pi, primary lamina of insertion.

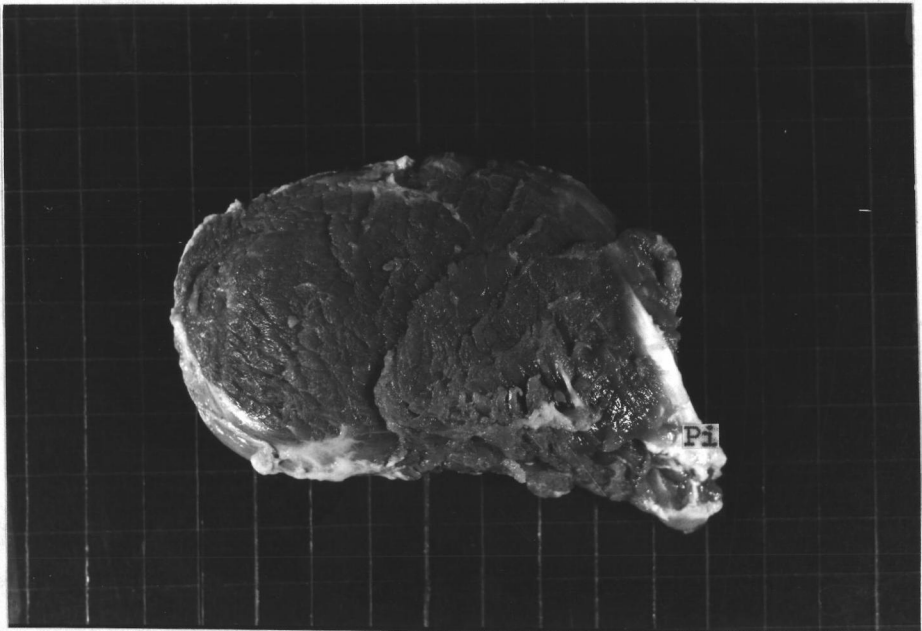
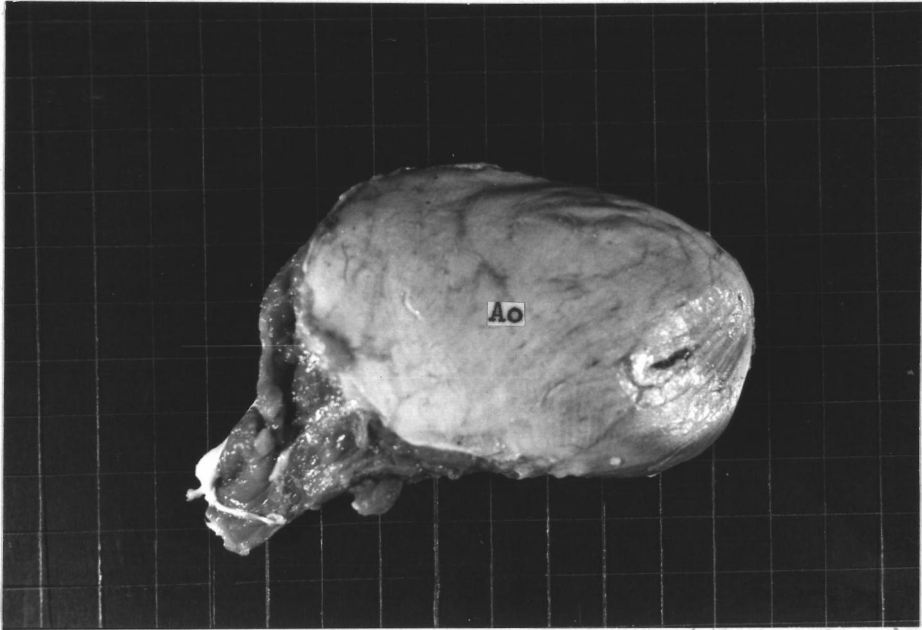

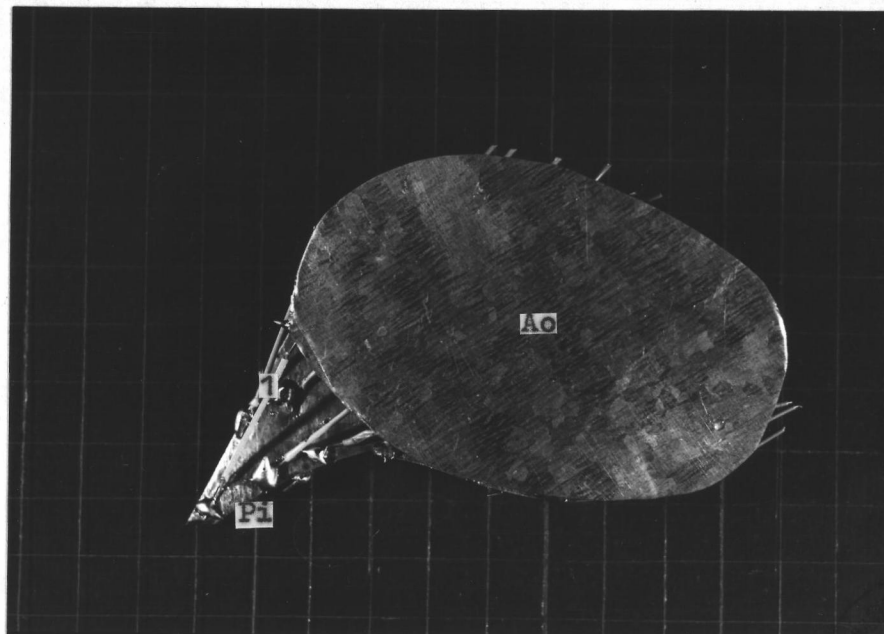
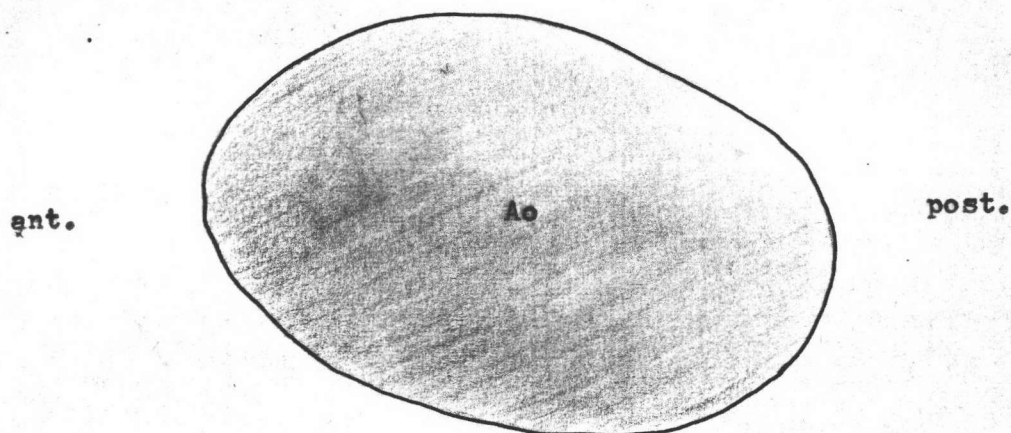


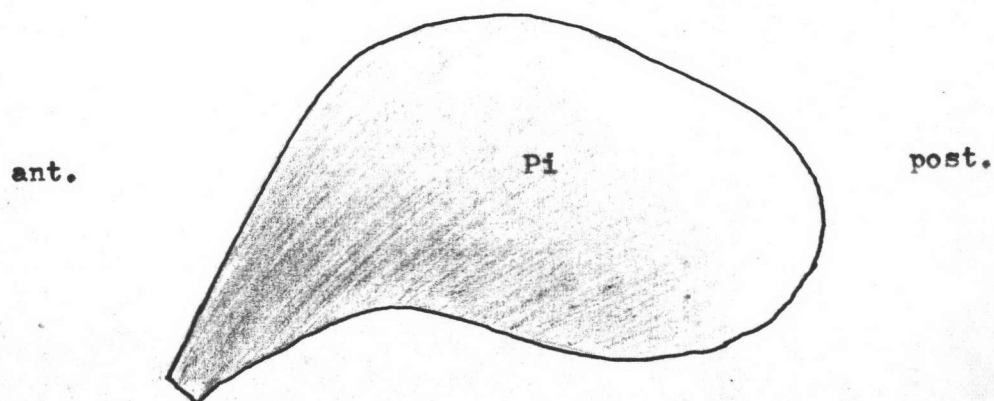
Fig. 4 The lateral aspect of the model of the temporalis muscle of dog. Compare with Fig. 2. Wires indicate directions of muscle fibers. Ao, aponeurosis of origin; Pi, primary lamina of insertion; 1, the first layer of muscle fibers.

Fig. 5 The medial aspect of the model of the temporalis muscle of dog. Compare with Fig. 3. Wires indicate directions of muscle fibers. Ao, aponeurosis of origin; Pi, primary lamina of insertion; 2, the second layer of muscle fibers.





6
Fig. 6 The diagram of the lateral surface of the aponeurosis of origin, Ao, of the temporalis muscle of deg.



7
Fig. 7 The diagram of the lateral surface of the primary lamina of insertion, Pi, of the temporalis muscle of deg.

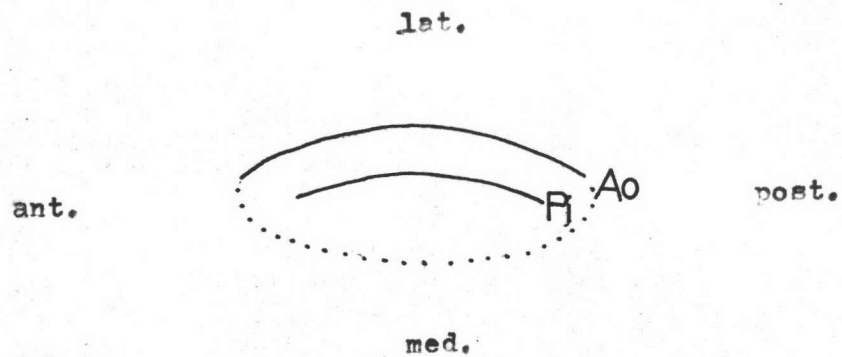


Fig. 8 The diagram of horizontal section of the temporalis muscle of dog. Dotted line indicates the medial surface of the muscle. Ao, aponeurosis of origin; Pi, primary lamina of insertion.

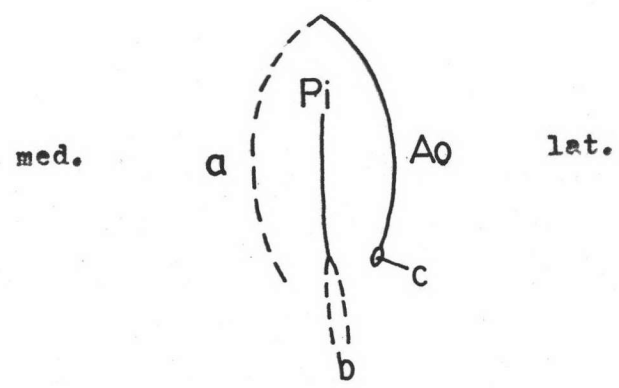


Fig. 9 The diagram of vertical section of the temporalis muscle of dog. a, the temporal fossa; b, the coronoid process of mandible; c, the zygomatic arch. Ao, aponeurosis of origin; Pi, primary lamina of insertion.

Internal Tendons of Insertion

Formula: Pi

There is no aponeurosis of insertion. The primary lamina of insertion, Pi (Fig. 7), arises directly from the coronoid process of the mandible. It has a quadrilateral shape with an extension of its antero-ventral margin. The size of the primary lamina of insertion, Pi, is the same as that of the aponeurosis of origin, Ao. It lies medially to the aponeurosis of origin, Ao (Figs. 8 and 9).

The Arrangement of the Muscle Fibers (Figs. 4 and 5)

The muscle fibers which arise from the deep aspect of the aponeurosis of origin, Ao, pass antero-medially to the lateral surface of the primary lamina of insertion, Pi, whereas most anterior fibers from the aponeurosis of origin, Ao, pass anteriorly and insert on the lateral surface of the coronoid process and the adjacent part of the mandible. The deep muscle fibers which arise from the floor of the temporal fossa, extend antero-laterally and insert on the medial surface of the primary lamina of insertion, Pi, and the medial surface of the coronoid process and the adjacent part of the mandible.

Masseter Muscle of Dog

General Description

The masseter muscle of dog (Figs. 10 and 11) is a strong muscle which is situated at the lateral side of the mandible. It is covered by a strong aponeurosis. This muscle arises from the

ventral and medial borders of the zygomatic arch. It runs postero-ventrally to insert on the ventro-lateral surface of the mandible and the ventral margin of the masseteric fossa. Some fibers from the medial surface of the zygomatic arch fuse with that of temporalis muscle.

Internal Tendons of Origin

Formulae: Ao , Po_1 , Po_2

The aponeurosis of origin, Ao (Fig. 14), is strong and ellipsoid in shape. It arises from the ventral border of the zygomatic arch and extends downwards cover the lateral surface of the muscle. At its anterior margin, there is a little reflection to the medial surface of the muscle.

There are two primary laminae of origin, Po_1 and Po_2 . Both of them arise from the medial surface of the posterior part of the zygomatic arch. The primary lamina of origin, Po_1 (Fig. 15), is quadrilateral shape and lies medial to the aponeurosis of origin, Ao . The primary lamina of origin, Po_2 (Fig. 16), is a long quadrilateral shape and is situated at the medial surface of the muscle, medial to the primary lamina of origin, Po_1 .

Internal Tendons of Insertion

Formulae: Pi_1 , Pi_2

No aponeurosis of insertion is visible. There are two primary laminae of insertion, Pi_1 and Pi_2 . The primary lamina of insertion, Pi_1 (Fig. 17), is a trapezoid in shape with a bifurcate

Fig. 10 The lateral surface of the isolated masseter muscle of dog. Ao, aponeurosis of origin.

Fig. 11 The medial surface of the isolated masseter muscle of dog. Po₂, primary lamina of origin; Pi₁, primary lamina of insertion which is situated medial to the aponeurosis of origin, Ao (not visible, see Fig. 10).

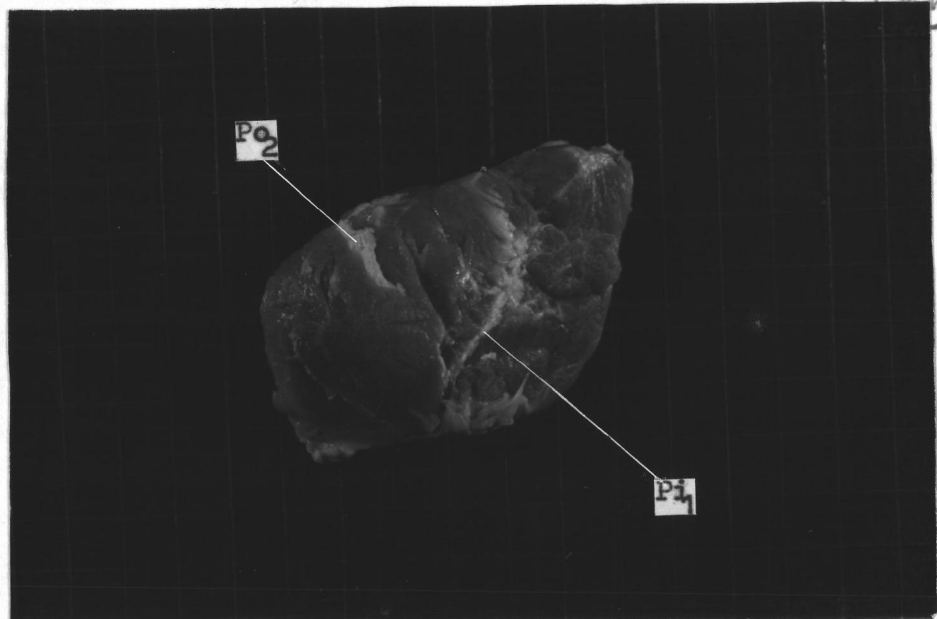
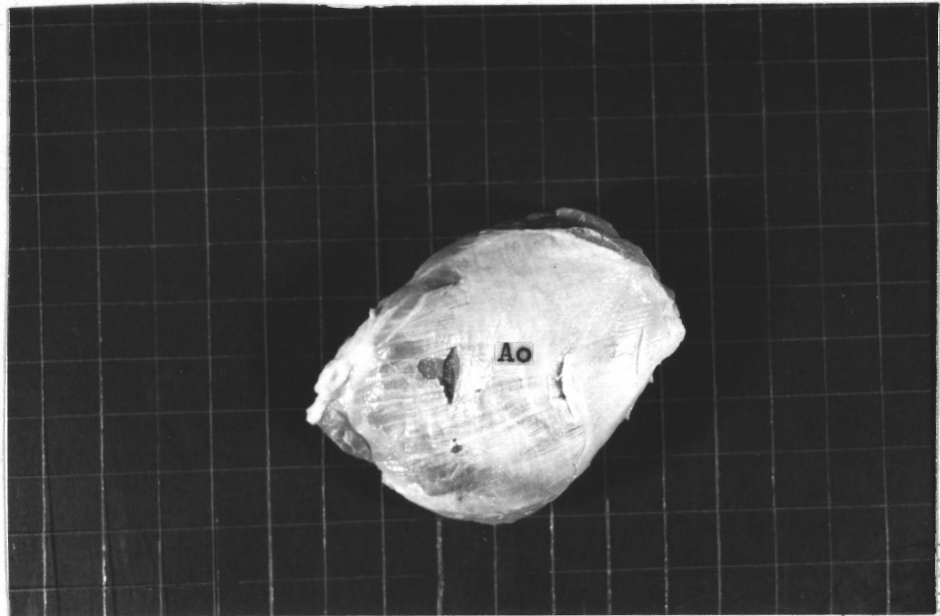
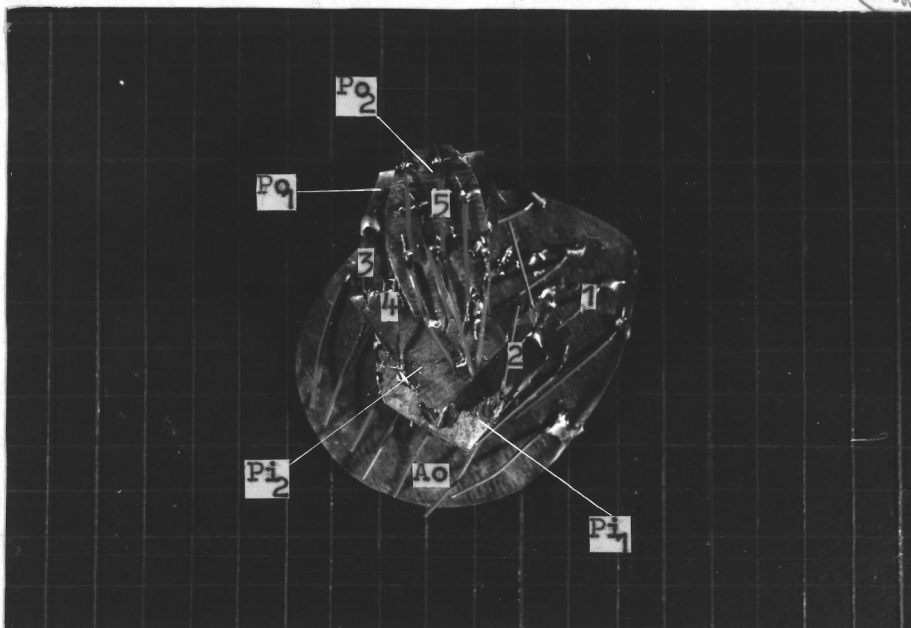

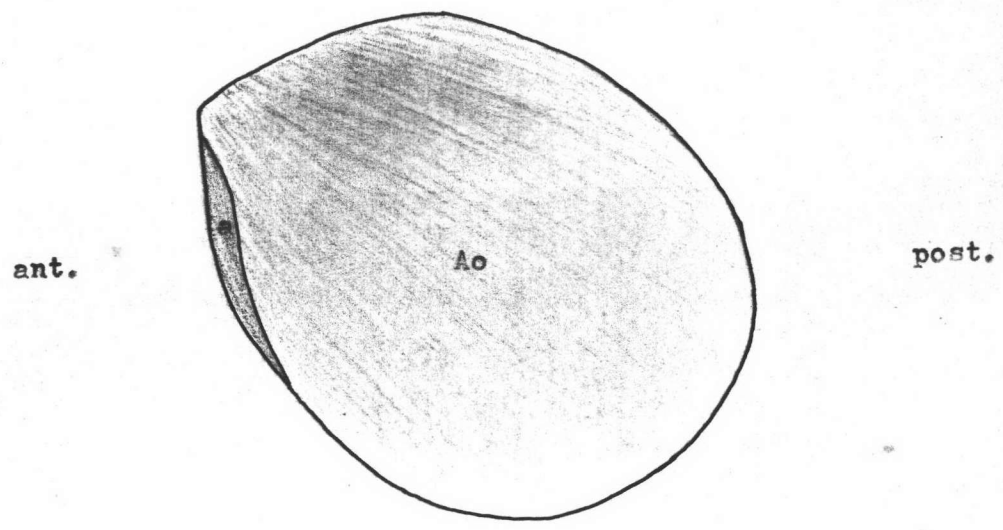


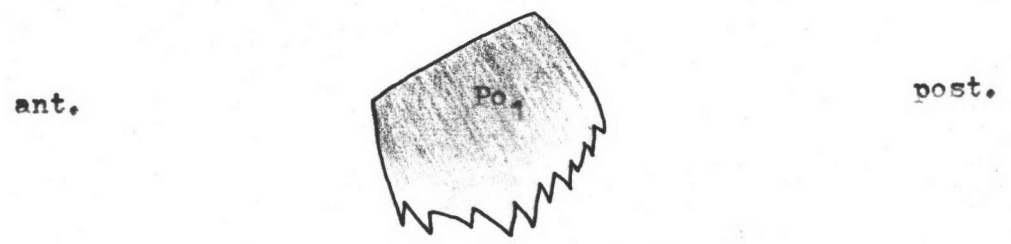
Fig. 12 The lateral aspect of the model of the masseter muscle of dog. Compare with Fig. 10. Wires indicate directions of muscle fibers. Ao, aponeurosis of origin; Po₁, primary lamina of origin.

Fig. 13 The medial aspect of the model of the masseter muscle of dog. Compare with Fig. 11. Wires indicate directions of muscle fibers. Ao, aponeurosis of origin; Po₁ and Po₂, primary laminae of origin. Pi₁ and Pi₂, primary laminae of insertion. 1,2,3,4, and 5 are the first, second, third, fourth and fifth layer of muscle fibers.





14 Fig. 14 The diagram of the medial surface of the aponeurosis of origin, Ao, of the masseter muscle of dog, with its reflection, a.



15 Fig. 15 The diagram of the medial surface of the primary lamina of origin, Po1, of the masseter muscle of dog.

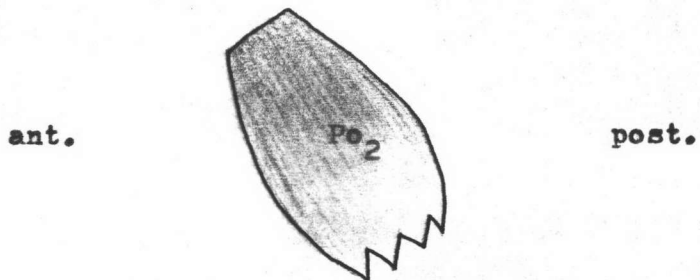


Fig. 16 The diagram of the medial surface of the primary lamina of origin, Po_2 , of the masseter muscle of dog.

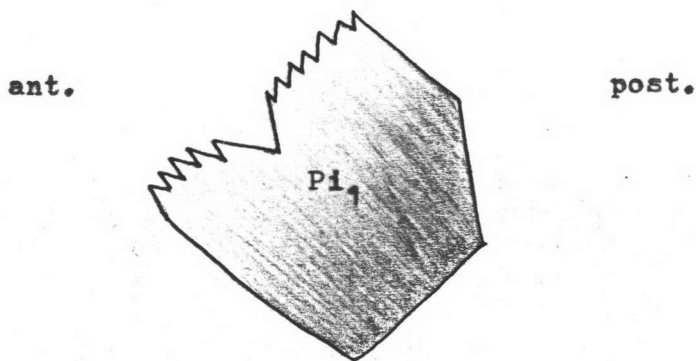


Fig. 17 The diagram of the medial surface of the primary lamina of insertion, Pi_1 , of the masseter muscle of dog.

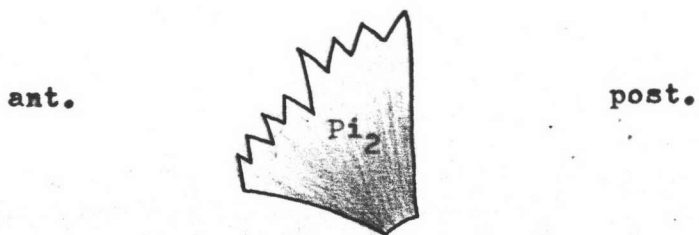


Fig. 18 The diagram of the medial surface of the primary lamina of insertion, Pi_2 , of the masseter muscle of dog.

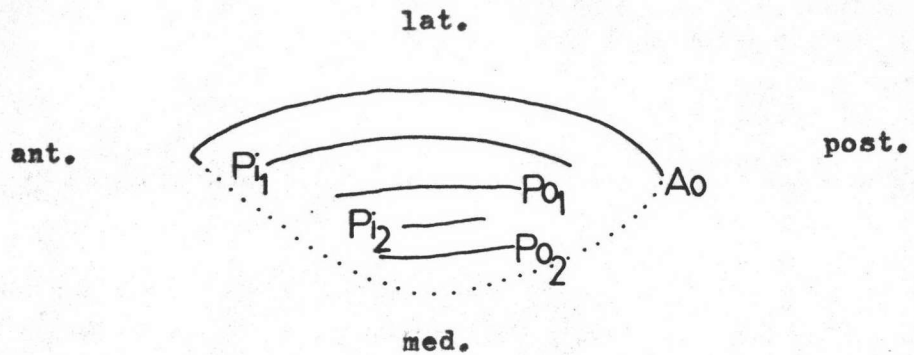


Fig. 19 The diagram of horizontal section of the masseter muscle of dog. Dotted line indicates the medial surface of the muscle. Ao, aponeurosis of origin; Po₁ and Po₂, primary laminae of origin; Pi₁ and Pi₂, primary laminae of insertion.

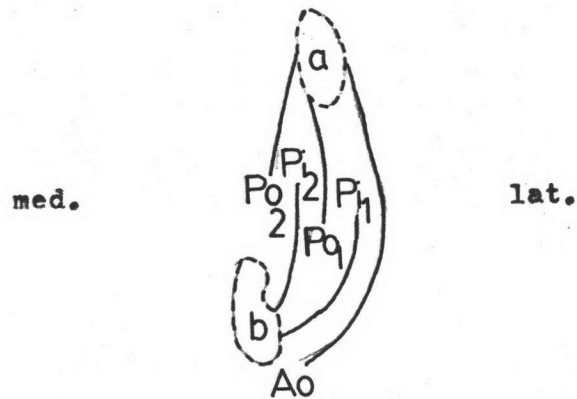


Fig. 20 The diagram of vertical section of the masseter muscle of dog. a, the zygomatic arch; b, the mandible. Ao, aponeurosis of origin; Po₁ and Po₂, primary laminae of origin; Pi₁ and Pi₂, primary laminae of insertion.

antero-dorsal margin. It arises from the angular process and the posterior and ventral margin of the mandible. This primary lamina of insertion, Pi_1 , extends upwards and lies between the aponeurosis of origin, Ao , and the primary lamina of origin, Po_1 .

The primary lamina of insertion, Pi_2 (Fig. 18), is a triangular shape which originates from the postero-ventral margin of the masseteric fossa. It extends upwards and lies between the primary laminae of origin, Po_1 and Po_2 .

The Arrangement of the Muscle Fibers (Fig. 13)

This muscle is divided into five layers of muscle fibers. From lateral to medial, the fibers of the first layer arise from the medial surface of the aponeurosis of origin, Ao . They run downwards to insert on the lateral surface of primary lamina of insertion, Pi_1 , and the postero-lateral surface of the mandible. The fibers of the second layer which originate from the lateral surface of the primary lamina of origin, Po_1 , pass downwards to terminate at the medial surface of the primary lamina of insertion, Pi_1 . In third layer, the fibers arise from the medial surface of the primary lamina of origin, Po_1 . They pass downwards to insert on the lateral surface of the primary lamina of insertion, Pi_2 . The fourth and the fifth layers lie in the masseteric fossa. The fibers of the fourth layer which originate from the lateral surface of the primary lamina of origin, Po_2 , run downwards to terminate at the medial surface of the primary lamina of insertion, Pi_2 . In the fifth layer, the fibers arise from the medial surface of the primary lamina of origin, Po_2 .

They pass downwards to insert on the floor of the masseteric fossa.

Pterygoid Muscle of Dog

General Description

The pterygoid muscle of dog (Figs. 21 and 22) is not divided into the medial and lateral pterygoid muscles. It originates from the pterygopalatine fossa and runs postero-ventrally to insert on the medial surface, posterior margin, and the condyle of the mandible.

Internal Tendons of Origin

Formulae: Po_1 , Po_2

No aponeurosis of origin is visible. There are two primary laminae of origin, Po_1 and Po_2 . The primary lamina of origin, Po_1 (Fig. 25), is a pear-like in-shape which arises from the lateral surface of the palatine bone. It runs horizontally.

The primary lamina of origin, Po_2 (Fig. 26), is a long quadrilateral shape which arises from the lateral surface of the pterygoid, palatine, and sphenoid bones. It passes horizontally and embeds in the posterior part of the muscle.

Internal Tendons of Insertion

Formulae: Ai_1 , Ai_2 , Ai_1' , Pi

There are two aponeuroses of insertion, Ai_1 and Ai_2 . The aponeurosis of insertion, Ai_1 (Fig. 27), is a trapezoid shape with an extension, Ai_1' , on its postero-ventral margin. This aponeurosis, Ai_1 , arises from the medial surface of the ramus of the

Fig. 21 The lateral aspect of the isolated pterygoid muscle of dog. Ai_1 , aponeurosis of insertion with its extension, Ai_1' , and its primary lamina of insertion, Pi ; Ai_2 , aponeurosis of insertion.

Fig. 22 The medial aspect of the isolated pterygoid muscle of dog. Po_2 , the primary lamina of origin lied in the muscle mass.

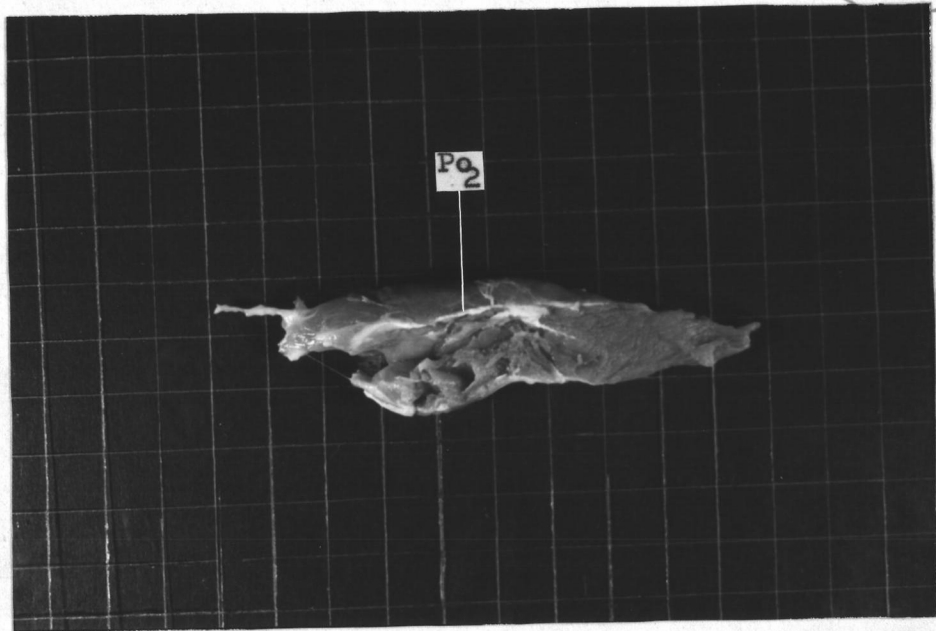
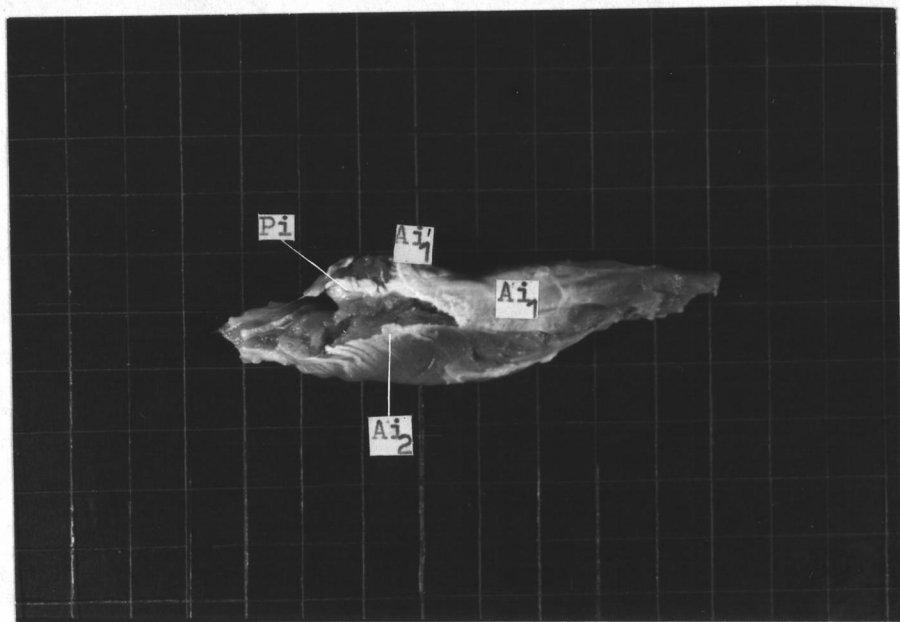



Fig. 23 The lateral aspect of the model of the pterygoid muscle of dog. Compare with Fig. 21. Wires indicate directions of muscle fibers. Ai_1 , aponeurosis of insertion which give off the primary lamina of insertion, Pi , and the extension, Ai_1' ; Ai_2 , aponeurosis of insertion. Po_1 and Po_2 , primary laminae of origin. 2, 3, and 4 are the second, third, and fourth layers of muscle fibers.

Fig. 24 The medial aspect of the model of the pterygoid muscle of dog. Compare with Fig. 22. Wires indicate directions of muscle fibers. Ai_1 and Ai_2 , aponeuroses of insertion; Pi , primary lamina of insertion. Po_1 and Po_2 , primary laminae of origin. 1, 2, and 3 are the first, second, and third layers of muscle fibers.



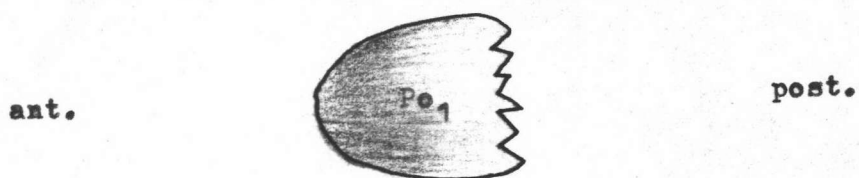


Fig. 25 The diagram of the ventral surface of the primary lamina of origin, Po_1 , of the pterygoid muscle of dog.

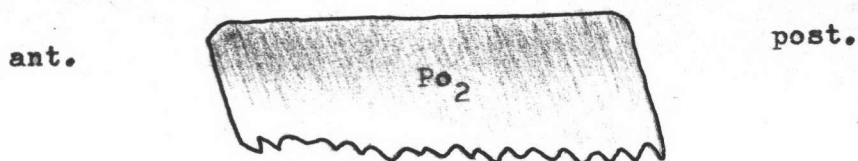


Fig. 26 The diagram of the ventral surface of the primary lamina of origin, Po_2 , of the pterygoid muscle of dog.

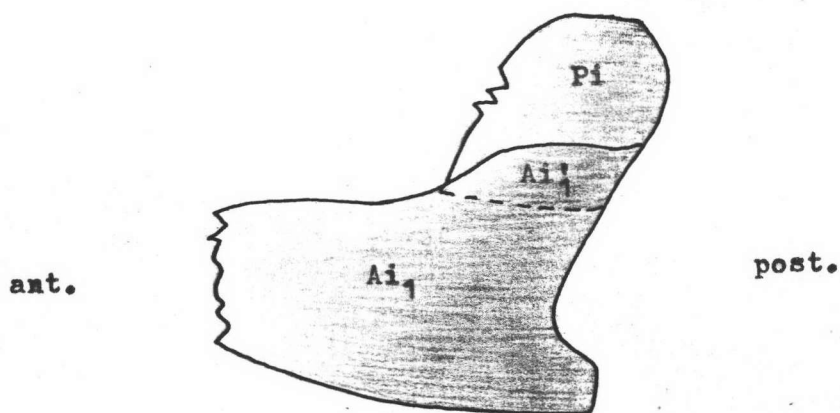


Fig. 27 The diagram of the lateral surface of the aponeurosis, of insertion, Ai_1 , of the pterygoid muscle of dog, showing its extension, Ai_1' , and the primary lamina of insertion, Pi .

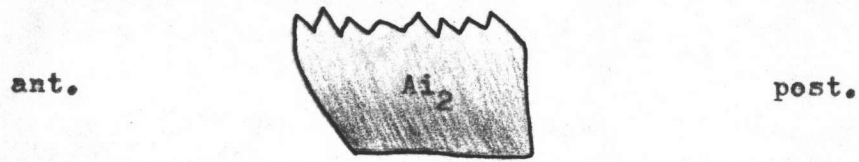


Fig. 28 The diagram of the ventral surface of the aponeurosis of insertion, Ai_2 , of the pterygoid muscle of dog.

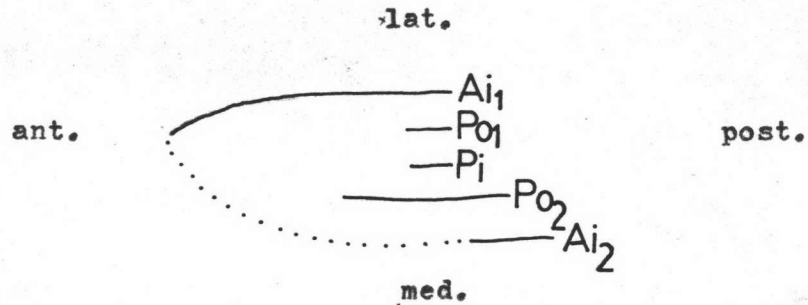


Fig. 29 The diagram of horizontal section of the pterygoid muscle of dog. Dotted line indicates the medial surface of the muscle. Po_1 and Po_2 , primary laminae of origin; Ai_1 and Ai_2 , aponeuroses of insertion; Pi , primary lamina of insertion.

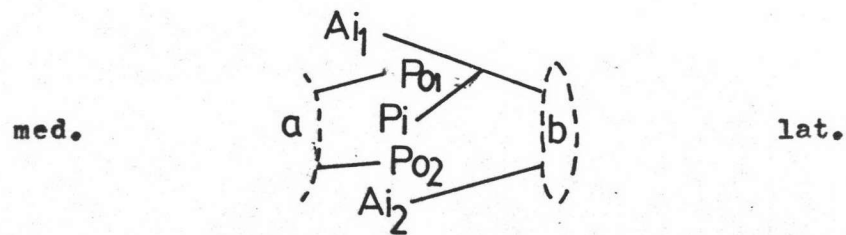


Fig. 30 The diagram of vertical section of the pterygoid muscle of dog. a, the pterygoid bone; b, the mandible. Po_1 and Po_2 , primary laminae of origin; Ai_1 and Ai_2 , aponeuroses of insertion; Pi , primary lamina of insertion.

mandible and extends anteriorly parallel to the body of the mandible.

The aponeurosis of insertion, Ai_2 (Fig. 28), is a quadrangular shape which originates from the ventral margin of the mandible. It runs horizontally to cover the postero-ventral surface of the muscle.

The primary lamina of insertion, Pi (Fig. 27), extends from the deep surface of the aponeurosis of insertion, Ai_1 , into the muscle mass. It runs between the primary laminae of origin, Po_1 and Po_2 .

The Arrangement of the Muscle Fibers (Figs. 23 and 24)

The muscle mass is composed of four layers of muscle fibers. From ventral to dorsal, the fibers of the first layer arise from the ventral surface of the primary lamina of origin, Po_2 . They pass posteriorly to insert on the dorsal surface of the aponeurosis of insertion, Ai_2 . In the second layer, the fibers are divided into two parts. The anterior fibers which arise from the lateral surface of the pterygopalatine fossa, pass posteriorly to insert on the medial surface of the aponeurosis of insertion, Ai_1 . The posterior fibers originate from the dorsal surface of the primary lamina of origin, Po_2 . They pass posteriorly to insert on the ventral surface of the primary lamina of insertion, Pi . The fibers of the third layer which originate from the ventral surface of the primary lamina of origin, Po_1 , pass posteriorly to terminate at the dorsal surface of the primary lamina of insertion, Pi . In the fourth layer, the fibers arise from the dorsal surface of the primary lamina of origin,

Po₁, they pass posteriorly to insert on the medial surface of the extension of the aponeurosis of insertion, Ai₁.

Temporalis Muscle of Ox

General Description

The temporalis muscle of ox (Figs. 31 and 32) is a strong and thick muscle which is covered by an aponeurosis. It fills the temporal fossa and is, therefore, situated on the lateral aspect of the cranium. It arises from the temporal fossa and the muscle fibers pass to a strong tendon of insertion, which inturn, inserts on the coronoid process on the proximal extremity of the ramus of mandible and the dorsal part of the alveolar border.

Internal Tendons of Origin

Formula: Ao

The aponeurosis of origin, Ao (Fig. 35), is a large, thin and trapezoid-like in shape. It originates from the posterior orbital bone, upper margin of the temporal fossa, and nuchal crest, superiorly; and the upper margin of the zygomatic arch, inferiorly. This aponeurosis, Ao, and the temporal fossa form the lateral and medial roof of the muscle as an inverted V-shape.

Internal Tendons of Insertion

Formulae: Pi, Si₁, Si₂, Si₃

No aponeurosis of insertion for this muscle is found. The primary lamina of insertion, Pi (Fig. 36), extends from the coronoid process of the mandible deep in the muscle mass. This

Fig. 31 The lateral surface of the isolated temporalis muscle of ox. Ao, aponeurosis of origin.

Fig. 32 The medial surface of the isolated temporalis muscle of ox. Pi, primary lamina of insertion gave off the secondary laminae of insertion, Si₁, Si₂, and Si₃.

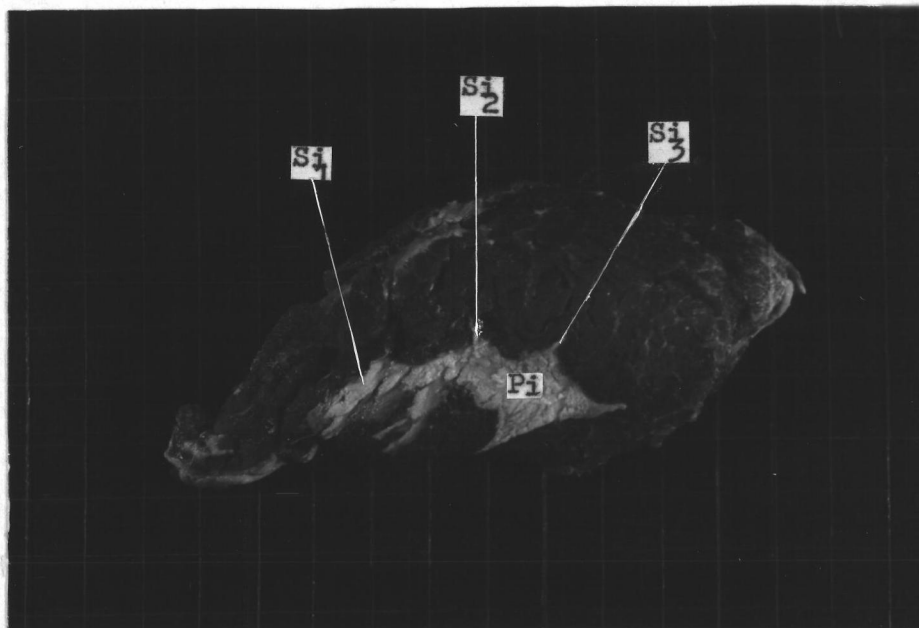
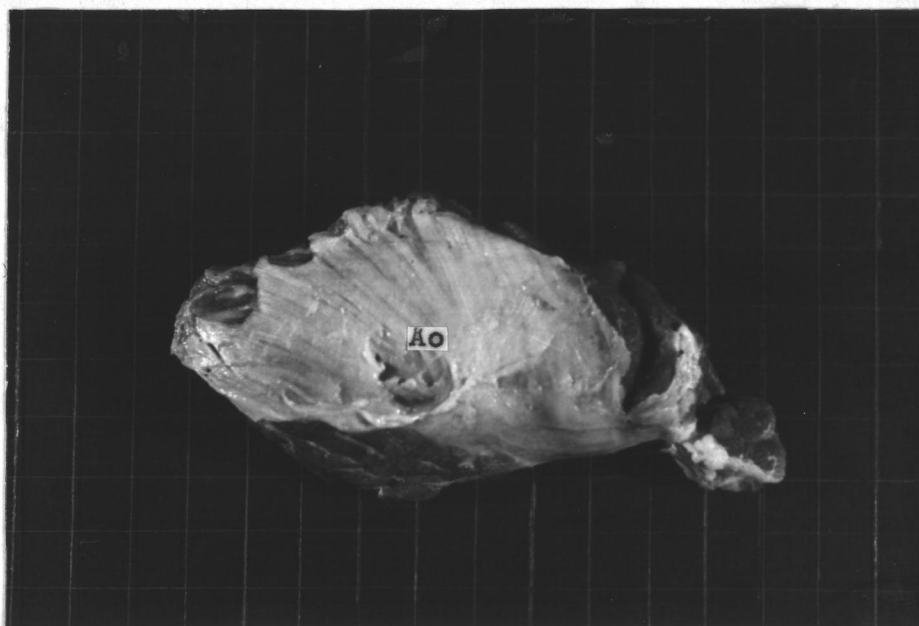
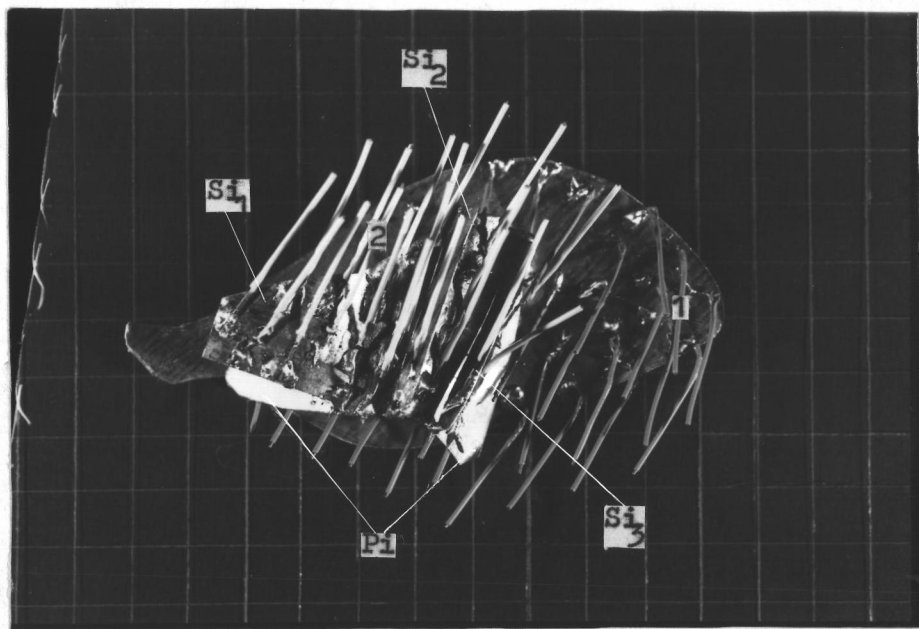



Fig. 33 The lateral aspect of the model of the temporalis muscle of ox. Compare with Fig. 31. Wires indicate directions of muscle fibers. Ao, aponeurosis of origin.

Fig. 34 The medial aspect of the model of the temporalis muscle of ox. Compare with Fig. 32. Wires indicate directions of muscle fibers. Pi, primary lamina of insertion; Si₁, Si₂, and Si₃, secondary laminae of insertion arise from the medial aspect of the primary lamina of insertion, Pi. 1 and 2 are the first and second layers of muscle fibers.



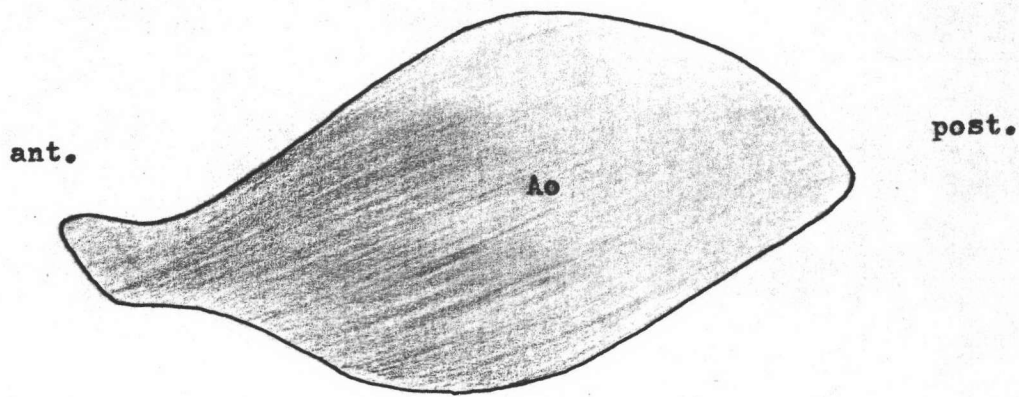


Fig. 35 The diagram of the medial surface of the aponeurosis of origin, Ao, of the temporalis muscle of ox.

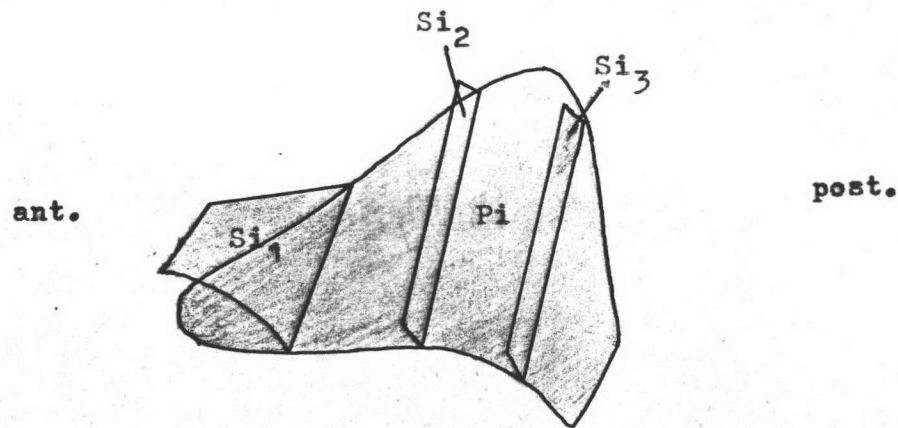


Fig. 36 The diagram of the medial surface of the primary lamina of insertion, Pi, of the temporalis muscle of ox, showing the secondary laminae of insertion, Si₁, Si₂, and Si₃.

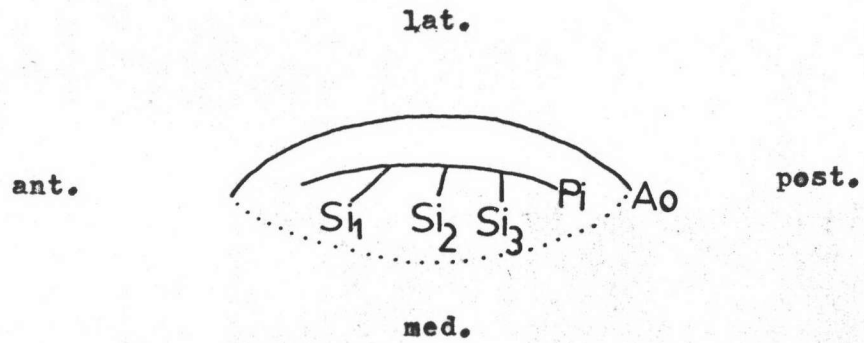


Fig. 37 The diagram of horizontal section of the temporalis muscle of ox. Dotted line indicates the medial surface of the muscle. Ao, aponeurosis of origin; Pi, primary lamina of insertion; S₁, S₂, and S₃, secondary laminae of insertion.

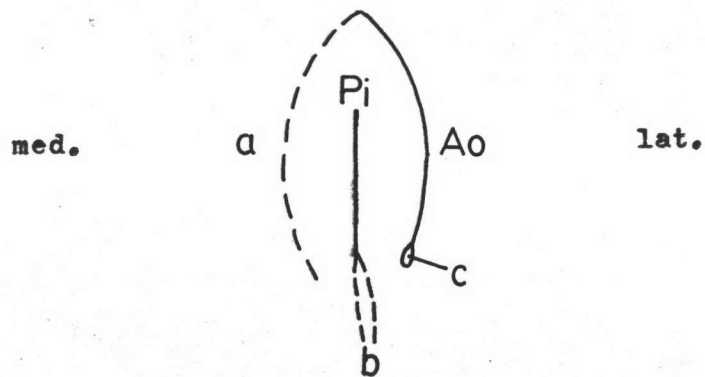


Fig. 38 The diagram of vertical section of the temporalis muscle of ox. a, the temporal fossa; b, the coronoid process of mandible; c, the zygomatic arch. Ao, aponeurosis of origin; Pi, primary lamina of insertion.

primary lamina, Pi is smaller than the aponeurosis of origin, Ao. Its upper border is convex but its lower border is concave. It is situated medially to the aponeurosis of origin, Ao. There are three secondary laminae of insertion, Si₁, Si₂, and Si₃ (Fig. 36). They arise from the medial surface of the primary lamina of insertion, Pi, in an almost parallel vertical array. The secondary lamina, Si₁, is thin, and trapezoid-like in shape. It arises from the anterior one-fourth of the primary lamina of insertion, Pi, and extends obliquely to the anterior part of the muscle. Other secondary laminae of insertion, Si₂ and Si₃, are nearly the same size and arise from the middle and the posterior-fourth of the primary lamina of insertion, Pi, respectively. Both of them are long, thin and narrow quadrangular shape.

The Arrangement of the Muscle Fibers (Figs. 33 and 34)

Muscle fibers that originate from the medial aspect of the aponeurosis of origin, Ao, pass antero-medially and terminate at the lateral surface of the primary lamina of insertion, Pi. Most anterior fibers from the aponeurosis of origin, Ao, pass antero-medially and insert on the antero-lateral surface of the coronoid process. The deep muscle fibers which arise from the temporal fossa pass downwards to the medial aspect of the primary lamina of insertion, Pi, and its secondary laminae of insertion, Si₁, Si₂, and Si₃. Most inferior fibers insert on the medial surface of the coronoid process.

Masseter Muscle of Ox

General Description

The masseter muscle of ox (Figs. 39 and 40) is a short, wide and thick muscle. It is composed of several layers intersected by tendinous bands and is covered at its lateral part by a strong aponeurotic sheath. Due to the difference in the direction of the muscle fibers, the masseter muscle can be divided into two parts; the anterior and posterior parts. The anterior part arises from the facial tuberosity of the maxilla and the zygomatic arch. The posterior part originates from the posterior border of the zygomatic process of the temporal bone. This muscle terminates on the upper part of the horizontal ramus and on the external surface of the vertical ramus of mandible.

Internal Tendons of Origin

Formulae: Ao_1 , Ao_2 , Ao_1' , Po_1 , Po_2 , Po_3

This muscle has two aponeuroses of origin, Ao_1 and Ao_2 . The aponeurosis of origin, Ao_1 (Fig. 43), is a strong, thick and broad tendon which arises from the facial tuberosity and zygomatic arch. It runs obliquely in the postero-ventral direction and covers the lateral surface of the muscle. Along its anterior margin, it reflects toward the medial surface as the reflected part, Ao_1' , of the aponeurosis of origin. In conjunction with this, a primary lamina of origin, Po_1 , arises from the postero-dorsal margin of the aponeurosis of origin, Ao_1 (Fig. 43). This primary lamina of origin is rather rectangular with a curved ventral margin. It lies

medially to the aponeurosis of origin, Ao_1 .

The aponeurosis of origin, Ao_2 (Fig. 45), is trapezoid in shape. It arises from the lateral surface of the maxilla. At its posterior border, it is continued as a triangular primary lamina of origin, Po_2 . Both of them are situated at the deep surface of the muscle.

The primary lamina of origin, Po_3 (Fig. 47), is the primary lamina of origin of the posterior part of the muscle. This primary lamina of origin, Po_3 , is a quadrangular shaped tendinous expansion. It arises from the posterior border of the zygomatic process of the temporal bone, and lies posteriorly to the primary lamina of origin, Po_1 (Fig. 42).

Internal Tendons of Insertion

Formulae: Ai, Pi_1, Pi'_1, Pi_2

The aponeurosis of insertion, Ai (Fig. 46), is in the anterior part of the muscle. It is a long quadr-angular shaped tendinous sheet which originates from the upper part of the lateral surface of the ramus of the mandible and lies at the medial aspect of the muscle (Fig. 42).

The primary lamina of insertion, Pi_1 (Fig. 44), is the primary lamina of the anterior part of the muscle. It originates from the lower part of the lateral surface of the ramus and lies between the aponeurosis of origin, Ao_1 , and the primary lamina of origin, Po_1 . This primary lamina of insertion, Pi_1 , is quadrilateral with a curved ventral border and lies parallel to the ventral border

Fig. 39 The lateral surface of the isolated masseter muscle of ox. Ao_1 , aponeurosis of origin; Pi_2 , primary lamina of insertion of the posterior part.

Fig. 40 The medial surface of the isolated masseter muscle of ox. Ao_2 , aponeurosis of origin; Ai , aponeurosis of insertion; Pi_1 , primary lamina of insertion gave off the reflected part, Pi'_1 , of primary lamina of insertion.

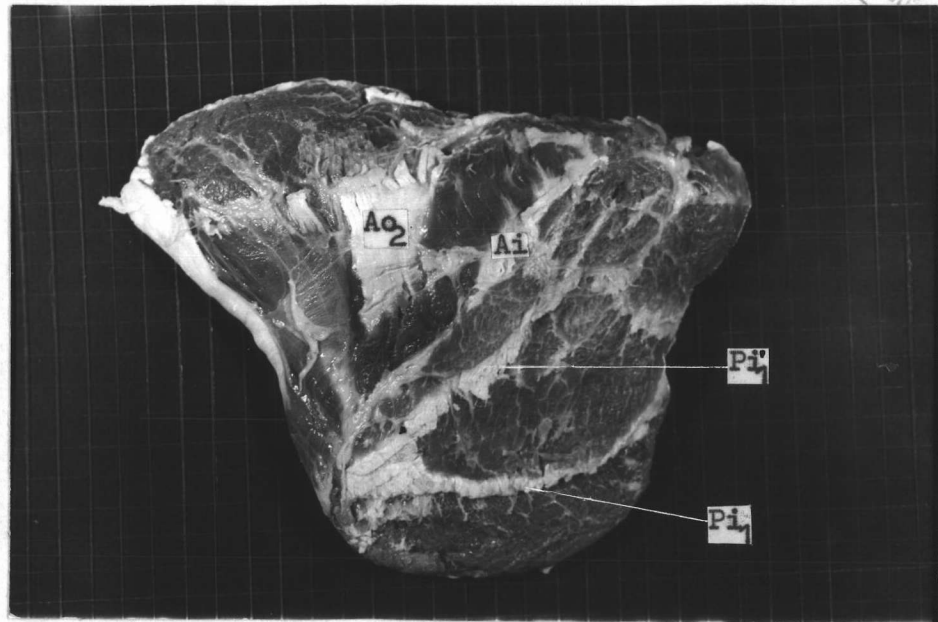
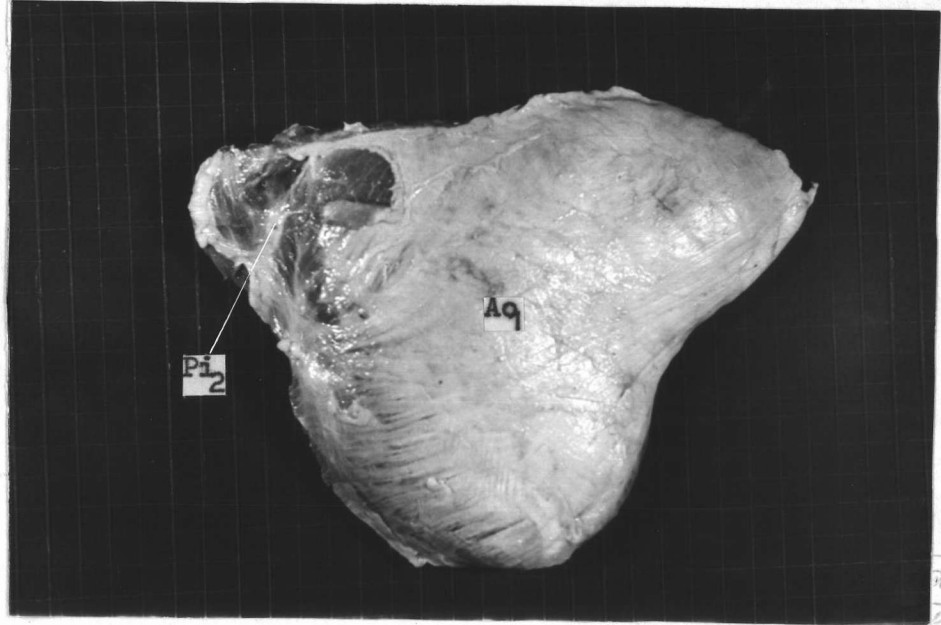
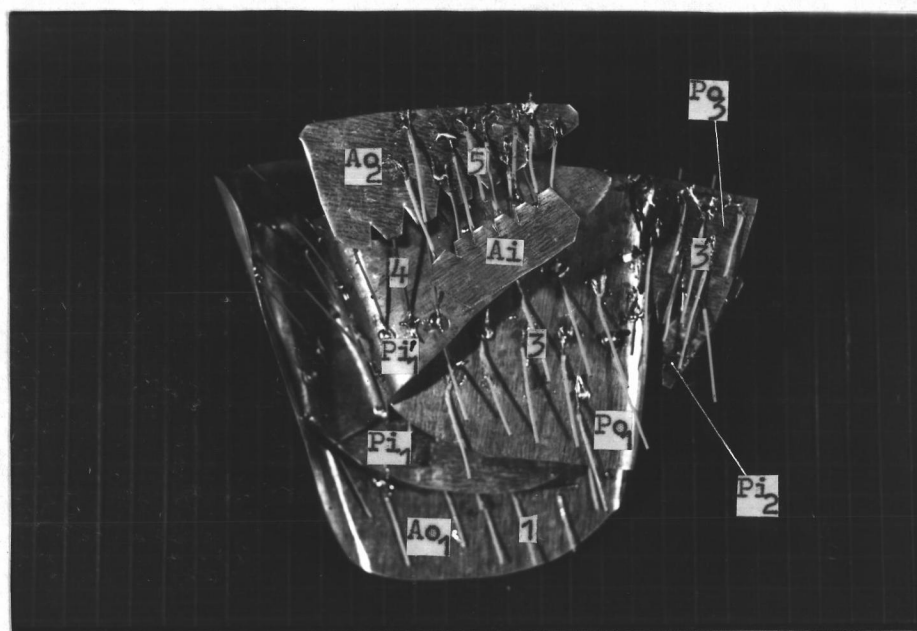



Fig. 41 The lateral aspect of the model of the masseter muscle of ox. Compare with Fig. 39. Wires indicate directions of muscle fibers. Ao_1 , aponeurosis of origin; Po_2 , primary lamina of origin; Po_3 , primary lamina of origin of the posterior part; Pi_2 , primary lamina of insertion of the posterior part. $1'$, the first layer of muscle fibers of the posterior part.

Fig. 42 The medial aspect of the model of the masseter muscle of ox. Compare with Fig. 40. Wires indicate directions of muscle fibers. Ao_1 and Ao_2 , aponeuroses of origin; Po_1 , primary lamina of origin; Po_3 , primary lamina of origin of the posterior part. Ai , aponeurosis of insertion; Pi_2 , primary lamina of insertion of the posterior part. 1, 3, 4, and 5 are the first, third, fourth, and fifth layers of muscle fibers. $3'$, the third layer of muscle fibers of the posterior part. Note that, the second layer of muscle fibers of the anterior and posterior parts are not visible.



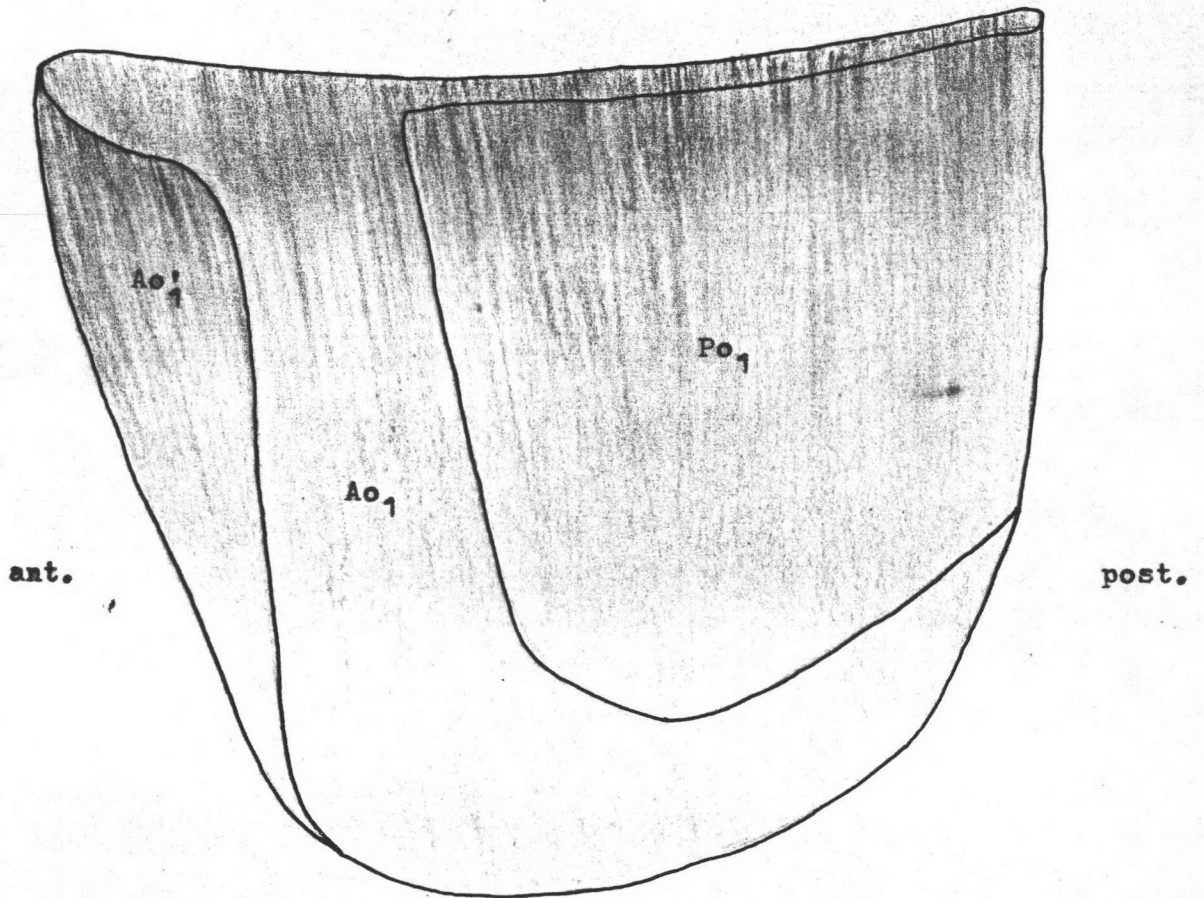


Fig. 43 The diagram of the medial surface of the aponeurosis of origin, Ao_1 , of the masseter muscle of ex, showing the reflected part, Ao'_1 , of the aponeurosis of origin and the primary lamina of origin, Po_1 .

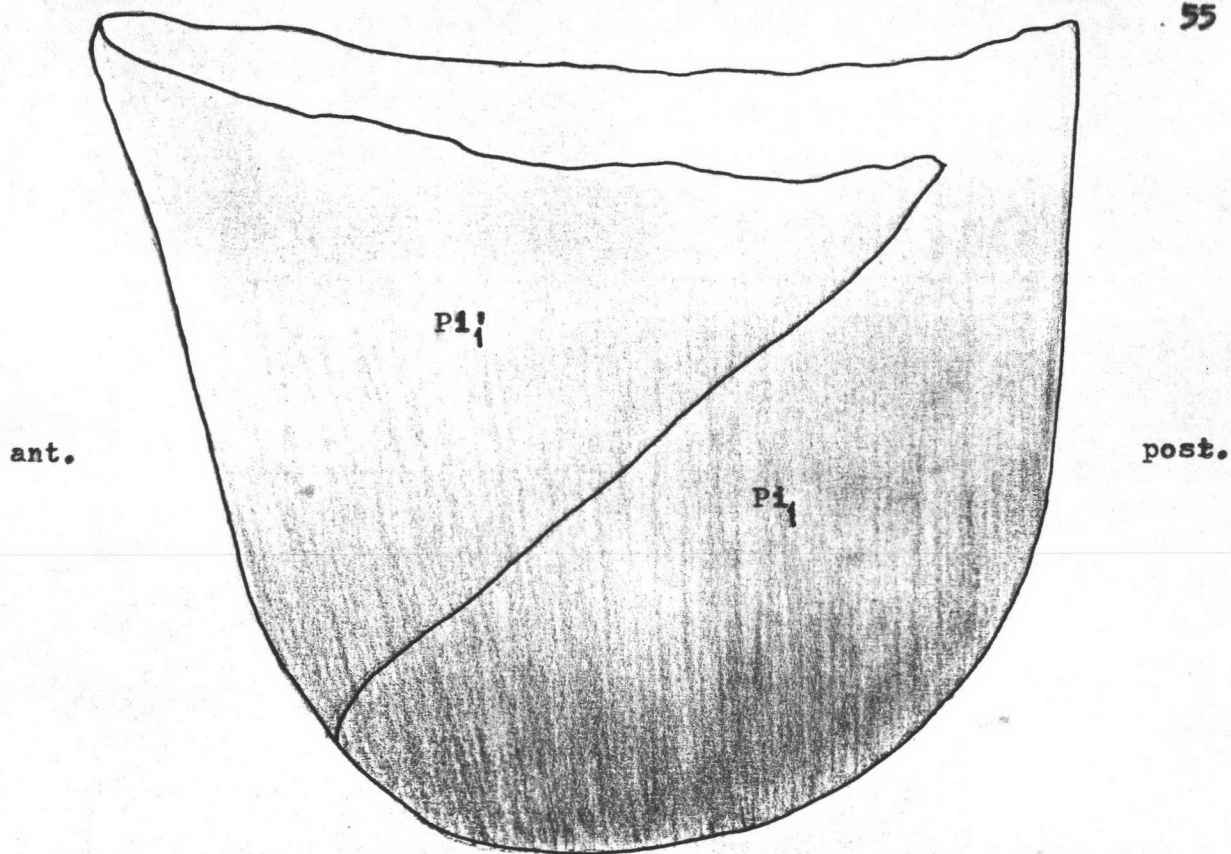


Fig. 44 The diagram of the medial surface of the primary lamina of insertion, Pi_1 , of the masseter muscle of ox, showing the reflected part, Pi_1' , of the primary lamina of insertion.

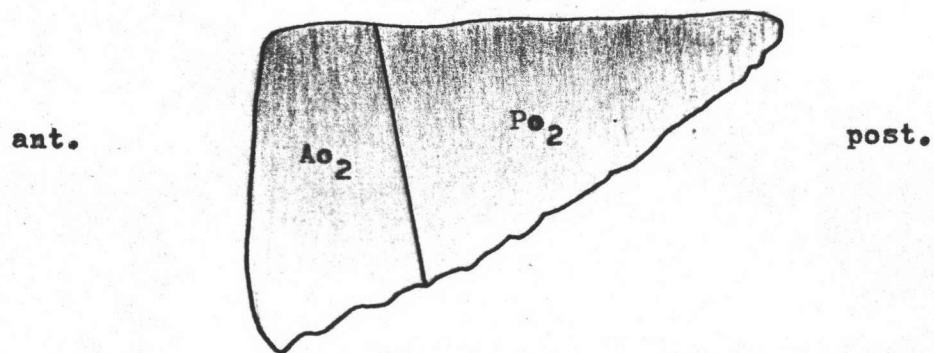


Fig. 45 The diagram of the medial surface of the aponeurosis of origin, Ao_2 , and the primary lamina of origin, Po_2 , of the masseter muscle of ox.

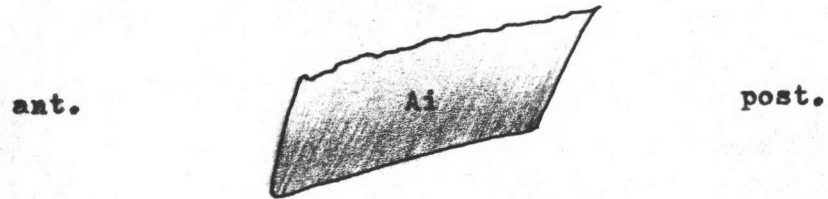


Fig. 46 The diagram of the medial surface of the aponeurosis of insertion, Ai, of the masseter muscle of ox.

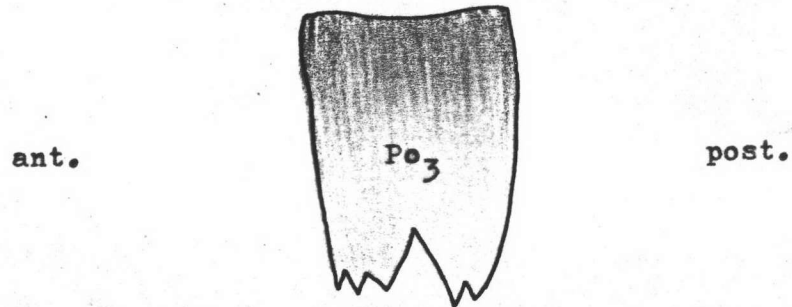


Fig. 47 The diagram of the medial surface of the primary lamina of origin, Po₃, of the masseter muscle of ox.

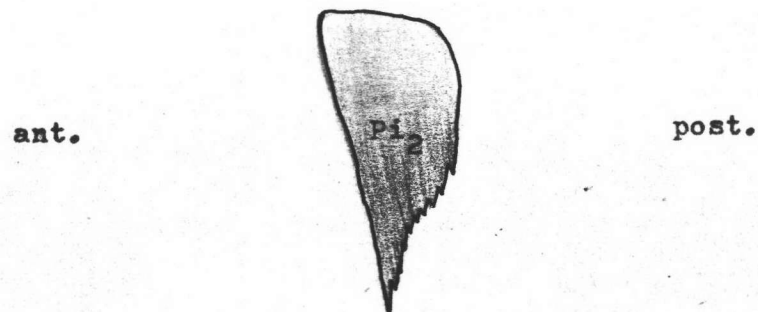


Fig. 48 The diagram of the medial surface of the primary lamina of insertion, Pi₂, of the masseter muscle of ox.

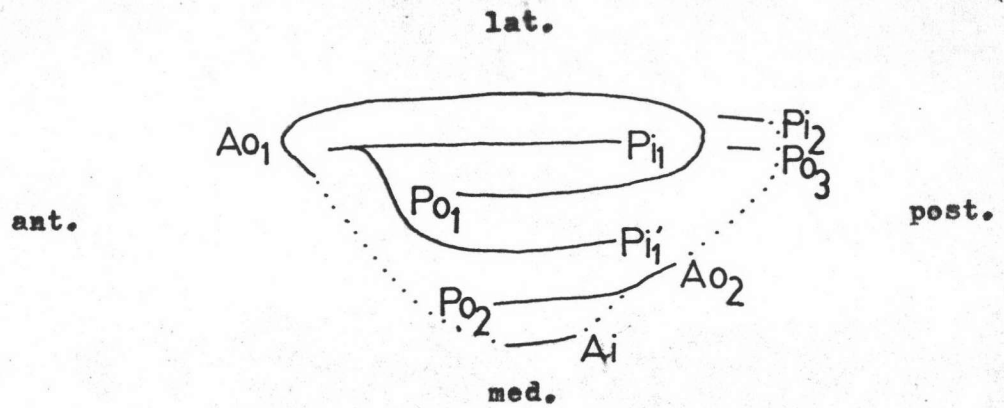


Fig. 49 The diagram of the horizontal section of the masseter muscle of ox. Dotted line indicates the medial surface of the muscle. Ao₁ and Ao₂, aponeuroses of origin; Po₁, Po₂, and Po₃, primary laminae of origin; Ai, aponeurosis of insertion; Pi₁, Pi₁', and Pi₂, primary laminae of insertion.

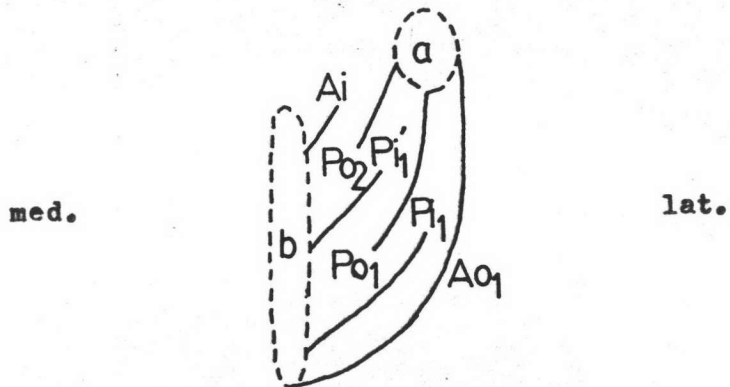


Fig. 50 The diagram of the vertical section of the masseter muscle of ox. a, the zygomatic arch; b, the mandible. Ao₁ and Ao₂, aponeuroses of origin; Po₁ and Po₂, primary laminae of origin; Ai, aponeurosis of insertion; Pi₁ and Pi₁', primary laminae of insertion.

of the aponeurosis of origin, Ao_1 . At its anterior border, it reflects to the medial surface as a triangular reflected part, Pi'_1 , of the primary lamina of insertion. This reflected part of the primary lamina of insertion lies between the primary laminae of origin, Po_1 and Po_2 (Figs. 49 and 50).

On the other hand, the primary lamina of insertion, Pi_2 (Fig. 47), is in the posterior part of the muscle. It is triangular in shape. It arises from the lateral surface of the ramus and lies laterally to the primary lamina of origin, Po_3 .

The Arrangement of the Muscle Fibers (Figs. 41 and 42)

As mentioned earlier, the muscle is divided into two parts according to the arrangement of the fibers, the anterior and posterior parts. The fibers of the anterior part is oblique while those of posterior part is vertical.

The anterior part is larger and can be further subdivided into five layers. From lateral to medial, the fibers of the first layer originate from the medial surface of the aponeurosis of origin, Ao_1 . They run downwards and insert on the lateral surface of the primary lamina of insertion, Pi_1 . In the second layer, the fibers which arise from the lateral surface of the primary lamina of origin, Po_1 , pass downwards to insert on the medial surface of the primary lamina of insertion, Pi_1 . The muscle fibers of the third layer originate from the medial surface of the primary lamina of origin, Po_1 . They pass downwards to insert on the lateral surface of the reflected part, Pi'_1 , of the primary lamina of insertion,

anteriorly; and the lateral surface of the ramus, posteriorly. The fourth and the fifth layers are situated at the upper portion of the anterior part of the muscle. In the fourth layer, the fibers which arise from the lateral surface of the aponeurosis of origin, Ao_2 and the primary lamina of origin, Po_2 , pass downwards to terminate at the medial surface of the reflected part, Pi_1 , of the primary lamina of insertion. The muscle fibers of the fifth layer originate from the medial surface of the primary lamina of origin, Po_2 . They terminate at the lateral surface of the aponeurosis of insertion, Ai , and the upper part of the lateral surface of the ramus of mandible.

The posterior part of the muscle is smaller. It is situated at the postero-dorsal part of the muscle. This part is further subdivided into three layers. From lateral to medial, the fibers of the first layer arise from the posterior part of the zygomatic arch. They pass vertically downwards to insert on the upper part of the lateral surface of the primary lamina of insertion, Pi_2 . In the second layer, the fibers which originate from the lateral surface of the primary lamina of origin, Po_3 , run vertically downwards to terminate at the medial surface of the primary lamina of insertion, Pi_2 . The fibers of the third layer arise from the medial surface of the primary lamina of origin, Po_3 . They pass vertically downwards to insert on the upper part of the lateral surface of the ramus of mandible.

Medial Pterygoid Muscle of Ox

General Description

The medial pterygoid muscle of ox (Figs. 51 and 52) is situated on the medial surface of the vertical part of the ramus of mandible. This muscle resembles the masseter muscle in form, but is smaller. It arises from the pterygoid process of the sphenoid and the lateral face of the perpendicular part of the palatine bone. It inserts on the medial surface and the posterior border of the vertical ramus of the mandible.

Internal Tendons of Origin

Formulae: Ao_1 , Ao_2 , Po , So

The muscle is composed of two aponeuroses of origin, Ao_1 and Ao_2 . The aponeurosis of origin, Ao_1 (Fig. 55), is a small and quadrilateral shaped aponeurosis. It arises from the lateral surface of the perpendicular part of the palatine bone. This aponeurosis, Ao_1 , is situated at the dorso-lateral surface of the muscle (Fig. 52).

The aponeurosis of origin, Ao_2 (Fig. 56), is a strong and quadrangular in shape. It arises from the pterygoid process and extends downwards to cover the medial surface of the muscle. At the antero-dorsal margin of the aponeurosis of origin, Ao_2 , arises a primary lamina of origin, Po . It is rectangular in shape and originates as the reflected part of the aponeurosis of origin, Ao_2 . The secondary lamina of origin, So (Fig. 56) is also rectangular in shape and arises from the middle of the primary lamina

of origin, Po. It extends laterally parallel to the primary lamina of origin, Po.

Internal Tendons of Insertion

Formulae: Ai, Pi₁, Pi₂

The aponeurosis of insertion, Ai (Fig. 58), is quadrilateral. It arises from the medial side of the ramus. It extends upwards and covers almost the lateral surface of the muscle.

This muscle has two primary laminae of insertion, Pi₁ and Pi₂. The primary lamina of insertion, Pi₁ (Fig. 57), has a trapezoid shape with a curved ventral margin. It arises from the medial surface of the mandible. This primary lamina of insertion, Pi₁, locates between the primary lamina of origin, Po and the secondary lamina of origin, So (Fig. 59).

The primary lamina of insertion, Pi₂ (Fig. 58), shaped like a rectangle whose ventral margin is curved and runs parallel to the ventral margin of the aponeurosis of origin, Ao₂. It arises from the medial surface of the mandible and lies between the aponeurosis of origin, Ao₂ and the primary lamina of origin, Po. The anterior border of the primary lamina of insertion, Pi₂, connects to the antero-ventral border of the aponeurosis of insertion, Ai.

The Arrangement of the Muscle Fibers (Figs. 53 and 54)

The muscle is composed of four layers of muscle fibers. From medial to lateral, the fibers of the first layer arise from the lateral surface of the aponeurosis of origin, Ao₂, run downwards

Fig. 51 The medial surface of the isolated medial pterygoid muscle of ox. Ao_2 , aponeurosis of origin.

Fig. 52 The lateral surface of the isolated medial pterygoid muscle of ox. Ao_1 , aponeurosis of origin; Ai , aponeurosis of insertion; Pi_2 , primary lamina of insertion connected to the aponeurosis of insertion, Ai .

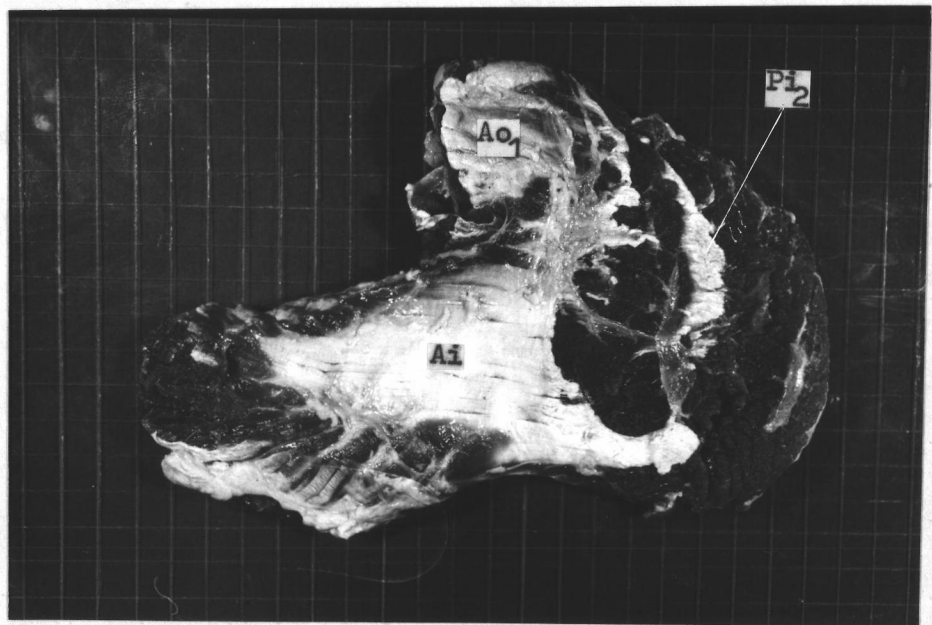
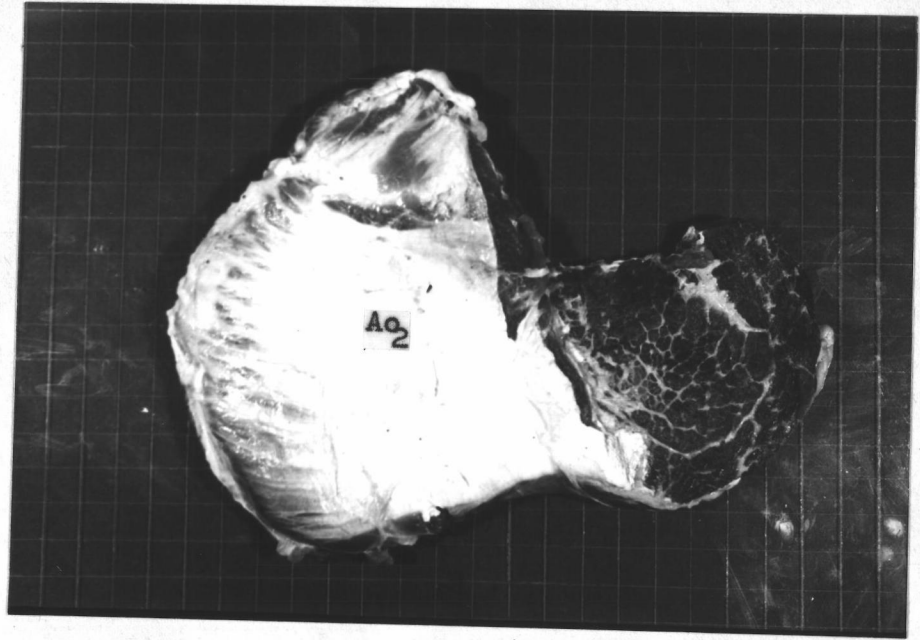
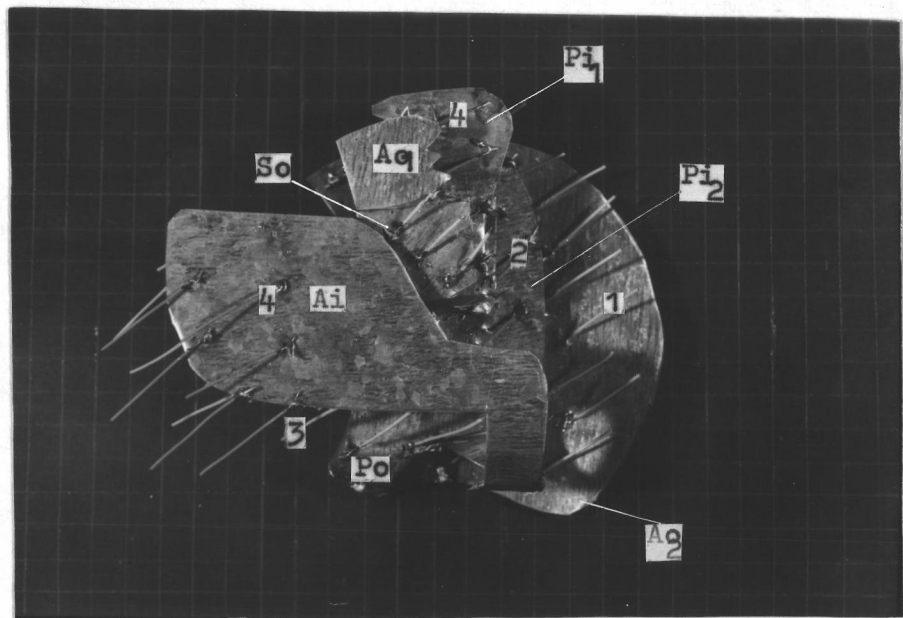
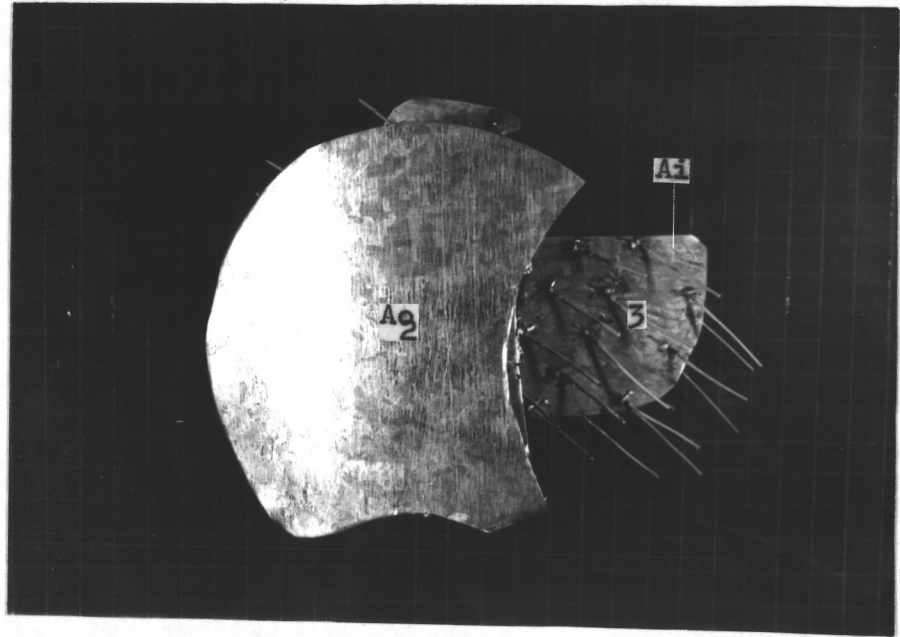


Fig. 53 The medial aspect of the model of the medial pterygoid muscle of ox. Compare with Fig. 51. Wires indicate directions of muscle fibers. Ao_2 , aponeurosis of origin; Ai , aponeurosis of insertion. 3, the third layer of muscle fibers.

Fig. 54 The lateral aspect of the model of the medial pterygoid muscle of ox. Compare with Fig. 52. Wires indicate directions of muscle fibers. Ao_1 and Ao_2 , aponeuroses of origin; Ai , aponeurosis of insertion. Po , primary lamina of origin connected to the aponeurosis of origin, Ao_2 ; So , secondary lamina of origin arised from the primary lamina of origin, Po ; Pi_1 and Pi_2 , primary laminae of insertion. 1, 2, and 3 are the first, second, and third layers of muscle fibers.



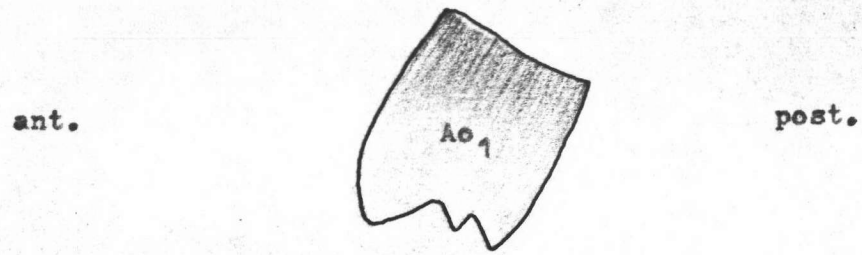


Fig. 55 The diagram of the lateral surface of the aponeurosis of origin, Ao_1 , of the medial pterygoid muscle of ox.

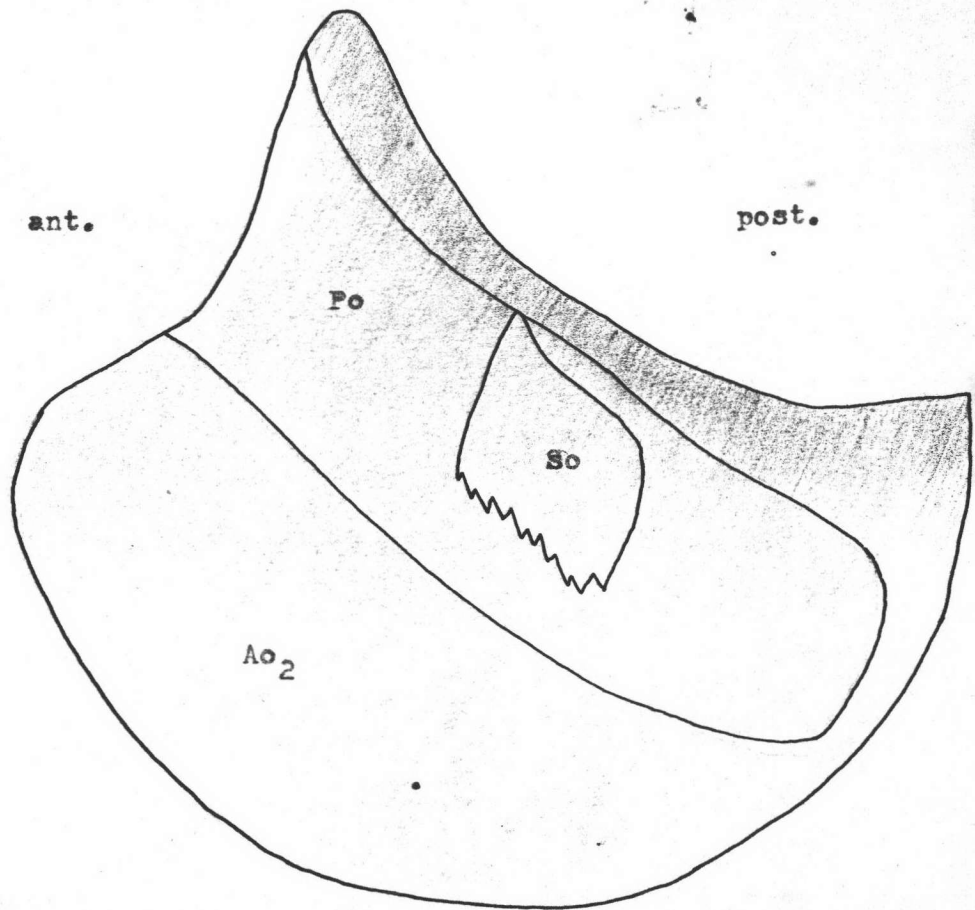


Fig. 56 The diagram of the lateral surface of the aponeurosis of origin, Ao_2 , of the medial pterygoid muscle of ox, showing the primary lamina of origin, Po , and the secondary lamina of origin, So .

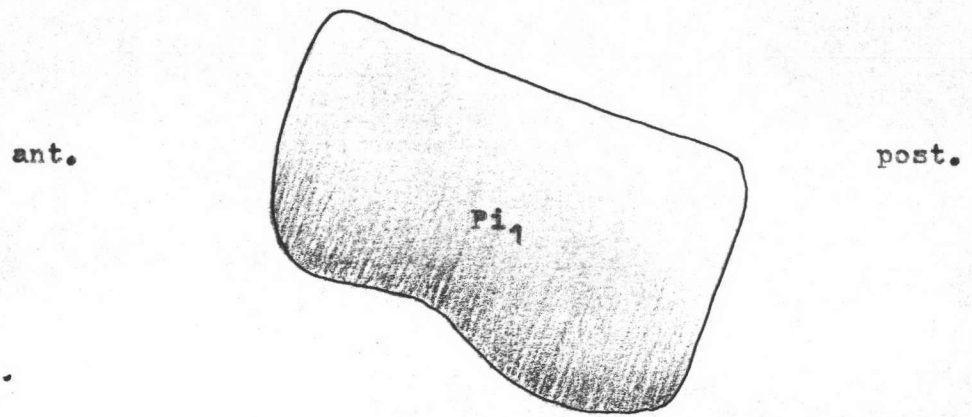


Fig. 57 The diagram of the lateral surface of the primary lamina of insertion, Pi_1 , of the medial pterygoid muscle of ox.

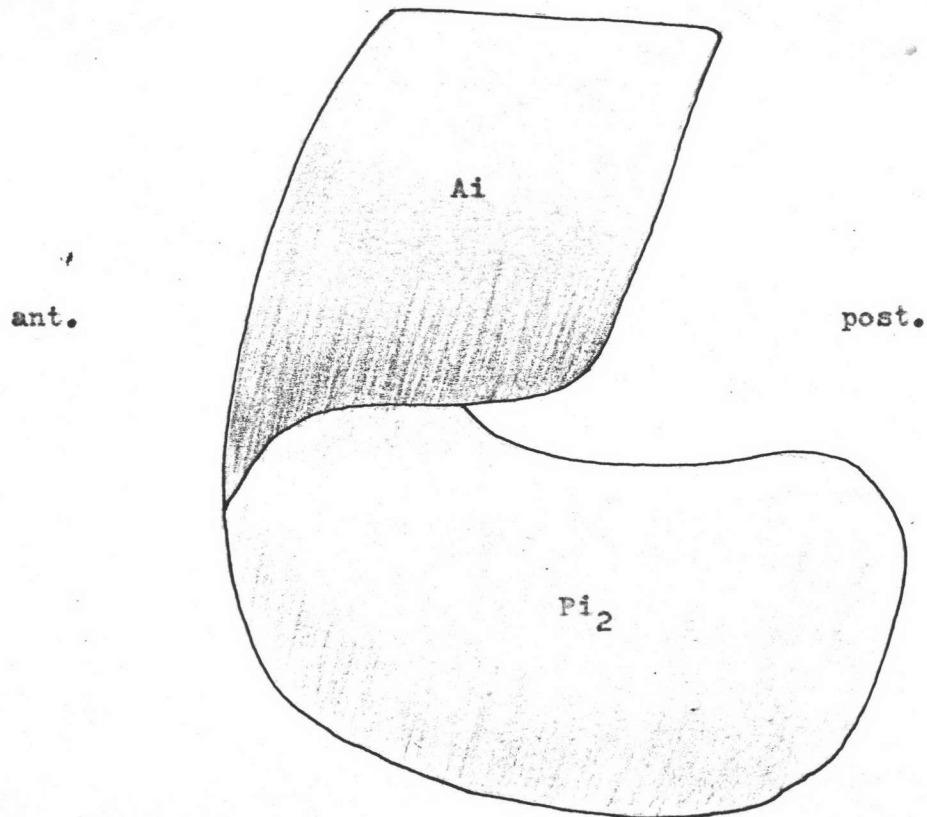


Fig. 58 The diagram of the lateral surface of the aponeurosis of insertion, Ai , of the medial pterygoid muscle of ox, showing the primary lamina of insertion, Pi_2 .

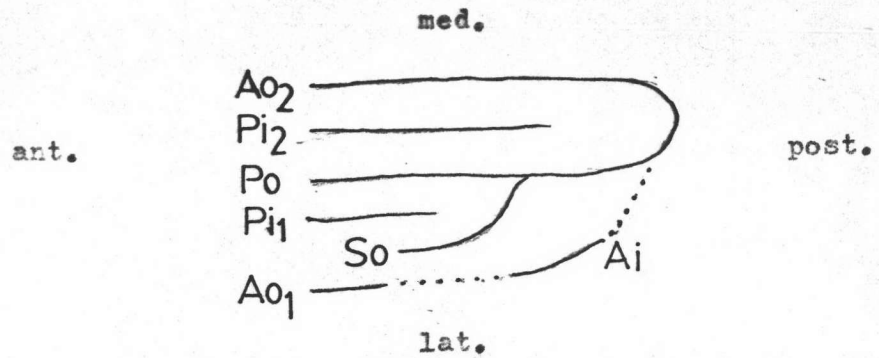


Fig. 59 The diagram of the horizontal section of the medial pterygoid muscle of ox, dotted line indicates the lateral surface of the muscle. Ao_1 and Ao_2 , aponeuroses of origin; Po , primary lamina of origin; So , secondary lamina of origin; Ai , aponeurosis of insertion; Pi_1 and Pi_2 , primary laminae of insertion.

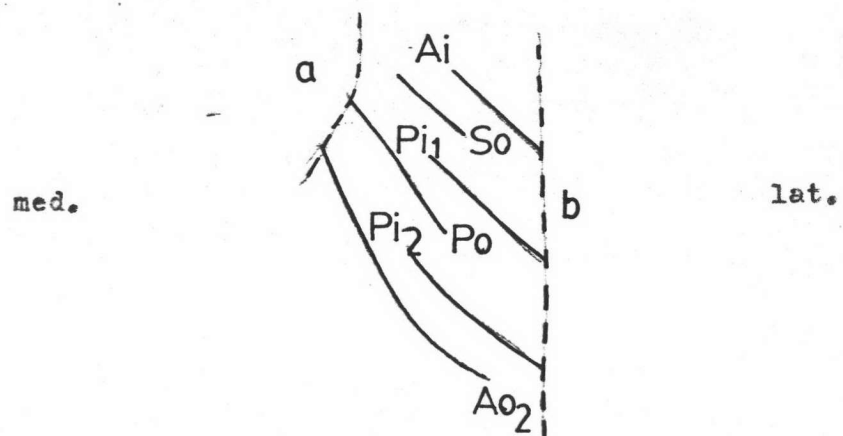


Fig. 60 The diagram of the vertical section of the medial pterygoid muscle of ox. a, the pterygoid process of sphenoid; b, the mandible. Ao_1 , aponeurosis of origin; Po , primary lamina of origin; So , secondary lamina of origin; Ai , aponeurosis of insertion; Pi_1 and Pi_2 , primary laminae of insertion.

and insert on the medial surface of the primary lamina of insertion, Pi_2 , and the lower border of the medial surface of the mandible. The muscle fibers of the second layer originate from the medial surface of the primary lamina of origin, Po . They extend downwards to insert on the lateral surface of the primary lamina of insertion, Pi_2 . The muscle fibers of the third layer are divided into two parts; the anterior and posterior parts. The fibers of the anterior part arise from the lateral surface of the perpendicular part of the palatine bone and the anterior half of the lateral surface of the primary lamina of origin, Po . They run downwards to insert on the medial surface of the aponeurosis of insertion, Ai . The posterior fibers which originate from the posterior half of the lateral surface of the primary lamina of origin, Po , pass downwards to the medial surface of the primary lamina of insertion, Pi_1 . The muscle fibers of the fourth layer are also divided into two parts. The anterior fibers arise from the pterygoid crest. They run downwards to insert on the upper border of the lateral surface of the aponeurosis of insertion, Ai . The posterior fibers arise from the medial surface of the secondary lamina of origin, So , and the aponeurosis of origin, Ao_1 . They pass downwards to insert on the lateral surface of the primary lamina of insertion, Pi_1 .

Lateral Pterygoid Muscle of Ox

General Description

The lateral pterygoid muscle (Figs. 61 and 62) is a short, flat, triangular muscle. It is situated in front of the

temporomaxillary articulation. This muscle arises from the pterygoid process and the postero-lateral surface of the perpendicular part of the palatine bone and extends to the floor of the pterygo-palatine fossa. It inserts on the medial side of the neck of the dorsal extremity of the ramus and the medial extremity of the temporal condyle of the mandible.

Internal Tendons of Origin

Formulae: Ao, Po

The curved trapezoidal aponeurosis of origin, Ao (Fig. 65) covers the lower part of the medial side of the muscle. This aponeurosis of origin arises from the pterygoid process of the palatine bone and terminates at the anterior half of its ventral border as the long quadrilateral primary lamina of origin, Po (Fig. 65). This primary lamina of origin, Po curves upwards and laterally to the aponeurosis of origin, Ao.

Internal Tendons of Insertion

Formulae: Ai₁, Ai₂, Pi

This muscle is composed of two aponeuroses of insertion, Ai₁ and Ai₂. The triangular shaped aponeurosis of insertion, Ai₁ (Fig. 66), covers the lateral surface of the muscle. It arises from the medial extremity of the temporal condyle of the mandible, which extends upwards and anteriorly. The aponeurosis of insertion, Ai₂ (Fig. 66), arises at the posterior half of the dorsal margin of the aponeurosis of insertion, Ai₁. It reflects as a small quadrangular shape and medial to the aponeurosis of insertion, Ai₁.

Fig. 61 The lateral surface of the isolated lateral pterygoid muscle of ox. Ao, aponeurosis of origin with its extension, the primary lamina of origin, Po; Ai₁, aponeurosis of insertion.

Fig. 62 The medial surface of the isolated lateral pterygoid muscle of ox. Ao, aponeurosis of origin; Ai₂, aponeurosis of insertion.

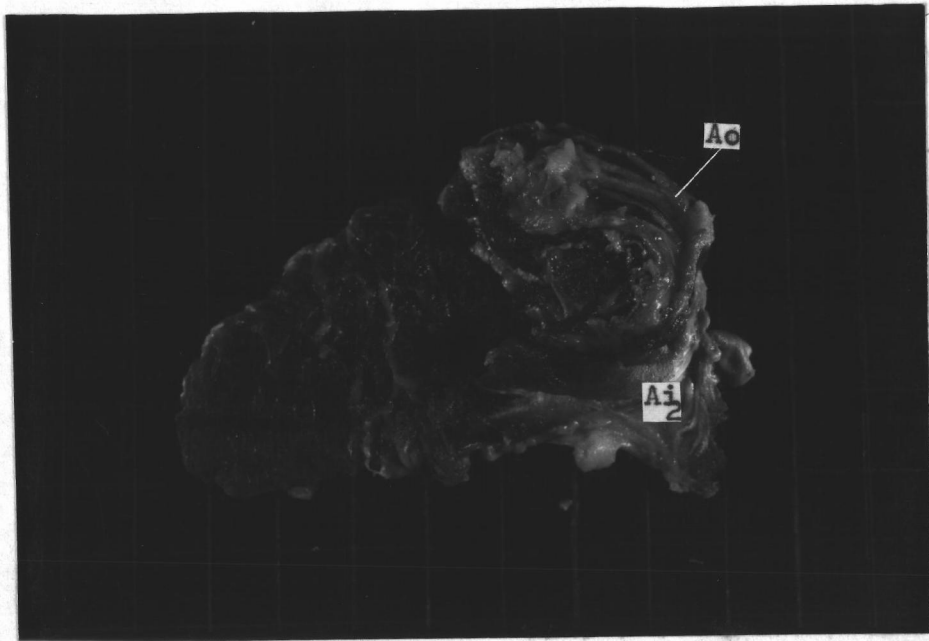
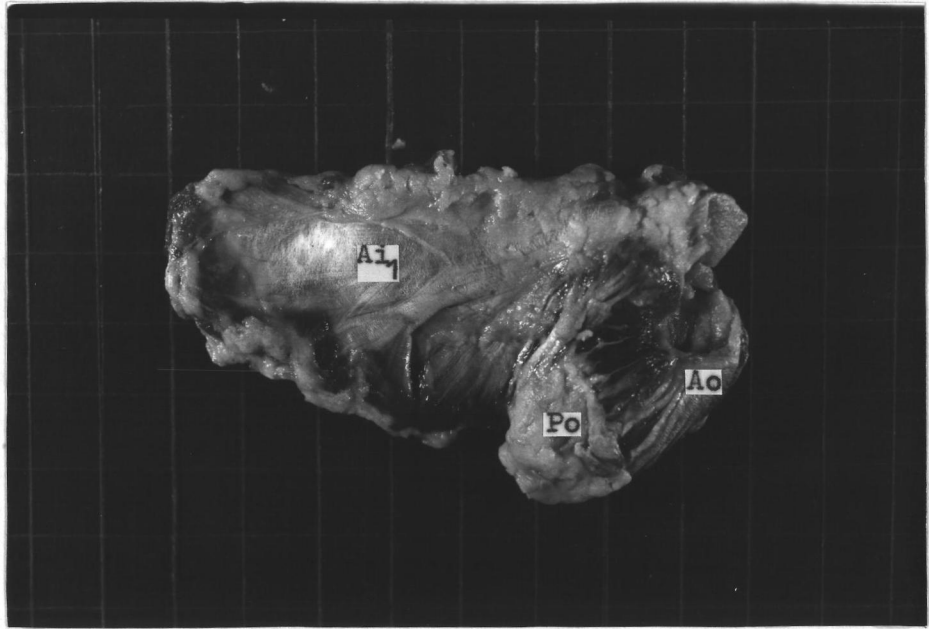




Fig. 63 The lateral aspect of the model of the lateral ptery-
gold muscle of ox. Compare with Fig. 61. Wires indi-
cate directions of muscle fibers. Ao, aponeurosis of
origin; Po, primary lamina of origin; Al¹, aponeurosis
of insertion.

Fig. 64 The medial aspect of the model of the lateral ptery-
gold muscle of ox. Compare with Fig. 62. Wires
indicate directions of muscle fibers. Ao, aponeurosis
of origin; Al¹ and Al², aponeuroses of insertion; Pl,
primary lamina of insertion.



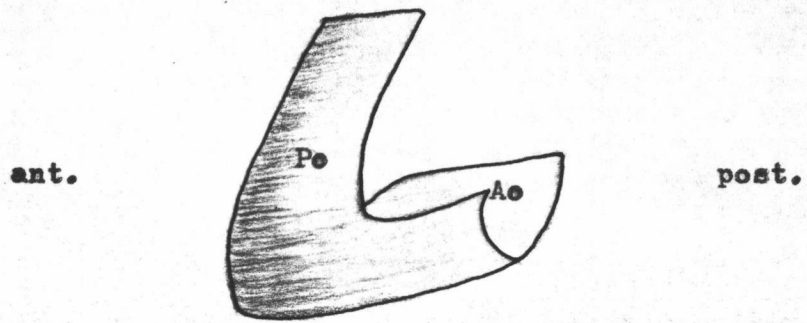


Fig. 65 The diagram of the lateral surface of the aponeurosis of origin, Ao, of the lateral pterygoid muscle of ox, showing the primary lamina of origin, Po.

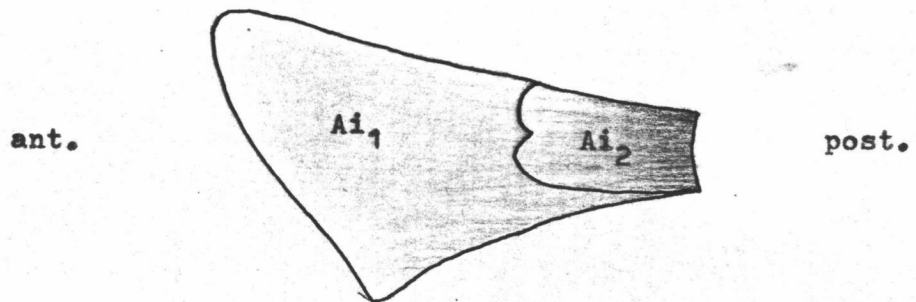


Fig. 66 The diagram of the medial surface of the aponeurosis of insertion, Ai₁, of the lateral pterygoid muscle of ox, and the aponeurosis of insertion, Ai₂.

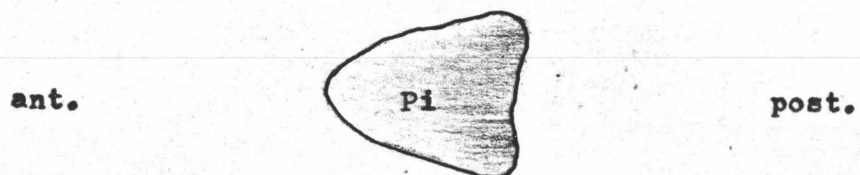


Fig. 67 The diagram of the medial surface of the primary lamina of insertion, Pi, of the lateral pterygoid muscle of ox.

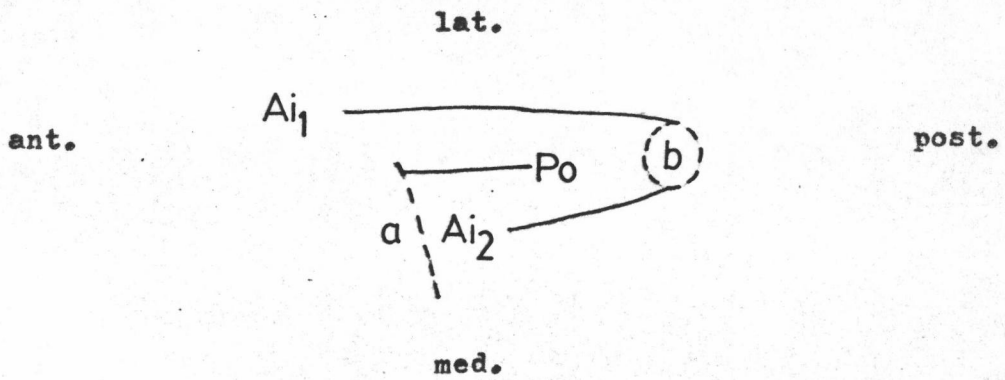


Fig. 68 The diagram of the horizontal section of the lateral pterygoid muscle of ox. . . a, the pterygoid process; b, the temporal condyle of mandible. Ai₁ and Ai₂, aponeuroses of insertion, Po, primary lamina of origin.

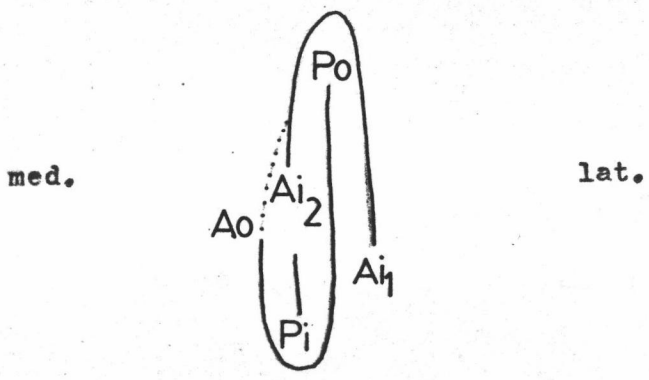


Fig. 69 The diagram of the vertical section of the lateral pterygoid muscle of ox. . . Dotted line indicates the medial surface of the muscle. Ao, aponeurosis of origin; Po, primary lamina of origin; Ai₁ and Ai₂, aponeuroses of insertion; Pi, primary lamina of insertion.

The primary lamina of insertion, Pi (Fig. 67), is small triangular in shape. It arises from the neck of the dorsal extremity of the ramus of mandible. It is situated inferiorly to the aponeurosis of insertion, Ai₂, between the primary lamina of origin, Po, laterally and the aponeurosis of origin, Ao, medially.

The Arrangement of the Muscle fibers (Figs. 63 and 64)

This muscle consists of three layers of muscle fibers. From lateral to medial, the muscle fibers of the first layer are divided into two parts. The fibers of the anterior part arise from the postero-lateral surface of the perpendicular part of the palatine bone. They pass downwards and insert on the anterior part of the medial surface of the aponeurosis of insertion, Ai₁. The fibers of the posterior part originate along the lateral surface of the primary lamina of origin, Po, and insert on the posterior part of the medial surface of the aponeurosis of insertion, Ai₁. In the second layer, the muscle fibers arise from the medial surface of the primary lamina of origin, Po. They pass downwards and insert on the lateral surface of the aponeurosis of insertion, Ai₂, superiorly; and the lateral surface of the primary lamina of insertion, Pi, inferiorly. The third layer has two origins. The fibers of the upper origin originate from the pterygoid process of the palatine bone and adjacent areas. They terminate on the anterior half of the medial surface of the aponeurosis of insertion, Ai₂. The fibers of the lower origin which arise from the lateral surface of the aponeurosis of origin, Ao, pass downwards to insert on the medial surface of the primary lamina of insertion, Pi.

Temporalis Muscle of Man

General Description

The temporalis muscle of man (Figs. 70 and 71) is a large fan-shaped muscle which arises from the floor of the temporal fossa and from the temporal fascia. This muscle covers the upper part of the lateral aspect of the head. It inserts on the anterior margin of the coronoid process and the anterior margin of the ramus of mandible.

Internal Tendons of Origin

Formula : Ao

The aponeurosis of origin, Ao (Fig. 74), is thin and fan-shaped. It is a continuation of the temporal fascia at the inferior temporal line, and extends to insert on the superior margin of the zygomatic arch.

Internal Tendons of Insertion

Formula: Pi

There is no aponeurosis of insertion. The trapezoidal primary lamina of insertion, Pi (fig. 75), is thick inferiorly and thin superiorly. It arises from the coronoid process of mandible.

The Arrangement of the Muscle Fibers (Figs. 72 and 73)

The muscle fibers which arise from the deep surface of the aponeurosis of origin, Ao, pass downwards and converge to insert on the lateral surface of the primary lamina of insertion, Pi. The deep muscle fibers which arise from the floor of the temporal

Fig. 70 The lateral surface of the isolated temporalis muscle of man. Ao, aponeurosis of origin; Pi, primary lamina of insertion.

Fig. 71 The medial surface of the isolated temporalis muscle of man. The muscle fibers can only be seen.

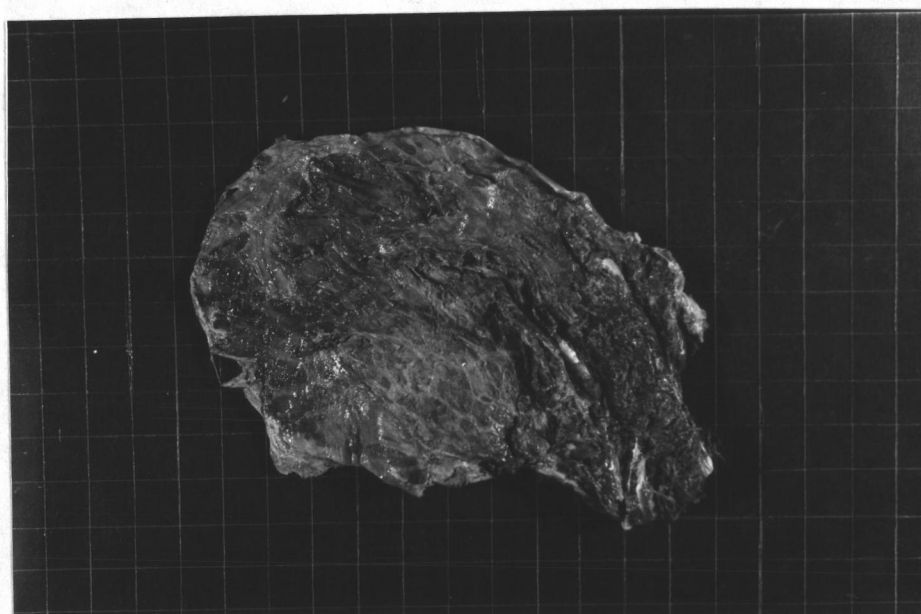





Fig. 72 The lateral aspect of the model of the temporalis muscle of man. Compare with Fig. 70. Wires indicate directions of muscle fibers. Ao, aponeurosis of origin; Pi, primary lamina of insertion. 1, the first layer of muscle fibers.

Fig. 73 The medial surface of the model of the temporalis muscle of man. Compare with Fig. 71. Wires indicate directions of muscle fibers. Ao, aponeurosis of origin; Pi, primary lamina of insertion. 1 and 2 are the first and second layers of muscle fibers.






Fig. 74 The diagram of the lateral surface of the aponeurosis of origin, Ao, of the temporalis muscle of man.

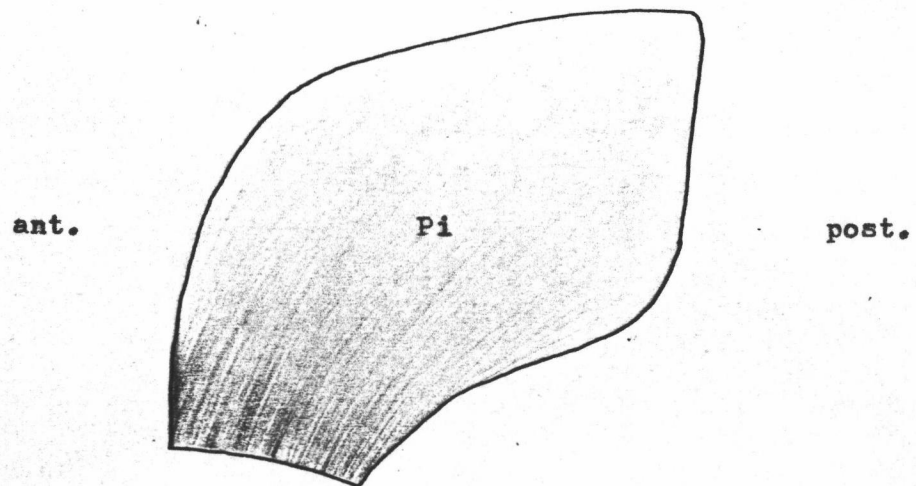
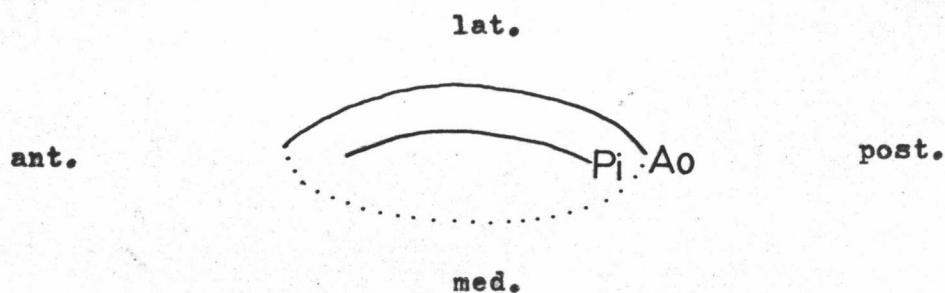
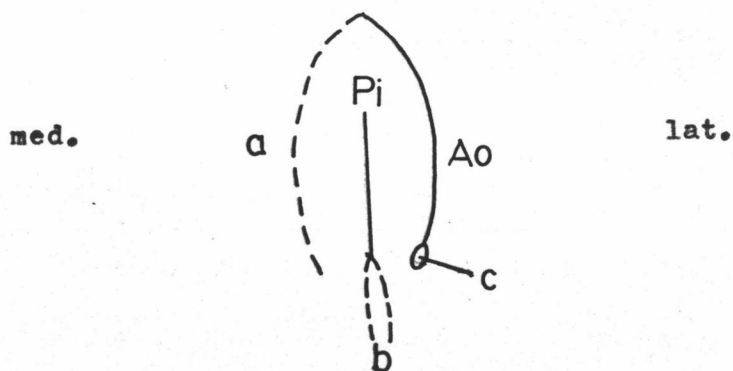


Fig. 75 The diagram of the lateral surface of the primary lamina of insertion, Pi, of the temporalis muscle of man.



76 Fig. 76 The diagram of the horizontal section of the temporalis muscle of man, dotted line indicates the medial surface of the muscle. Ao, aponeurosis of origin; Pi, primary lamina of insertion.



77 Fig. 77 The diagram of the vertical section of the temporalis muscle of man. a, the temporal fossa; b, the coronoid process of mandible; c, the zygomatic arch. Ao, aponeurosis of origin; Pi, primary lamina of insertion.

fossa, extend downwards and converge to the medial surface of the primary lamina of insertion, Pi. The arrangements of the muscle fibers can be divided into three groups. The fibers of the anterior group are almost vertical, the fibers of the middle group are obliquely arranged, and the fibers of the posterior group are nearly horizontal.

Masseter Muscle of Man

General Description

The masseter muscle of man (Figs. 78 and 79) is a thick, quadrangular muscle which covers the lateral aspect of the ramus and the coronoid process of the mandible. It arises from the inferior and medial margin of the zygomatic arch. This muscle inserts on the lateral surface of the ramus of mandible.

Internal Tendons of Origin

Formulae: Ao, Po₁, Po₂

The aponeurosis of origin, Ao (Fig. 82), is thick and strong and quadrilateral in shape. It arises from the inferior margin of the zygomatic arch. It covers the upper part of the lateral aspect of the muscle.

This muscle has two primary laminae of origin, Po₁ and Po₂. The primary lamina of origin, Po₁ (Fig. 82), is quadrilateral. It arises from the deep surface of the zygomatic arch, parallel to the aponeurosis of origin, Ao. The anterior and posterior margin of this primary lamina of origin, Po₁, are connected to the anterior

and posterior margin of the aponeurosis of origin, Ao. Thus, the primary lamina of origin, Po₁, and the aponeurosis of origin, Ao form the boundaries of a narrow oval pouch.

The triangular shaped primary lamina of origin, Po₂ (Fig. 83), arises from the posterior and medial sides of the zygomatic arch. It lies posteriorly to the primary lamina of origin, Po₁.

Internal Tendons of Insertion

Formulae: Ai₁, Ai₂, Pi₁, Pi₂, Pi₃, Pi₄, Pi₅

Both of the two aponeuroses of insertion, Ai₁ and Ai₂ arise from the lateral surface of the mandible and continue with each other as the broad aponeurosis of insertion (Fig. 84). The aponeurosis of insertion, Ai₁ is rather quadrilateral with a curved lower border. The aponeurosis of insertion, Ai₂, is quadrangular and extends posteriorly.

This muscle consists of five primary laminae of insertion. The four primary laminae Pi₁, Pi₂, Pi₃, and Pi₄ (Fig. 84) arise from the termination of the aponeurosis of insertion, Ai₁. The fifth primary lamina of insertion, Pi₅ (Fig. 85), is isolated from the other laminae and lies postero-laterally to the aponeurosis of insertion, Ai₂.

The Arrangement of the Muscle Fibers (Figs. 80 and 81)

This muscle is composed of three layers of muscle fibers. The muscle fibers of the superficial layer which arise from the medial surface of the aponeurosis of origin, Ao, pass downwards to the lateral surface of the primary laminae of insertion, Pi₁, Pi₂,

Fig. 78 The lateral surface of the isolated masseter muscle of man. Ao, aponeurosis of origin.

Fig. 79 The medial surface of the isolated masseter muscle of man. Ai₁ and Ai₂, aponeuroses of insertion; Po₁ and Po₂, primary laminae of origin.

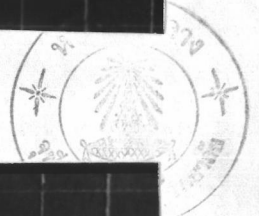
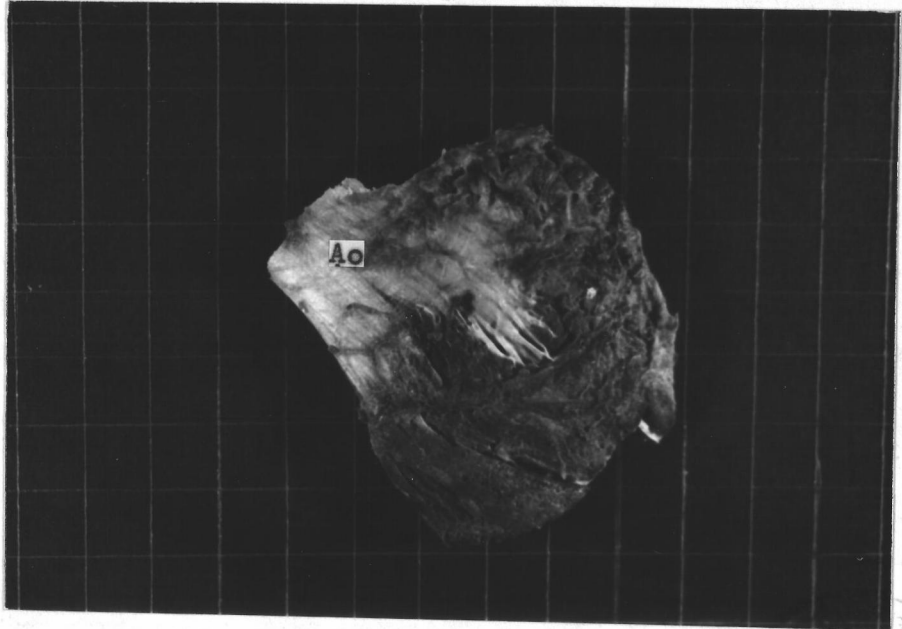

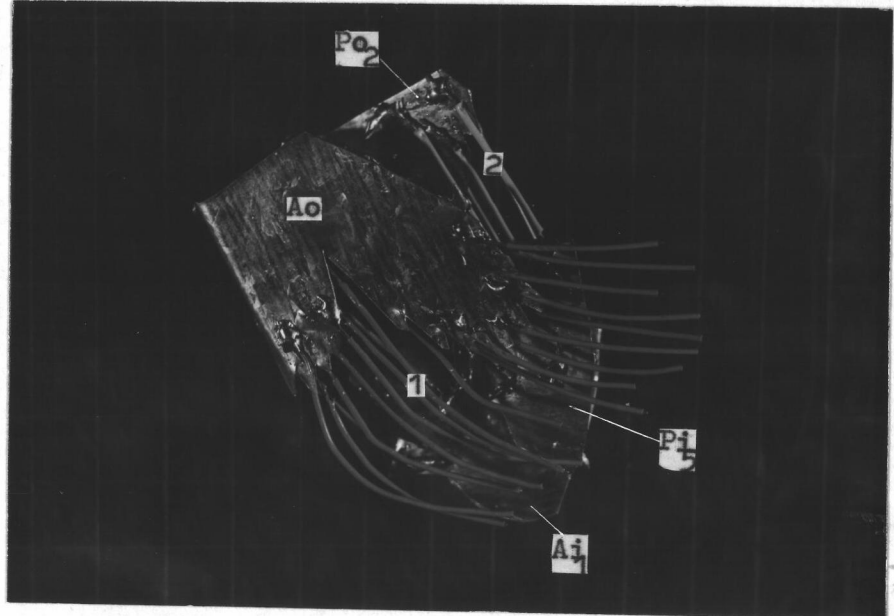
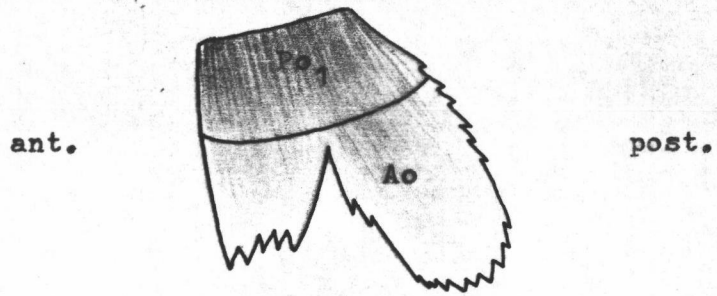


Fig. 80 The lateral aspect of the model of the masseter muscle of man. Compare with Fig. 78. Wires indicate directions of muscle fibers. Ao, aponeurosis of origin; Po₂, primary lamina of origin. Ai₁, aponeurosis of insertion; Pi₅, primary lamina of insertion. 1 and 2 are the first and second layers of muscle fibers.

Fig. 81 The medial aspect of the model of the masseter muscle of man. Compare with Fig. 79. Wires indicate directions of muscle fibers. Po₁ and Po₂, primary laminae of origin. Ai₁ and Ai₂, aponeuroses of insertion; Pi₁ and Pi₂, primary laminae of insertion arised from the aponeurosis, Ai₁. 3, the third layer of muscle fibers.

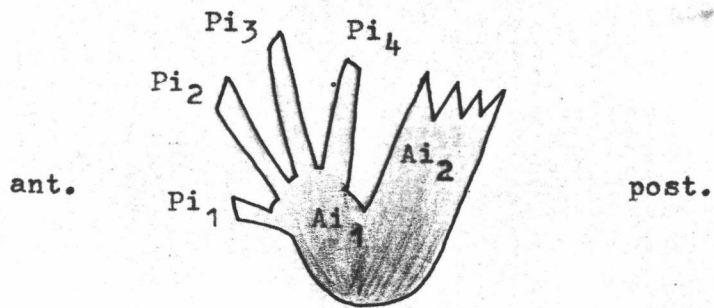




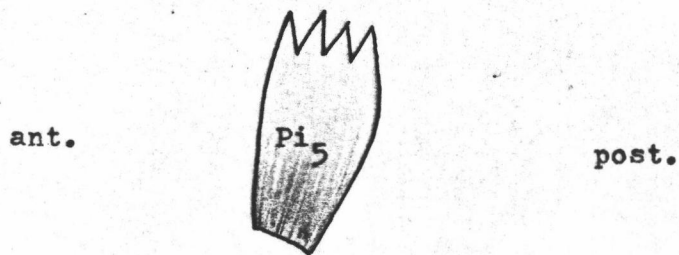
82 Fig. 82 The diagram of medial surface of aponeurosis of origin, Ao , of the masseter muscle of man, showing the primary lamina of origin, Po_1 .



83 Fig. 83 The diagram of the medial surface of the primary lamina of origin, Po_2 , of the masseter muscle of man.



84 Fig. 84 The diagram of the medial surface of the aponeuroses of insertion, Ai_1 and Ai_2 , of the masseter muscle of man, showing the primary laminae of insertion, Pi_1 , Pi_2 , Pi_3 , Pi_4 .



85 Fig. 85 The diagram of the medial surface of the primary lamina of insertion, Pi_5 , of the masseter muscle of man.

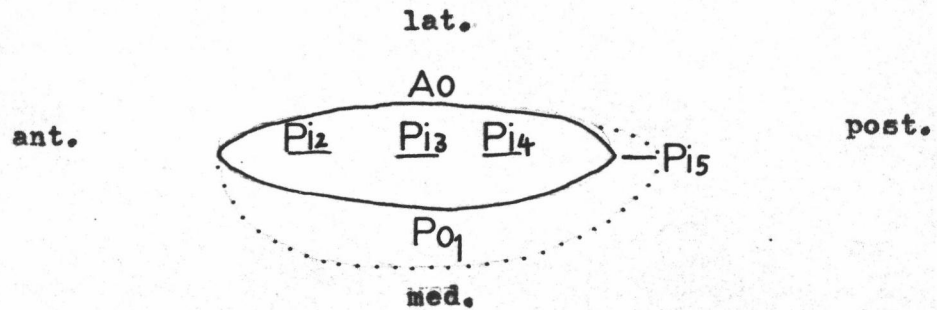


Fig. 86 The diagram of the horizontal section of the masseter muscle of man, dotted line indicates the border of the muscle. Ao, aponeurosis of origin; Po₁, primary lamina of origin; Pi₂, Pi₃, Pi₄, and Pi₅, primary laminae of insertion.

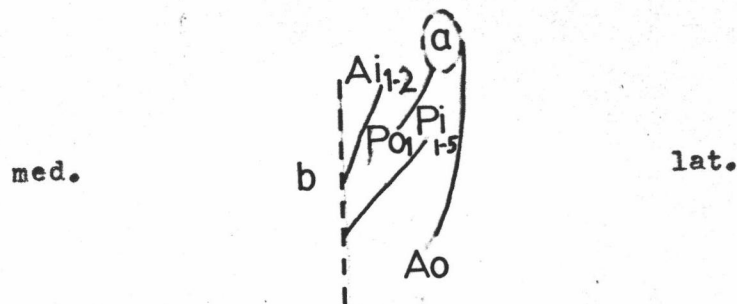


Fig. 87 The diagram of the vertical section of the masseter muscle of man. a, the zygomatic arch; b, the mandible. Ao, aponeurosis of origin; Po₁, primary lamina of origin; Ai₁₋₂, primary laminae of insertion; Pi₁₋₅, primary laminae of insertion.

Pi₃, Pi₄, and Pi₅. The middle muscle fibers which originate from the lateral surface of the primary laminae of origin, Po₁ and Po₂, pass downwards to insert on the medial surface of the primary laminae of insertion, Pi₁, Pi₂, Pi₃, Pi₄, and Pi₅. The fibers of the deep layer which arise from the medial surface of the primary laminae of origin, Po₁ and Po₂, pass downwards to the lateral surface of the aponeurosis of insertion, Ai₂, and the lateral surface of the mandible.

Medial Pterygoid Muscle of Man

General Description

The medial pterygoid muscle of man (Figs. 88 and 89) has two heads of origin. The anterior head is small. It arises from the maxillary tuberosity. The posterior head forms nearly the whole muscle. It arises from the medial surface of the lateral pterygoid plate deep to the lateral pterygoid muscle. The two heads unite inferior to the lateral pterygoid muscle. It passes downwards to insert on the medial surface of the mandible.

Internal Tendons of Origin

Formulae: Po₁, Po₂, Po₃, So₁, So₂, So₃, So₄

No aponeurosis of origin is visible. There are three primary laminae of origin. The quadrangular shaped primary lamina of origin, Po₁ (Fig. 92), arises from the maxillary tuberosity superficially and the medial surface of the lateral pterygoid plate deeply. Its lower margin has a fringe-like border. There are four secondary laminae of origin, So₁, So₂, So₃, and So₄ (Fig. 92),

arise from the medial surface of the primary lamina of origin, Po_1 . Three secondary laminae of origin, So_1 , So_2 , and So_3 , arise vertically from the anterior margin of the primary lamina of origin, Po_1 . The other secondary lamina of origin, So_4 , is a large rectangular tendon. It arises from the middle of the primary lamina of origin, Po_1 , and curves to the postero-medial surface of the muscle.

The primary lamina of origin, Po_2 (Fig. 93), is long and rectangular. It arises from the medial surface of the lateral pterygoid plate and lies at the posterior aspect of the muscle medial to the primary lamina of origin, Po_1 .

The primary lamina of origin, Po_3 (Fig. 94), is square. It arises from the medial surface of the lateral pterygoid plate and embeds at the middle of the muscle medial to the primary laminae of origin, Po_1 and Po_2 (Fig. 97).

Internal Tendons of Insertion

Formulae: Pi_1 , Pi_2 , Pi_3 , Pi_3' , Si

This muscle has no aponeurosis of insertion. Three primary laminae of insertion, Pi_1 , Pi_2 , and Pi_3 , arise from the medial surface of the muscle. The primary laminae of insertion, Pi_1 and Pi_2 (Fig. 95) are thin quadrangular tendons which embed in the anterior part of the muscle. They connect together at their lower extremity. The primary lamina of insertion, Pi_1 , lies between the secondary laminae of origin, So_1 and So_2 , while the primary lamina of insertion, Pi_2 , lies between the secondary laminae of origin, So_2 and So_3 .

The primary lamina of insertion, Pi_3 (Fig. 96), is a quadrangular tendon and lies at the posterior aspect of the muscle between the primary laminae of origin, Po_1 and Po_2 (Fig. 97). At the anterior border of the primary lamina of insertion, Pi_3 , there is a reflection to the medial surface named the reflected part, Pi_3^1 , of the primary lamina of insertion. It lies between the primary lamina of origin, Po_3 , and the secondary lamina of origin, So_4 (Fig. 97). The secondary lamina of insertion, Si , arises from the middle part of the primary lamina of insertion, Pi_3 . It is a thin quadrangular tendon and lies between the primary laminae of origin, Po_2 and Po_3 (Fig. 97).

The Arrangement of the Muscle Fibers (Figs. 90 and 91)

The arrangement of the muscle fibers is divided into two parts according to the two heads of origin, the anterior and posterior parts. The muscle fibers of the anterior part are two bipinnate arrangements. The fibers of the anterior one arise from the posterior surface of the secondary lamina of origin, So_1 , and from the anterior surface of the secondary lamina of origin, So_2 . They pass downwards to insert on the anterior and posterior surface of the primary lamina of insertion, Pi_1 . The fibers of the posterior bipinnate originate from the posterior surface of the secondary lamina of origin, So_2 and the anterior surface of the secondary lamina of origin, So_3 . They also run downwards to terminate at the anterior and posterior surface of the primary lamina of insertion, Pi_2 . Besides, there are some muscle fibers from both medial and lateral surface of the secondary laminae of origin, So_1 , So_2 , and

Fig. 88 The medial surface of the isolated medial pterygoid muscle of man. So_1 , So_2 , So_3 , and So_4 are secondary laminae of origin.

Fig. 89 The lateral surface of the isolated medial pterygoid muscle of man. Po_1 , Po_2 , and Po_3 are primary laminae of origin.

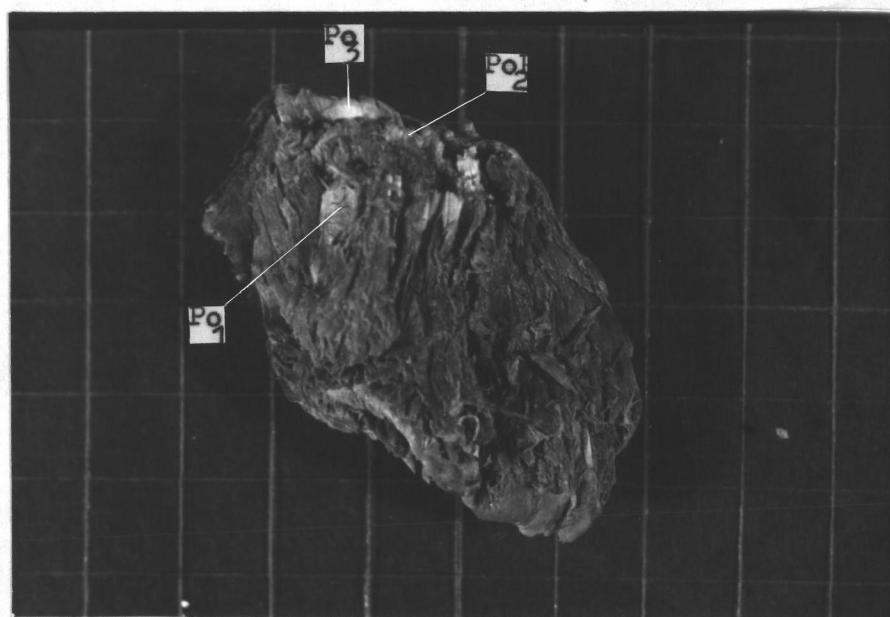
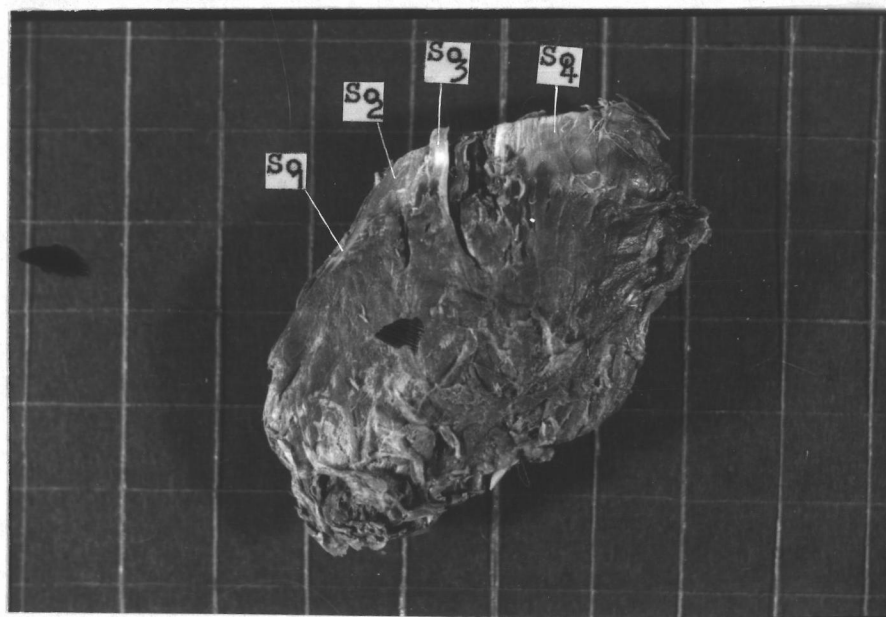

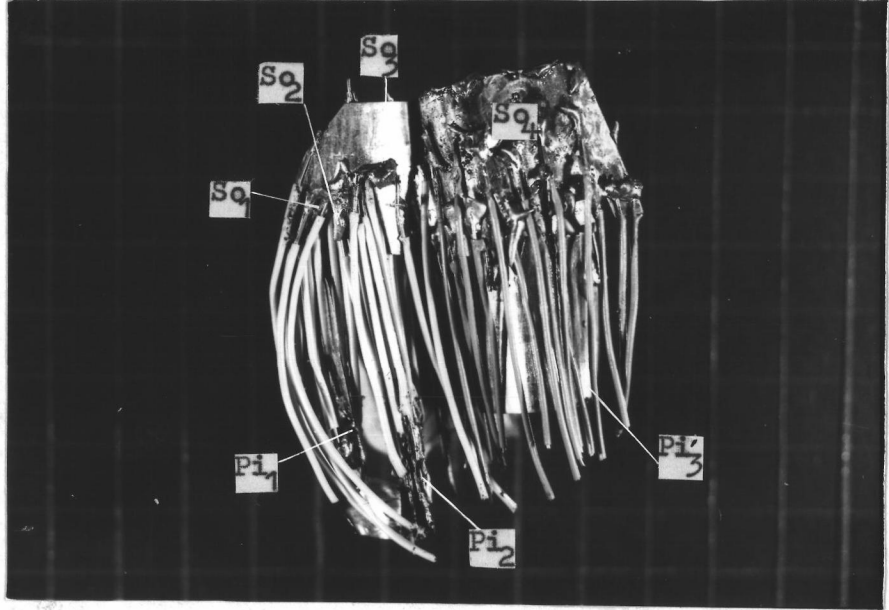
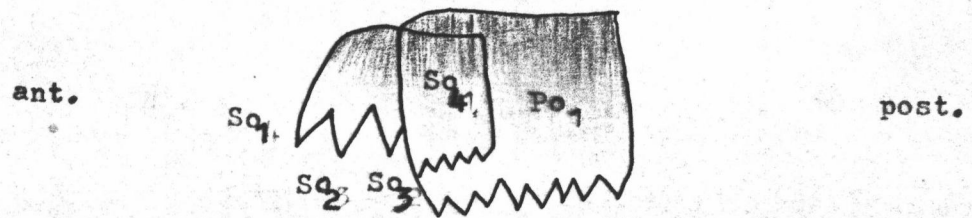


Fig. 90 The medial aspect of the model of the medial pterygoid muscle of man. Compare with Fig. 88. Wires indicate directions of muscle fibers. So_1 , So_2 , So_3 , and So_4 are secondary laminae of origin. Pi_3 , reflected part of the primary lamina of insertion, Pi_3 not visible here; Pi_1 and Pi_2 , the slender primary laminae of insertion.

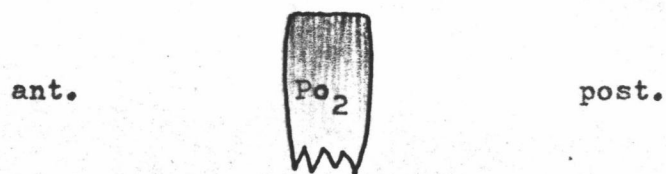Fig. 91 The lateral aspect of the model of the medial pterygoid muscle. Compare with Fig. 89. Wires indicate directions of muscle fibers. Po_1 and Po_2 , primary laminae of origin; Pi_1 , Pi_2 , and Pi_3 are primary laminae of insertion; Si , secondary lamina of insertion arise from the primary lamina of insertion, Pi_3 .





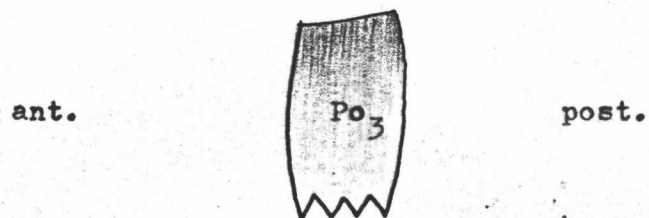
92

Fig. 92 The diagram of the medial surface of the primary lamina of origin, Po₁, of the medial pterygoid muscle of man, showing the secondary laminae of origin, So₁, So₂, So₃, So₄:



93

Fig. 93 The diagram of the medial surface of the primary lamina of origin, Po₂, of the medial pterygoid muscle of man.



94

Fig. 94 The diagram of the medial surface of the primary lamina of origin, Po₃, of the medial pterygoid muscle of man.

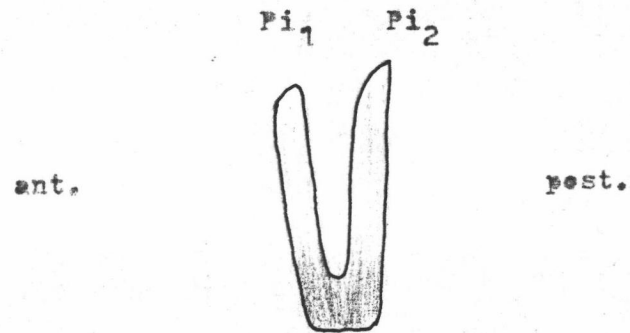


Fig. 95 The diagram of the medial surface of the primary laminae of insertion, Pi_1 and Pi_2 , of the medial pterygoid muscle of man.

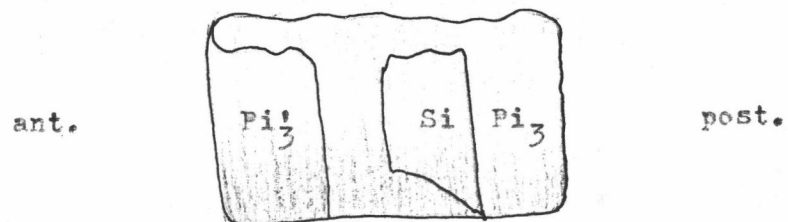


Fig. 96 The diagram of the medial surface of the primary lamina of insertion, Pi_3 , of the medial pterygoid muscle of man, showing the reflected part, Pi_3' , of the primary lamina of insertion and the secondary lamina of insertion, Si .

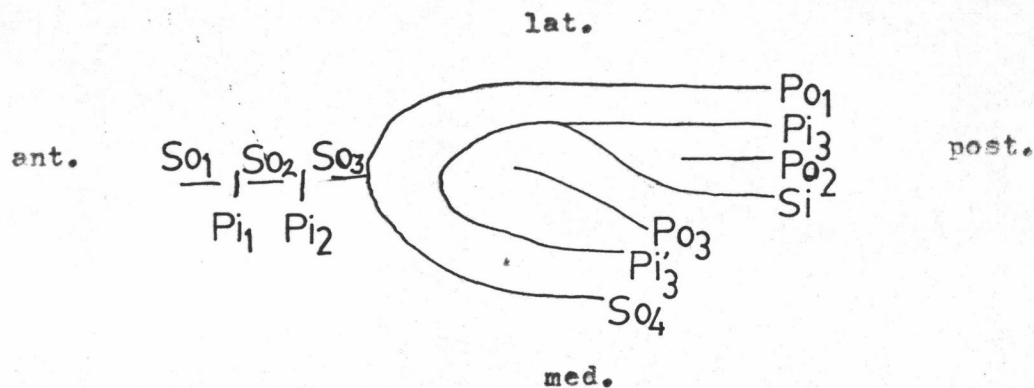


Fig. 97 The diagram of the horizontal section of the medial pterygoid muscle of man. Po_1 , Po_2 , and Po_3 , primary laminae of origin; So_1 , So_2 , So_3 , and So_4 , secondary laminae of origin; Pi_1 , Pi_2 , Pi_3 , and Pi'_3 , primary laminae of insertion.

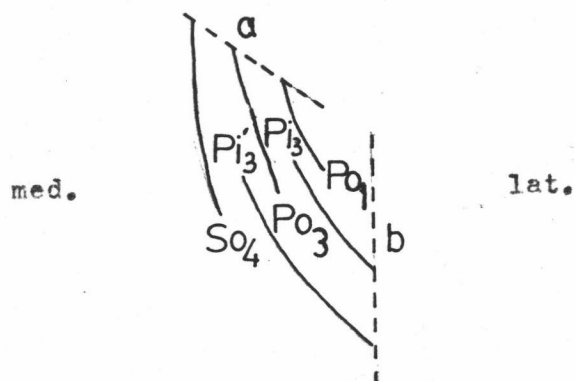


Fig. 98 The diagram of the vertical section of the medial pterygoid muscle of man. a , the medial surface of the lateral pterygoid plate; b , the mandible. Po_1 and Po_3 , primary laminae of origin; So_4 , secondary lamina of origin; Pi_3 and Pi'_3 , primary laminae of insertion.

So₃, pass downwards to insert on the medial surface of the ramus of mandible.

The muscle fibers of the posterior part are subdivided into six layers. From medial to lateral, the fibers of the first layer originate from the medial surface of the secondary lamina of origin, So₄. They run downwards to the medial surface of the ramus of mandible. In the second layer, the fibers which arise from the lateral surface of the secondary lamina of origin, So₄, run downwards and insert on the medial surface of the reflected part, Pi₃¹, of the primary lamina of insertion. The muscle fibers of the third layer originate from the medial surface of the primary lamina of origin, Po₃. They pass downwards to the lateral surface of the reflected part, Pi₃, of the primary lamina of origin. The muscle fibers of the fourth layer arise from the lateral surface of the primary lamina of origin, Po₃, run downwards to the medial surface of the anterior part of the primary lamina of insertion, Pi₃, anteriorly; and to the medial surface of the secondary lamina of insertion, Si, posteriorly. Laterally to the secondary lamina of insertion, Si, two layers of muscle fibers arise from the primary lamina of origin, Po₂. These fibers from its medial surface insert on the lateral surface of the secondary lamina of insertion, Si. The other fibers which arise from the lateral surface of the primary lamina of origin, Po₂, terminate at the posterior part of the medial surface of the primary lamina of insertion, Pi₃. In the fifth layer, the fibers arise from the posterior part of the medial surface of the primary lamina of origin, Po₁. They run downwards to the lateral

surface of the primary lamina of insertion, Pi_3 . The muscle fibers of the sixth layer which originate from the posterior part of the lateral surface of the primary lamina of origin, Po_1 , pass downwards to insert on the medial surface of the ramus of mandible.

Lateral Pterygoid Muscle of Man

General Description

The lateral pterygoid muscle of man (Fig. 99) is a triangular muscle. It likes the medial pterygoid muscle, also has two heads of origin. The upper head is a small head which arises from the infratemporal ridge. The lower head is a large head which arises from the lateral surface of the lateral pterygoid plate. These two heads join together and insert on the front of the neck of mandible and the articular disc of the temporomandibular joint.

Internal Tendons of Origin

No external and internal tendons of origin are found.

Internal Tendons of Insertion

Formulae: Pi_1, Pi_2



This muscle has two thin primary laminae of insertion, Pi_1 (Fig. 101), superiorly, and Pi_2 , inferiorly. The superior one, Pi_1 , is a small and a penta surface. It arises from the articular disc. The inferior one, Pi_2 , is little larger and an irregular shape. It arises from the neck of the mandible (Fig. 102).

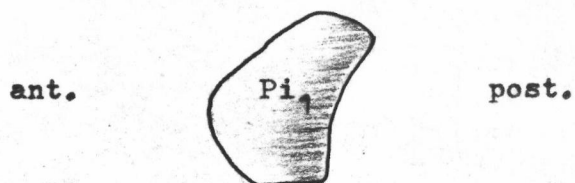
The Arrangement of the Muscle Fibers (Fig. 100)

The arrangement of the muscle fibers of the lateral ptery-

Fig. 99 The lateral surface of the isolated lateral pterygoid muscle of man. a, temporal condyle.

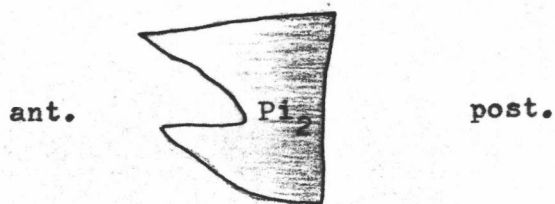
Fig. 100 The lateral surface of the model of the lateral pterygoid muscle of man. Compare with Fig. 99. Wires indicate directions of muscle fibers. Pi_1 and Pi_2 , primary laminae of insertion.





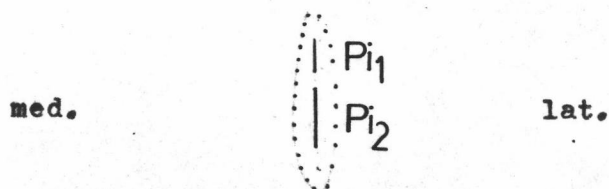
101

Fig. 101 The diagram of the lateral surface of the primary lamina of insertion, Pi_1 , of the lateral pterygoid muscle of man.



102

Fig. 102 The diagram of the lateral surface of the primary lamina of insertion, Pi_2 , of the lateral pterygoid muscle of man.



103

Fig. 103 The diagram of the vertical section of the lateral pterygoid muscle of man, dotted line indicates the border of the muscle. Pi_1 and Pi_2 , primary laminae of insertion.

oid is separated into two parts according to the two heads of origin. The muscle fibers of the superior head which arise from the infratemporal ridge and the infratemporal surface of the greater wing of the sphenoid, pass posteriorly to the medial and lateral surface of the primary lamina of insertion, Pi_1 . The muscle fibers of the lower head originate from the lateral surface of the lateral pterygoid plate, and pass horizontally to insert on the medial and lateral surface of the primary lamina of insertion, Pi_2 .