

ผลของสารสกัดมาตรฐานบัวบก อีซีไอ 233 ต่อการสมานแผลใหม่ระดับที่สอง
ในหนูแรทปกติและหนูแรทที่ถูกเหนี่ยวนำให้เป็นเบาหวาน

นางสาวกรณิศ วรรณรัตน์

วิทยานิพนธ์นี้เป็นส่วนหนึ่งของการศึกษาตามหลักสูตรปริญญาวิทยาศาสตรมหาบัณฑิต
สาขาวิชาเภสัชวิทยา (สหสาขาวิชา)
บัณฑิตวิทยาลัย จุฬาลงกรณ์มหาวิทยาลัย
ปีการศึกษา 2552
ลิขสิทธิ์ของจุฬาลงกรณ์มหาวิทยาลัย

EFFECTS OF STANDARDIZED EXTRACT OF *CENTELLA ASIATICA* ECa 233
ON SECOND DEGREE BURN WOUND HEALING IN NORMAL AND DIABETIC RATS

Miss Koranit Wannarat

A Thesis Submitted in Partial Fulfillment of the Requirements
for the Degree of Master of Science Program in Pharmacology

(Interdisciplinary Program)

Graduate School

Chulalongkorn University

Academic Year 2009

Copyright of Chulalongkorn University

Thesis Title	EFFECTS OF STANDARDIZED EXTRACT OF <i>CENTELLA ASIATICA</i> ECa 233 ON SECOND DEGREE BURN WOUND HEALING IN NORMAL AND DIABETIC RATS
By	Miss Koranit Wannarat
Field of Study	Pharmacology
Thesis Advisor	Associate Professor Mayuree Tantisira, Ph.D.
Thesis Co-Advisor	Associate Professor Boonyong Tantisira, Ph.D.

Accepted by the Graduate School, Chulalongkorn University in Partial
Fulfillment of the Requirements for the Master's Degree

.....Dean of the Graduate School
(Associate Professor Pornpote Plumsomboon, Ph.D.)

THESIS COMMITTEE

..... Chairman
(Assistant Professor Wacharee Limpanasithikul, Ph.D.)

..... Thesis Advisor
(Associate Professor Mayuree Tantisira, Ph.D.)

..... Thesis Co-Advisor
(Associate Professor Boonyong Tantisira, Ph.D.)

..... Examiner
(Assistant Professor Nipan Israsena Na Ayuthaya, M.D., Ph.D.)

..... External Examiner
(Associate Professor Pornprom Muangman, M.D.)

..... External Examiner
(Naphatsanan Duansak, Ph.D.)

กรณีศ วรณรัตน์ : ผลของสารสกัดมาตรฐานบัวบก อีซีเอ 233 ต่อการสมานแผลใหม่
ระดับที่สองในหนูแรพปกติและหนูแรพที่ถูกเหนี่ยวนำให้เป็นเบาหวาน. (EFFECTS OF
STANDARDIZED EXTRACT OF *CENTELLA ASIATICA* ECa 233 ON SECOND
DEGREE BURN WOUND HEALING IN NORMAL AND DIABETIC RATS)

อ.ที่ปรึกษาวิทยานิพนธ์หลัก : รศ.ภญ.ดร.มยุรี ตันตีสิริระ, อ.ที่ปรึกษาวิทยานิพนธ์ร่วม :
รศ.ภก.ดร.บุญยงค์ ตันตีสิริระ, 117 หน้า.

การศึกษานี้มีวัตถุประสงค์เพื่อศึกษาผลของสารสกัดมาตรฐานบัวบก อีซีเอ 233 ต่อการสมานแผลใหม่
ระดับที่สอง ทำให้เกิดแผลใหม่โดยนำแผ่นโลหะ อุดนภูมิ 90 องศาเซลเซียส วางทับบริเวณหลังหนู เป็นเวลา
10 วินาที ทำการศึกษาในหนูแรพ เพศผู้ สายพันธุ์ Wistar น้ำหนัก 250-300 กรัม แบ่งออกเป็น 2 กลุ่มใหญ่
ได้แก่ หนูแรพปกติและหนูแรพที่ถูกเหนี่ยวนำให้เป็นเบาหวาน และแบ่งออกเป็น 6 กลุ่มย่อย คือ กลุ่มไม่ทำให้
เกิดแผลใหม่ กลุ่มที่ทำให้เกิดแผลใหม่และไม่ได้รับการรักษาใดๆ กลุ่มที่ทำให้เกิดแผลใหม่และได้รับการทาด้วย
เจลที่ไม่มีสารสกัดมาตรฐานบัวบก อีซีเอ 233 กลุ่มที่ทำให้เกิดแผลใหม่และได้รับการทาด้วยสารสกัดมาตรฐาน
บัวบก อีซีเอ 233 ในรูปเจล ความเข้มข้น 0.05, 0.1 และ 0.5 เปอร์เซ็นต์ ทาแผลด้วยสารต่างๆ ขนาด 100
มิลลิกรัม วันละ 1 ครั้ง ประเมินผลโดยการสังเกตลักษณะภายนอกของแผล คำนวณอัตราการสมานแผล วัด
ปริมาณการไหลเวียนเลือดที่ผิวหนัง ศึกษาปฏิกิริยา लिพิดเปอร์ออกซิเดชัน และการเปลี่ยนแปลงทางพยาธิวิทยา
ในวันที่ 3, 7 และ 14 หลังเกิดแผลใหม่

ผลการทดลอง พบว่าสารสกัดมาตรฐานบัวบก อีซีเอ 233 มีฤทธิ์ช่วยเร่งกระบวนการสมานแผลทั้งใน
หนูแรพปกติและหนูแรพที่ถูกเหนี่ยวนำให้เป็นเบาหวาน โดยหนูที่ได้รับสารสกัดมาตรฐานบัวบกอีซีเอ 233 มี
ขนาดของแผลเล็กลงอย่างมีนัยสำคัญทางสถิติเมื่อเปรียบเทียบกับกลุ่มที่ไม่ได้รับการรักษาและกลุ่มที่ทาด้วย
เจลที่ไม่มีสารสกัดมาตรฐานบัวบกอีซีเอ 233 นอกจากนี้พบว่าสารสกัดมาตรฐานบัวบก อีซีเอ 233 มีฤทธิ์เพิ่ม
การไหลเวียนของเลือดที่ผิวหนังโดยหนูแรพที่ถูกเหนี่ยวนำให้เป็นเบาหวานที่ได้รับสารสกัดมาตรฐานบัวบกอีซีเอ
233 มีค่าเฉลี่ยร้อยละของปริมาณการไหลเวียนเลือดที่ผิวหนังเพิ่มขึ้นอย่างมีนัยสำคัญทางสถิติ ตลอดการ
ทดลอง ในขณะที่หนูแรพปกติจะพบการตอบสนองดังกล่าวในวันที่ 3 และ 7 เท่านั้น มีฤทธิ์ลดระดับสารอนุมูล
อิสระ ในวันที่ 3, 7 และ 14 ในหนูแรพปกติและวันที่ 14 ในหนูแรพที่ถูกเหนี่ยวนำให้เป็นเบาหวาน จากการสังเกต
ลักษณะของแผลและการเปลี่ยนแปลงทางพยาธิวิทยา ในกลุ่มที่ได้รับสารสกัดมาตรฐานบัวบก อีซีเอ 233 พบว่า
ระดับเซลล์อักเสบลดลง และมีจำนวนต่อมขนเพิ่มขึ้น ในหนูแรพกลุ่มที่ทาด้วยสารสกัดมาตรฐานบัวบก อีซีเอ
233 ในวันที่ 3 และ 7 ทั้งในหนูแรพปกติและที่ถูกเหนี่ยวนำให้เป็นเบาหวาน

การศึกษานี้แสดงให้เห็นว่า สารสกัดมาตรฐานบัวบก อีซีเอ 233 สามารถเร่งการสมานแผลใหม่ได้ทั้งใน
หนูแรพปกติและหนูแรพที่ถูกเหนี่ยวนำให้เป็นเบาหวาน โดยยับยั้งกระบวนการอักเสบ และเร่งการสร้างเซลล์
ผิวหนังใหม่ เพิ่มปริมาณการไหลเวียนเลือดที่ผิวหนัง เพิ่มจำนวนต่อมขนและลดระดับสารอนุมูลอิสระได้ จึงอาจ
กล่าวได้ว่า สารสกัดมาตรฐานบัวบก อีซีเอ 233 สามารถเร่งกระบวนการหายของแผลใหม่ระดับที่สองได้

สาขาวิชาเภสัชวิทยา..... ลายมือชื่อ.....
ปีการศึกษา2552..... ลายมือชื่อ.....อ.ที่ปรึกษาวิทยานิพนธ์หลัก.....
ลายมือชื่อ.....อ.ที่ปรึกษาวิทยานิพนธ์ร่วม.....

5087108020 : MAJOR PHARMACOLOGY

KEYWORDS : *CENTELLA ASIATICA*/ SECOND DEGREE BURN / WOUND HEALING/ DIABETIC/
ECa 233

KORANIT WANNARAT: EFFECTS OF STANDARDIZED EXTRACT OF *CENTELLA ASIATICA* ECa 233 ON SECOND DEGREE BURN WOUND HEALING IN NORMAL AND DIABETIC RATS. THESIS ADVISOR : ASSOC. PROF. MAYUREE TANTISIRA, Ph.D., THESIS CO-ADVISOR : ASSOC. PROF. BOONYONG TANTISIRA, Ph.D., 117 pp.

The purpose of this study was to investigate the effects of standardized extract of *Centella asiatica* ECa 233 on second degree burn wound healing induced by 90° C hot plate for 10 seconds on the selected area of the back. Male Wistar rats weighing 250-300 g were used and divided into two groups for normal and diabetic rats. In each group, the animals were subdivided into six subgroups as follows : no burn, burn with no treatment (untreated), burn treated with gel base, burn treated with 0.05, 0.1 and 0.5% ECa 233 gel. The wounds were daily treated with 100 mg of the test substances topically. Evaluation of wound healing including a visual observation, an estimation of rate of wound healing, measurement of cutaneous blood flow, lipid peroxidation assay and histopathological observation was made at day 3, 7 and 14 post burning.

The result revealed that rate of wound healing in both normal and diabetic rats treated with ECa 233 was significantly different from those observed in their respective untreated and gel base-treated groups. In comparison to their respective control groups, cutaneous blood flow was significantly increased in ECa 233-treated groups at all three time points in diabetic rats whereas it was observed only at day 3 and 7 in normal group. In normal, burn injury significantly increased oxidative stress which was counteracted by ECa 233 throughout experimental period. However, in diabetic, antioxidant property of ECa 233 was evident only on day 14. Visual and histopathological observation, application of ECa 233 seemed to reduce inflammatory cell in normal and diabetic rats though with a lesser extent in the latter group. In addition, the number of hair follicles in ECa 233-treated groups, both in normal and diabetic rats were found to increase on day 3 and 7 post burning.

In conclusion topical application of standardized extract of *Centella asiatica* ECa 233 clearly facilitated burn wound healing in normal and diabetic rats. Shortening of inflammatory process by its anti-inflammatory, increased rate of re-epithelialization and might explain the results observed. Increased of cutaneous blood flow, increased number of hair follicles and anti-oxidation could play role as well. Some other mechanisms await further investigation.

Field of Study : Pharmacology..... Student's Signature

Academic Year : 2009..... Advisor's Signature

Co-Advisor's Signature

ACKNOWLEDGEMENTS

I wish to express my sincere gratitude and deepest appreciation to my thesis advisor, Assoc. Prof. Mayuree Tantisira, Ph.D. and my thesis co-advisor Assoc. Prof. Boonyong Tantisira, Ph.D. Department of Pharmacology and Physiology, Faculty of Pharmaceutical Sciences, Chulalongkorn University whose encouraging guidance and open-mindedness to discuss anything anytime during the long working process, which enable me to accomplish this thesis.

I would also express my sincere appreciation to the committee of this thesis examination; Asst. Prof. Wacharee Limpanasithikul, Ph.D. and Asst. Prof. Nipan Israsena Na Ayuthaya, M.D., Ph.D. Department of Pharmacology, Faculty of Medicine, Chulalongkorn University. Assoc. Prof. Pornprom Muangman, M.D. Division of Trauma, Department of Surgery, Faculty of Medicine, Siriraj Hospital, Mahidol University and Naphatsanan Duansak, Ph.D. Division of Physiology, Faculty of Medicine, Thammasat University for their constructive comment and suggestions.

I would also express my sincere thank to Assoc. Prof. Suthiluk Patumraj, Department of Physiology, Faculty of Medicine, Chulalongkorn University for helping me and facilitate on support machine Laser Doppler Flowmeter.

I would also express my sincere thank to Assoc. Prof. Vilai Chintanes, Ph.D., Mrs. Atitaya Kaewsema, Department of Anatomy and Assoc. Prof. Juraiporn Somboonwong, M.D., M.Sc. Department of Physiology, Faculty of Medicine, Chulalongkorn University for helping me and facilitate on histopathological analysis.

I wish to thank all researchers from my literature for giving me the supporting data, knowledge and idea.

I wish to express my sincere thanks to my colleagues for their helps, supports and friendship.

Finally, I would like to eternally thank to my family for their encouragement, love and caring which make everything possible.

CONTENTS

	PAGE
ABSTRACT(Thai).....	iv
ABSTRACT(English).....	v
ACKNOWLEDGEMENTS.....	vi
CONTENTS.....	vii
LIST OF FIGURES.....	x
LIST OF ABBREVIATIONS.....	xii
CHAPTER	
I INTRODUCTION.....	1
Background and Rationale.....	1
Objective.....	4
Hypothesis.....	4
Keywords.....	4
II LITERATURE REVIEWS.....	5
2.1 The skin.....	5
2.1.1 Structure of the skin.....	5
2.1.2 Function of the skin.....	7
2.2 Hair follicle.....	8
2.2.1 The hair cycle.....	8
2.2.2 Hair follicle and wound healing.....	10
2.3 The wound and wound healing.....	12
2.3.1 Definition of wound.....	12
2.3.2 Types of wounds.....	12
2.3.3 Wound healing.....	13
2.3.4 Types of wound healing.....	20
2.4 Local and systemic factors that influence wound healing.....	23
2.5 The burn wound and wound healing.....	24

CHAPTER	PAGE
2.5.1 Definition of a burn.....	24
2.5.2 Types of burns.....	24
2.5.3 Pathophysiology of thermal burns.....	25
2.5.4 Classification of burn depth.....	29
2.5.5 Assessment of burn area.....	32
2.5.6 Burn wound healing.....	34
2.5.7 Free radical and antioxidant therapy.....	35
2.5.8 Management of burn injuries.....	36
2.6 Diabetes mellitus and wound healing.....	37
2.7 <i>Centella asiatica</i> (Linn.) Urban.....	40
2.7.1 Morphological description.....	40
2.7.2 Major chemical constituents.....	41
2.7.3 Traditional applications.....	42
2.7.4 Pharmacological study.....	43
III MATERIAL AND METHODS.....	46
3.1 Materials.....	46
3.1.1 Chemical substances.....	46
3.1.2 Instrument.....	46
3.1.3 Experimental animal.....	47
3.1.4 Preparation of test compound.....	48
3.2 Methods.....	48
3.2.1 Induction of diabetes.....	48
3.2.2 Induction of second degree of burn injury.....	48
3.2.3 Animal preparation.....	51
3.3 Evaluation of burn wound.....	53
3.3.1 General appearance of the wound.....	53
3.3.2 Rate of wound healing.....	53
3.3.3 Cutaneous blood flow.....	53
3.3.4 Lipid peroxidation assay.....	55
3.3.5 Histopathological analysis.....	55

CHAPTER	PAGE
3.3.6 Histopathological evaluation of hair follicles.....	55
3.4 Statistical analysis.....	56
IV RESULTS.....	57
V DISCUSSION AND CONCLUSION	95
REFERENCES.....	99
APPENDICES.....	108
APPENDIX A.....	109
APPENDIX B.....	111
BIOGRAPHY.....	117

LIST OF FIGURES

FIGURE	PAGE
2.1 Structure of the skin.....	5
2.2 Morphology of the human hair follicle.....	9
2.3 The wound healing.....	19
2.4 Steps in wound healing by first intention and second intention.....	22
2.5 Jackson's burn zone.....	28
2.6 Classification of burn depth.....	31
2.7 Wallace rule of nines and Lund and Brownder chart.....	33
2.8 Treatment of wound.....	36
2.9 <i>Centella asiatica</i> (Linn.) Urban.....	40
2.10 Structure of asiatic acid, madecassic acid, asiaticoside and madecassoside.....	41
3.1 Electrical hot plate.....	50
3.2 The area prepared for wounding of burn wound.....	50
3.3 Diagram of experimental animal groups.....	52
3.4 Laser Doppler Flowmeter.....	54
3.5 Selected position in the wound area for the measurement of cutaneous blood flow.....	54
4.1 Rate of wound healing on day 3 post burning in normal rats.....	57
4.2 Rate of wound healing on day 7 post burning in normal rats.....	58
4.3 Rate of wound healing on day 14 post burning in normal rats.....	59
4.4 Rate of wound healing on day 3 post burning in diabetic rats.....	60
4.5 Rate of wound healing on day 7 post burning in diabetic rats.....	61
4.6 Rate of wound healing on day 14 post burning in diabetic rats.....	62
4.7 The wound appearance on day 3 post burning in normal rats.....	63
4.8 The wound appearance on day 7 post burning in normal rats.....	64
4.9 The wound appearance on day 14 post burning in normal rats.....	65
4.10 The wound appearance on day 3 post burning in diabetic rats.....	66
4.11 The wound appearance on day 7 post burning in diabetic rats.....	67

FIGURE	PAGE
4.12 The wound appearance on day 14 post burning in diabetic rats.....	68
4.13 Cutaneous blood flow on day 3 post burning in normal rats.....	69
4.14 Cutaneous blood flow on day 7 post burning in normal rats.....	70
4.15 Cutaneous blood flow on day 14 post burning in normal rats.....	71
4.16 Cutaneous blood flow on day 3 post burning in diabetic rats.....	72
4.17 Cutaneous blood flow on day 7 post burning in diabetic rats.....	73
4.18 Cutaneous blood flow on day 14 post burning in diabetic rats.....	74
4.19 Malondialdehyde (MDA) level on day 3 post burning in normal rats.....	75
4.20 Malondialdehyde (MDA) level on day 7 post burning in normal rats.....	76
4.21 Malondialdehyde (MDA) level on day 14 post burning in normal rats.....	77
4.22 Malondialdehyde (MDA) level on day 3 post burning in diabetic rats.....	78
4.23 Malondialdehyde (MDA) level on day 7 post burning in diabetic rats.....	79
4.24 Malondialdehyde (MDA) level on day 14 post burning in diabetic rats.....	80
4.25 Histopathological of skin section on day 3 post burning in normal rats.....	82
4.26 Histopathological of skin section on day 7 post burning in normal rats.....	83
4.27 Histopathological of skin section on day 14 post burning in normal rats.....	84
4.28 Histopathological of skin section on day 3 post burning in diabetic rats.....	86
4.29 Histopathological of skin section on day 7 post burning in diabetic rats.....	87
4.30 Histopathological of skin section on day 14 post burning in diabetic rats...	88
4.31 The number of hair follicles per mm ² on day 3 post burning in normal rats..	89
4.32 The number of hair follicles per mm ² on day 7 post burning in normal rats..	90
4.33 The number of hair follicles per mm ² on day 14 post burning in normal rats	91
4.34 The number of hair follicles per mm ² on day 3 post burning in diabetic rats	92
4.35 The number of hair follicles per mm ² on day 7 post burning in diabetic rats	93
4.36 The number of hair follicles per mm ² on day 14 post burning in diabetic rats.....	94

LIST OF ABBREVIATIONS

ARDS	Adult respiratory distress syndrome
bFGF	Basic fibroblast growth factor
BW	Body weight
CA	<i>Centella asiatica</i>
CAD	Coronary artery disease
cm	Centimeter
cm ²	Square centimeter
°C	Degree Celsius
DM	Diabetes mellitus
DNA	Deoxyribonucleic acid
ECa 233	Standardized Extract of <i>Centella asiatica</i>
ECM	Extracellular matrix
EGF	Epidermal growth factor
e.g.	Exempli gratia (for example)
GSH	Glutathione
GSH-Px	Glutathione peroxidase
G6PD	Glucose-6-phosphate dehydrogenase deficiency
g/L	Gram per liter
h	Hour
iNOS	inducible nitric oxide synthase
IL-β	Interleukin-β
i.p.	Intraperitoneal
i.v.	Intravenous
LPS	Lipopolysaccharide
M	Molar (mole per liter)
MCP-1	Monocyte chemoattractant protein-1
MDA	Malondialdehyde
min	Minute
mg/kg	Milligram per kilogram

ml	Milliliter(s)
MODS	Multiple organ dysfunction syndrome
ng	Nanogram
nm	Nanometer
PDGF	Platelet derived growth factor
pg	Picogram
PTZ	Pentylentetrazole
PUFAs	Polyunsaturated fatty acids
ROS	Reactive oxygen species
rpm	Revolution per minute
sec	Seconds
S.E.M.	Standard error of means
SIRS	Systemic inflammatory response syndrome
STZ	Streptozotocin
TECA	Titrated extract <i>Centella asiatica</i>
TGF- α	Transforming growth factor- α
TGF- β	Transforming growth factor- β
TNF- α	Tumor necrosis factor- α
VEGF	Vascular endothelial growth factor
VEGFR-2	Vascular endothelial growth factor receptor-2
$\mu\text{mol/g}$	Micromole per gram

CHAPTER I

INTRODUCTION

Background and Rationale

Thermal burn is more commonly induced in tissues by the sudden application of excessive thermal energy. The local and systemic inflammatory response to thermal burn is extremely complex, resulting in both local burn tissue damage and deleterious systemic effects on all other organ systems distant from the burn area itself. These include fluid and protein loss, local and systemic sepsis, gross metabolic, hematological and immune disturbances [1]. These results in morbidity and mortality associated with burn injury.

Thermal injury initiates systemic inflammatory reactions producing burn toxin, oxygen radicals and finally leads to peroxidation. The relationship between the amount of products of oxidative metabolism and natural scavengers of free radicals determine the outcome of local and distant tissue damage and further organ failure in burn injury [2].

Free radicals and their scavenging system are also known to play a very important role in healing of normal and delayed healing type of wound [3, 4]. In many tissue such as skin, burn associated with lipid peroxidation, which is believed to be an important cause of oxidative damage to cellular membranes, and eventually cell death [5, 6]. A good indicator of oxidative injury and end product of lipid peroxidation is the formation of malondialdehyde (MDA). Several studies demonstrated that burn is associated with elevated levels of MDA in different organ and tissue [7, 8]. At is point the early intervention of antioxidant therapy will significantly help to restore cell mediated injury, decrease free radical mediated damage, minimize tissue destruction during extensive burn injury and might to help promote the healing of burn injury [9].

Optimum treatment of the wound reduces morbidity and mortality. It also shorten the time for healing and return of normal function and reduces the need for secondary reconstruction [10]. Factors affecting wound healing include wound care,

good nutrition, improvement of the blood supply of partial-thickness burns, prevention of wound infection, reduction of wound edema formation [11, 12], associated illness such as diabetes mellitus [13].

Diabetes mellitus is a metabolic disorder that continues to present a major worldwide health problem. It is characterized by chronic hyperglycemia with disturbances of carbohydrate, fat and protein metabolism resulting from defects in insulin secretion and/or insulin action at target tissue or both [14]. As a consequence of the metabolic derangement in diabetes, various complications develop including both microvascular and macrovascular dysfunctions [15]. Various studies have shown that diabetes mellitus is associated with increased formation of free radicals and decrease in antioxidant potential. It is accepted that oxidative stress results from an imbalance between the generation of oxygen derived radicals and the organism's antioxidant potential [16]. It is evident that hyperglycemia results in the generation of reactive oxygen species (ROS), ultimately leading to increased oxidative stress in variety of tissues [17]. Delayed wound healing in diabetes is caused by several intrinsic factors (neuropathy, vascular problems, other complicating systemic effects due to diabetes) and extrinsic factors (wound infection, callus formation and excessive pressure to the site) [18].

Burn wound care is needed according to the severity of burn. The concepts of optimum minor burn wound treatment focused on avoiding wound infection, treated with topical antibiotic agents or ointment, occlusive and wet dressing [10]. Topical antibiotics are used routinely in the forms of antimicrobial creams e.g. silver sulfadiazine applied locally to skin injury.

Silver sulfadiazine cream, the topical antimicrobial agent can inhibit DNA replication and modifications of the cell membrane and cell wall. It is used for prevention and treatment of infection in second and third degree burns. Although it is a broad spectrum antimicrobial, it has the disadvantage of not being absorbed through eschar. Thus, it is not effective in the wound that has eschar or infection. The adverse effects of this agent are skin reactions, such as pain, burning, itching or hypersensitivity and transient leucopenia. Due to bone marrow suppression, the use of silver sulfadiazine in G6PD patient may cause hemolytic anemia [19].

Despite the existence of many advanced medical treatments, we still have to encounter the side effects and high expense. In Thailand, there are many kinds of herbs including *Centella asiatica* (Linn.) Urban that have been advocated for their wound healing effect.

Centella asiatica (Linn.) Urban is a traditional herbal medicine used in Asiatic countries for hundreds of years. The major constituents are triterpenoids, mainly asiatic acid, asiaticoside, madecassic acid and madecassoside [20].

C.asiatica has been used for the treatment of psoriasis, wound healing, ulceration and eczema. They also have the benefits of memory improvement, anti-inflammatory, anticancer, antioxidant and anxiolytic [21].

Shukla et al. (1999) reported that the wound healing activity of asiaticoside, isolated from *C.asiatica* increased hydroxyproline content, tensile strength, collagen content and epithelialization in punch wound model thereby facilitating the healing [22]. Later, the study of Kimura et al. (2008) demonstrated that the topical application of a low dose (10 pg – 100 ng/wound area) of asiaticoside facilitated burn wound. These findings suggest that the enhancement of burn wound healing by asiaticoside might be due to the promotion of angiogenesis during skin wound repair as a result of the stimulation of vascular endothelial growth factor (VEGF) production caused by the increase in monocyte chemoattractant protein-1 (MCP-1) expression in keratinocytes and increase in interleukin- β (IL- β) expression in macrophage [23].

Furthermore, Liu et al. (2008) reported that madecassoside isolated from *Centella asiatica* had significant wound healing activity when administered orally at higher doses (12 and 24 mg/kg) decreased nitric oxide (NO) levels and malondialdehyde (MDA) content in the burn skin tissue [24].

Previous studies of *Centella asiatica* have been conducted mostly on many different types of extract and sometime with unknown amount of bioactive constituents making results uncomparable or even disagree. Recently ECa 233 which is a titrated extract of *Centella asiatica* was established by a group of researchers from the Faculty of Pharmaceutical Sciences, Chulalongkorn University. ECa 233 is a white to off-white standardized extracted powder of *C.asiatica* containing triterpenoids not less than 80% and the ratio between madecassoside and asiaticoside was kept at 1.5 ± 0.5 .

Acute toxicity and sub-chronic toxicity study of ECa 233 have revealed its very favorable toxicological profiles. No death was observed in mice acutely treated with ECa 233 in the dose up to 10 g/kg and oral administration of ECa 233 in the doses of 10-1000 mg/kg for 90 days did not cause any significant changes in any parameters observed [25].

Therefore, we consider it interesting to investigate the effects of standardized extract of *Centella asiatica* ECa 233 on second degree burn wound healing in normal and diabetic rats.

Objective

To study the effects of standardized extract of *Centella asiatica* ECa 233 on second degree burn wound healing in normal and diabetic rats.

Hypothesis

Standardized extract of *Centella asiatica* ECa 233 has ability to accelerate second degree burn wound healing in normal and diabetic rats.

Keywords

Centella asiatica / Second degree burn / Wound healing / Diabetic/ ECa 233

CHAPTER II

LITERATURE REVIEWS

2.1 The skin

The skin is one of the largest organs in the body. It has a surface area of 1.5 to 2 square meters, weighs approximately 4 kg (9 pounds) and receives about one-third of all blood circulating through the body. The skin is quite complex in structure and performs various functions essential for survival [26].

2.1.1 Structure of the skin

The skin is composed of three layers. The uppermost layer of the skin, which is composed of epithelium, is called the epidermis. The deeper layer is called the dermis and below the dermis is called the subcutaneous fat layer. The subcutaneous tissue, also called the superficial fascia or hypodermis, a layer of loose connective tissue and fatty tissue, binds the dermis to the underlying tissue of the body and supports the blood vessels and nerves that pass from the underlying tissues to the dermis (Figure 2.1) [26, 27].

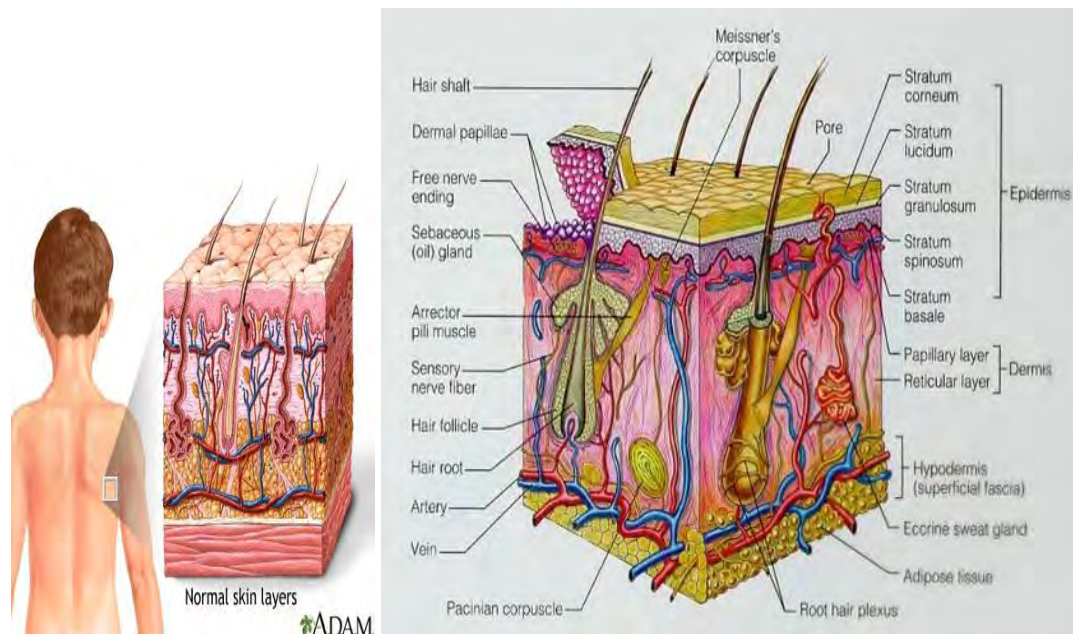


Figure 2.1 Structure of the skin [28, 29]

2.1.1.1 Epidermis

The outer surface of the skin is the epidermis, which is composed of stratified squamous epithelial cells. The epidermis covers the body, and it is specialized in areas to form the various skin appendages. The keratinocytes are the major cells of the epidermis. The functions of these cells are to produce a fibrous protein called keratin, which is essential to the protective function of skin. In addition to the keratinocytes, the epidermis has three other types of cells. Also in the basal cell layer are cells called melanocytes that produce a pigment called melanin, which is responsible for skin color, tanning and protecting against ultraviolet radiation. Merkel cells that provide sensory information and Langerhans (dendritic) cells, which are part of the immune system and help protect the body from foreign substances.

The epidermis is differentiated into five layers, from superficial to deep, the stratum corneum, the stratum lucidum, the stratum granulosum, the stratum spinosum and the stratum germinativum.

The deepest layer, the stratum germinativum or stratum basale, consists of cuboidal to columnar cells with the capability of continuing cell division. The basal cells are the only epidermal cells that are mitotically active. All cells of the epidermis arise from this layer. The second layer, the stratum spinosum is formed as cells from basal cell layer move upward toward the skin surface. The cells of this layer are commonly referred to as prickle cells because they develop a spiny appearance as their cell borders interact. The third layer, the stratum granulosum, is only a few cell thick. It is composed of flatter cells containing protein granules called keratohyalin granules. This compound is involved in the first step of keratin formation. The stratum lucidum, the fourth layer, is a thin, transparent layer mostly confined to the palms of the hands and soles of the feet. The top or surface layer of the epidermis is the stratum corneum. It is made up of stratified layers of dead keratinized cells that are constantly shedding. The stratum corneum contains the most cell layers and the largest cells of any zone of the epidermis [26, 27].

2.1.1.2 Dermis

Below the epidermis is the layer called the dermis. The dermis is the connective tissue layer that separates the epidermis from the subcutaneous fat layer. The two layers of the dermis, the papillary dermis and the reticular dermis are composed of cells, fibers, ground substances, nerves and blood vessels. The hair and glandular structures are embedded in this layer and continue through the epidermis.

The papillary dermis is a thin, superficial layer that lies adjacent to the epidermis. It consists of collagen fibers and ground substance. The reticular dermis is the thicker area of the dermis and forms the bulk of the dermal layer. The reticular dermis is characterized by a complex meshwork of three-dimensional collagen bundles interconnected with large elastic fibers and ground substance, a viscid gel that is rich in mucopolysaccharide [26, 27].

2.1.1.3 Hypodermis

The hypodermis (subcutaneous tissue) consists of loose connective and fatty tissues that lend support to the vascular and neural structures supplying the outer layers of the skin. Also within the hypodermis are the coiled ducts of sweat glands and the base of hair follicles. The fat stored in this layer represents an energy source for the body and helps to insulate the body against changes in the outside temperature [26, 27].

2.1.2 Function of the skin

The functions of the skin are to protect the body from sunlight, heat, chemicals, water loss, injury or microorganisms, help to control body temperature, synthesis of vitamin D and help to sense pain and other stimuli [26, 27].

2.2 Hair follicle

Hair follicles are appendages of the skin and represent complex and dynamic three-dimensional structures (Figure 2.2) [30, 31]. The hair follicle is composed of epidermal (epithelial) and dermal (mesenchymal) compartments and their interaction plays an important role in the morphogenesis and growth of the hair follicle [32, 33]. The term pilosebaceous unit describes the integrated structure of the hair follicle, hair shaft, adjoining arrector pili muscle and associated sebaceous gland [34]. The hair shaft is composed of the medulla, the cortex with melanosomes, and the cuticula, which is represented by flat cornified cells that are arranged similar to roof tiles [31].

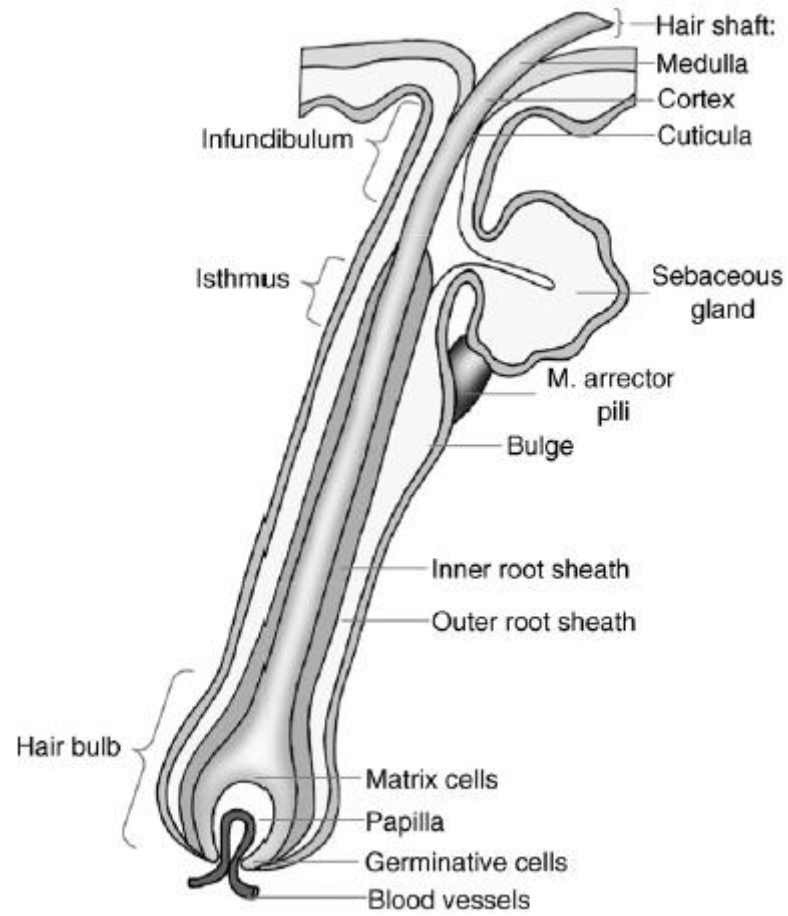
The structure of the human hair follicle can be divided in the following manner:

- The infundibulum, describing the part between the skin surface to the point of the sebaceous gland duct opening to the hair canal.
- The isthmus, representing the part between the sebaceous gland duct opening and the bulge region where the stem cells [35] as well as the skin mast cell precursors [36] are supposed to mainly be located.
- The suprabulbar zone, where various layers of anagen follicles begin to differentiate and can be easily identified as this level.
- The hair bulb with the dermal papilla connected to the blood vessels [37].

2.2.1 The Hair cycle

Hair follicles undergo a growth cycle including three major phases:

- The anagen is the active growth phase of hair follicle. The cells proliferate rapidly and continuously to form the inner root sheath, and migrate upward to form the hair shaft.
- The catagen phase is a short transition stage that occurs at the end of the anagen phase. It signals the end of the active growth of a hair.
- The telogen phase is the resting phase of the hair follicle. The club hair is the final product of a hair follicle in the telogen stage, and is a dead, fully keratinized hair [34].



Drug Discovery Today: Disease Mechanisms

Figure 2.2 Morphology of the human hair follicle [31]

2.2.2 Hair follicle and wound healing

The most obvious function of a hair follicle is to produce a hair fiber, but it has long been noted that follicles also contribute to healing of injured skin. Wounds that remove the surface epidermis but leave hair follicles relatively intact are reepithelialized simultaneously across the entire wound, with patches of new epidermis seen spreading outwards from the necks of the hair follicles. In contrast, deep wounds that destroy the hair follicles are slower to heal and do so only from the margins. Identification of these different healing modes has led to a realization that wound depth is critical when treating burn cases, with shallow wounds left to reepithelialize of their own accord, while deep wounds typically receive grafts of surface epidermis from uninjured sites [10].

Epidermal stem cells from the hair follicle are now thought to originate from the hair bulge that is believed to be the germinative portion of the hair and serve as a reservoir for keratinocytes in wound healing [38].

A major component of the wound healing process is the restoration of an epidermal barrier by growth and migration of the continuous epithelial sheets adjacent to the wound and by emigration of hair follicle cells to the skin surface [39].

The role of hair follicle stem cells in healing, Langton, Herrick and Headon (2008) developed a novel mutant mouse model (*Edaradd* mouse) that, as a result of defects in hair follicle development, lacks primary hair follicles. The tail region of these mice proved especially interesting, because it lacked all adnexal structures. In analyzing stem cell behavior in embryonic skin, the result found clonogenic keratinocytes to be relatively plentiful in the ectoderm prior to hair follicle formation. However, their frequency in the interfollicular epidermis dropped sharply by birth, when the majority of stem cells were located within hair follicles. Results from this study demonstrate that the acute wound healing response is delayed in the absence of hair follicles. Using a linear incision model, the wounds in wild-type skin closed steadily from 3 to 6 days after wounding, whereas the wounds in mutant skin (with no hair follicles) showed no closure up to day 4 but recovered to match wild-type skin by day 6 [40]. This latter event suggests that the epidermis can compensate for loss of follicles by calling on its vast proliferative potential. Thus in the absence of hair follicle input there is

an acute delay in wound re-epithelialization from which the epidermis recovers to cover the damaged region. The investigators found that in the absence of hair follicles wounds would heal with an acute delay in re-epithelialization, followed by expansion of the region of activated epidermis beyond that seen in normal haired skin, but resulting in appropriate wound closure.

Hair follicles provide a measurable contribution to the rate of re-epithelialization from a wound margin, but this input is not essential for the healing of incisional wounds. It is possible, however, that severe wounds requiring massive epidermal repair would require hair follicle stem cells to produce epidermis over an extended healing period. In addition to accelerating in growth at epidermal leading edges, evenly spaced hair follicles provide islands of epidermal repair capacity in case of destruction limited to the surface epithelium. It is likely that their scattered distribution, in addition to any intrinsically superior repair ability, makes hair follicle-derived cells such important agents in healing burn wounds.

2.3 The wound and wound healing

2.3.1 Definition of wound

A wound is defined as the loss of continuity of epithelium with or without the loss of underlying connective tissue (including muscle, bone and nerves), following injury. The injury may follow direct violence or be inflicted by non-mechanical injury, which may also be responsible for delay in healing. Extensive tissue damage such as contusion or hematoma could occur with minimal tissue loss [41].

2.3.2 Types of wounds

2.3.2.1 Incision or incised wound

Incised wounds involve injury with no tissue loss and minimal tissue damage. There are two types, surgical incision and non-surgical wound.

1. Surgical incisions cause minimal tissue damage. They are made with precision in an environment where aseptic and antiseptic techniques reduce the risk of infection, with the best of instruments and the facility to control hemostasis.

2. Penetrating, non-surgical wounds are caused by injuries inflicted by a knife or other sharp instrument. Penetrating trauma may involve minimal damage to skin and connective tissue, though deeper damage to vessels, nerves, and internal organs may occur [42, 43].

2.3.2.2 Laceration

Lacerations are caused when trauma exceeds intrinsic tissue strength for example, skin torn by blunt injury over a bony prominence such as the scalp. Tissue damage may not be extensive, and primary suturing may be possible. Sterile skin closure strips may be appropriate in some circumstances for example, in pretibial laceration, as suturing causes increased tissue tension, with the swelling of early healing and inflammation leading to more tissue loss [42, 43].

2.3.2.3 Abrasion

An abrasion is a scrape or graze. Typically, there is a superficial surface wound involving the epidermis and part of the dermis. As dermal nociceptors are exposed in the damaged dermis, these wounds are often very painful. Abrasions are most commonly caused by friction injuries, falling off bikes is a common cause. When extensive, plasma and/or blood loss similar to a burn can result from serious abrasions [42, 43].

2.3.2.4 Contusion

A contusion is more commonly called a bruise. It is usually caused by a blunt, the overlying skin is unbroken and is characterized by damage to blood vessels and extravasation of blood into tissues [42, 43].

2.3.2.5 Ulcer

An ulcer defined as a loss of an epithelial surface together with a variable degree of underlying connective tissue [42, 43].

2.3.3 Wound healing

Wound healing is a physiologic process of regenerating dermal and epidermal tissue. It is a complex process that can be divided into 4 overlapping phases of hemostasis, inflammation, proliferation and remodeling. The first stage, hemostasis, occurs immediately at the time of injury and is usually completed within hours. The second stage, inflammation, begins shortly after hemostasis and is usually completed within the first 24 to 72 hours after injury [44]. However, it may last as long as 5 to 7 days after injury. The third stage of proliferation and repair typically occurs 1 to 3 weeks after injury. The fourth and final stage, remodeling, begins approximately 3 weeks after injury and may take anywhere from months to several years to achieve physiologic completion [42, 45, 46].

2.3.3.1 Stage 1 : Hemostasis

Tissue injury provokes immediate activation of the extrinsic and intrinsic coagulation pathways. Within minutes of injury, platelet activation products and intense vasoconstriction lead to clot formation with hemostasis. Vasodilation and an increase in capillary permeability follows, possibly as a result of release of histamine from activated platelets. This allows serum rich in proteins such as fibronectin, fibrinogen and fibrin to leak into the interstitial space, where these combine with the clot to produce a fibrin plug that temporarily closes the wound. Cytokines and growth factors from inflammatory cells recruited later generate the correct environment to create a scaffold within the fibrin plug on which tissue repair can occur [47].

2.3.3.2 Stage 2 : Inflammation

The second stage of wound healing is inflammation. The inflammatory response is triggered by a variety of mediators released from injured tissue cells and capillaries, activated platelets and their cytokines and the by-products of hemostasis. Neutrophils are the next predominant cell marker in the wound within 24 hours after injury. The major function of the neutrophil is to remove foreign material, bacteria and non-functional host cells and damaged matrix components that may be present in the wound site [48, 49]. Bacteria give off chemical signals, attracting neutrophils, which ingest them by the process of phagocytosis [50].

The mast cell is another marker cell of interest in wound healing. Mast cells release granules filled with enzymes, histamine and other active amines and these mediators are responsible for the characteristic signs of inflammation around the wound site [51]. The active amines released from the mast cell, causes surrounding vessels to become leaky and thus allow the speedy passage of the mononuclear cells into the injury area. In addition fluid accumulates at the wound site and the characteristic signs of inflammation begin. The signs of inflammation have been well recognized since ancient times: *rubor* (redness), *calor* (heat), *tumor* (swelling) and *dolor* (pain).

By 48 hours after injury, fixed tissue monocytes become activated to become wound macrophages. These specialized wound macrophages are perhaps the most essential inflammatory cells involved in the normal healing response. Inhibition of macrophage function will delay the healing response. Once activated these wound macrophages also release PDGF (platelet-derived growth factor) and TGF- β (Transforming growth factor- β) that further attracts fibroblasts and smooth muscle cells to the wound site. These highly phagocytic macrophages are also responsible for removing nonfunctional host cells, bacteria-filled neutrophils, damaged matrix, foreign debris and any remaining bacteria from the wound site. The presence of wound macrophages is a marker that the inflammatory phase is nearing an end and that the proliferative phase is beginning [50].

2.3.3.3 Stage 3 : Proliferation and Repair

The proliferative phase is characterized by angiogenesis, collagen deposition, granulation tissue formation, re-epithelialization and wound contraction [52].

Angiogenesis or Neovascularization

The process of restoring the vascular network is called neovascularization or angiogenesis. Angiogenesis is a critical process in healing at sites of injury, in the development of collateral circulations at sites of ischemia, and in allowing tumors to increase in size beyond the constraints of their original blood supply.

The main steps that occur in angiogenesis from pre-existing vessels are listed below.

- Vasodilation in response to nitric oxide and increased permeability of the preexisting vessel induced by vascular endothelial growth factor (VEGF)
- Migration of endothelial cells toward the area of tissue injury
- Proliferation of endothelial cells just behind the leading front of migrating cells
- Inhibition of endothelial cell proliferation and remodeling into capillary tubes

- Recruitment of periendothelial cells (pericytes for small capillaries and smooth muscle cells for larger vessels) to form the mature vessel

As mentioned, bone marrow endothelial precursor cells may also contribute to angiogenesis. The nature of the homing mechanism by which endothelial precursor cells located in the bone marrow migrate into sites of injury is unknown. These cells may participate in the replacement of lost endothelial cells, in the re-endothelialization of vascular implants, in the neovascularization of cutaneous wounds and ischemic tissues, and in tumor development.

Several factors induce angiogenesis, but the most important are vascular endothelial growth factor (VEGF) and basic fibroblast growth factor (bFGF).

In angiogenesis originating from preexisting local vessels, VEGF stimulates both proliferation and motility of endothelial cells, thus initiating the process of capillary sprouting. In angiogenesis involving endothelial cell precursors from the bone marrow, VEGF acts through VEGFR-2 to mobilize these cells from the bone marrow and to induce proliferation and motility of these cells at the sites of angiogenesis. bFGF participates in angiogenesis mostly by stimulating the proliferation of endothelial cells. It also promotes the migration of macrophages and fibroblasts to the damaged area, and stimulates epithelial cell migration to cover epidermal wounds [53].

Re-epithelialization

As the proliferative phase progresses, the process of epithelization is stimulated by the presence of EGF (epidermal growth factor) and TGF- α (transforming growth factor alpha) that are produced by activated wound macrophages, platelets and keratinocytes [54]. Keratinocytes migrate to cover the surfaces of the skin defect. The keratinocytes proliferate and migrate across the wound. Once migration is complete, the keratinocytes stabilize themselves by forming firm attachments to each other and the new basement membrane [55, 56]. The skin surface is completely covered with new epidermal cells, the wound is closed.

Granulation

The third and final mechanism of proliferation and repair is the development of granulation tissue. Granulation tissue, a transitional substance that replaces the fibrin/fibronectin matrix, begins to appear about 4 days after injury [55, 57]. Granulation occurs as the fibrin clot scaffold is replaced with new tissue rich in hyaluronan (hyaluronic acid), fibronectin, and other ECM compounds. Because granulation tissue is very active metabolically and supports the proliferation of a variety of cells and proteins, it is also highly vascular. This accounts for its classic pinkish-red appearance.

The predominant cell type found in granulation tissue is the fibroblast. Fibroblasts are dermal cells that produce collagen and numerous other substances that comprise the extracellular matrix (ECM). The structure and composition of granulation tissue undergoes constant change as it matures. Although collagen becomes the predominant protein, there are at least 19 different types of collagen. The type of collagen present in a tissue varies with the tissue. For example, skin collagen is 80% type I and 20% type III.

The new granulation tissue contains type I, III, and V collagen fibers. Thirty percent of the collagen is type III collagen, which does not contribute to restoring tensile strength in the wound. At 3 weeks after injury, the healing wound has approximately 20% of its final strength [57, 58].

2.3.3.4 Stage 4 : Remodeling

The final stage of wound healing is remodeling or maturation of the granulation tissue into mature connective tissue and/or scar. The wound also develops its final strength during this stage of wound healing. The key cells for remodeling are macrophages and fibroblasts. Extracellular matrix (ECM) reshaping by cross-linking collagens, cell maturation, and program cell death or apoptosis are the mechanisms used in wound remodeling. Collagen synthesis peaks around 5 days after injury but continues for weeks or months. During this time, collagen and ECM tissue continue to be deposited into the wound, whereas the developing connective tissue is reshaped by cell

maturation and apoptosis. Although wound strength increases, in fact the maximum tensile strength that a wound can ever achieve is approximately 80% of normal skin [39, 45, 58].

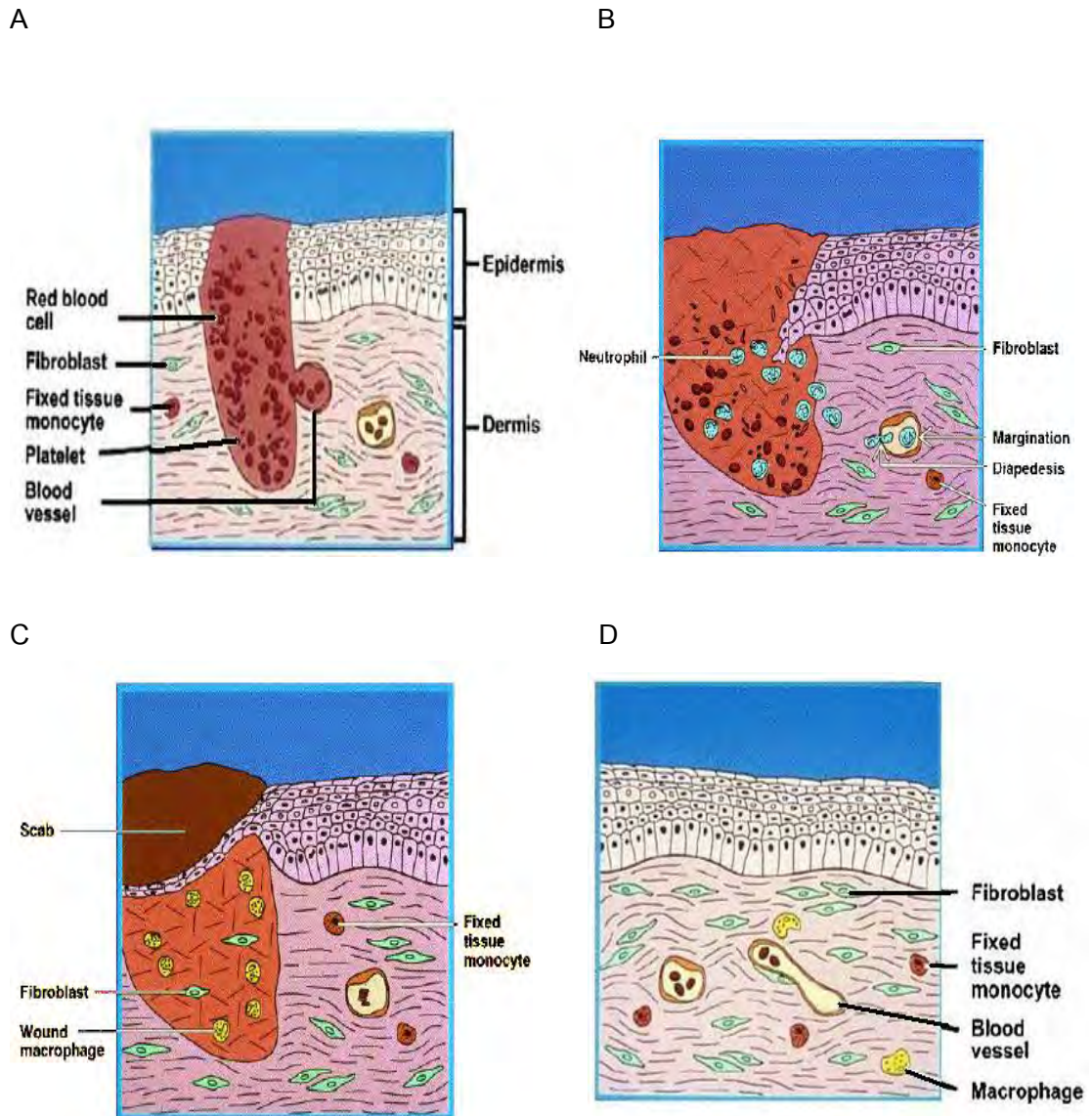


Figure 2.3 The wound healing A : At the time of injury, the tissue is disrupted and the platelets adhere to the exposed collagen and to each other. B : By the first day following injury, neutrophils attach to endothelial cells in the vessel walls surrounding the wound, then change shape to move through the cell junctions and migrate to the wound site. This is the beginning of the inflammatory phase. C: The inflammatory phase continues as fixed tissue macrophages become active and move into the site of injury and transform into very active wound macrophages. These highly phagocytic cells also release PDGF and TGF- β to recruit fibroblasts to the site and thus begin the proliferative phase. D: The remodeling phase is characterized by continued synthesis and degradation of the extracellular matrix components trying to establish a new equilibrium [39].

2.3.4 Types of wound healing

2.3.4.1 Healing by first intention

The least complicated example of wound repair is the healing of a clean, uninfected surgical approximated by surgical sutures. This is referred to as primary union or healing by first intention. The incision causes death of a limited number of epithelial and connective tissue cells as well as disruption of epithelial basement membrane continuity. The narrow incisional space immediately fills with clotted blood containing fibrin and blood cells ; dehydration of the surface clot forms the well-known scab that covers the wound. The healing process follows a series of sequential steps :

Within 24 hours, neutrophils appear at the margins of the incision, moving toward the fibrin clot. Within 24 to 48 hours, epithelial cells from both edges have begun to migrate and proliferate along the dermis, depositing basement membrane components as they progress. They fuse in the midline beneath the surface scab, producing a continuous but thin epithelial layer that closes the wound.

By day 3, neutrophils have been largely replaced by macrophages. Granulation tissue progressively invades the incision space. Collagen fibers are now present in the margins of the incision, but at first these are vertically oriented and do not bridge the incision. Epithelial cell proliferation thickens the epidermal layer.

By day 5, the incisional space is filled with granulation tissue. Neovascularization is maximal. Collagen fibrils become more abundant and begin to bridge the incision. The epidermis recovers its normal thickness, and differentiation of surface cells yields a mature epidermal architecture with surface keratinization.

During the second week, there is continued collagen accumulation and fibroblast proliferation. The leukocyte infiltrate, edema and increased vascularity are substantially diminished. At this time, the long process of blanching begins, accomplished by increased accumulation of collagen within the incisional scar, accompanied by regression of vascular channels.

By the end of the first month, the scar is made up of a cellular connective tissue devoid of inflammatory infiltrate, covered now by intact epidermis.

However, the dermal appendages destroyed in the line of the incision are permanently lost. Tensile strength of the wound increases thereafter, but it may take months for the wounded area to obtain its maximal strength [53].

2.3.4.2 Healing by second intention

When there is more extensive loss of cells and tissue, such as in large wounds, burn wound, abscess formation, and ulceration, the repair process is more complex, as is also the case after infarction in parenchymal organs. In secondary intention healing, also known as healing by secondary union, the inflammatory reaction is more intense, there is abundant development of granulation tissue, and the wound contracts by the action of myofibroblasts. This is followed by accumulation of extracellular matrix (ECM) and formation of a large scar.

Secondary healing differs from primary healing in several aspects :

- A larger clot or scab rich in fibrin and fibronectin forms at the surface of the wound.
- Inflammation is more intense because large tissue defects have a greater volume of necrotic debris, exudate and fibrin that must be removed. Consequently, large defects have a greater potential for secondary inflammation-mediated injury.
- Much larger amounts of granulation tissue are formed. Larger defects require a greater volume of granulation tissue to fill in the gaps and provide the underlying framework for the regrowth of tissue epithelium. A greater volume of granulation tissue generally results in a greater mass of scar tissue.
- Secondary healing involves wound contraction. Within 6 weeks, for example, large skin defects may be reduced to 5-10% of their original size, largely by contraction. This process has been ascribed to the presence of myofibroblasts, which are modified fibroblasts exhibiting many of the ultrastructural and functional features of contractile smooth muscle cells [53].

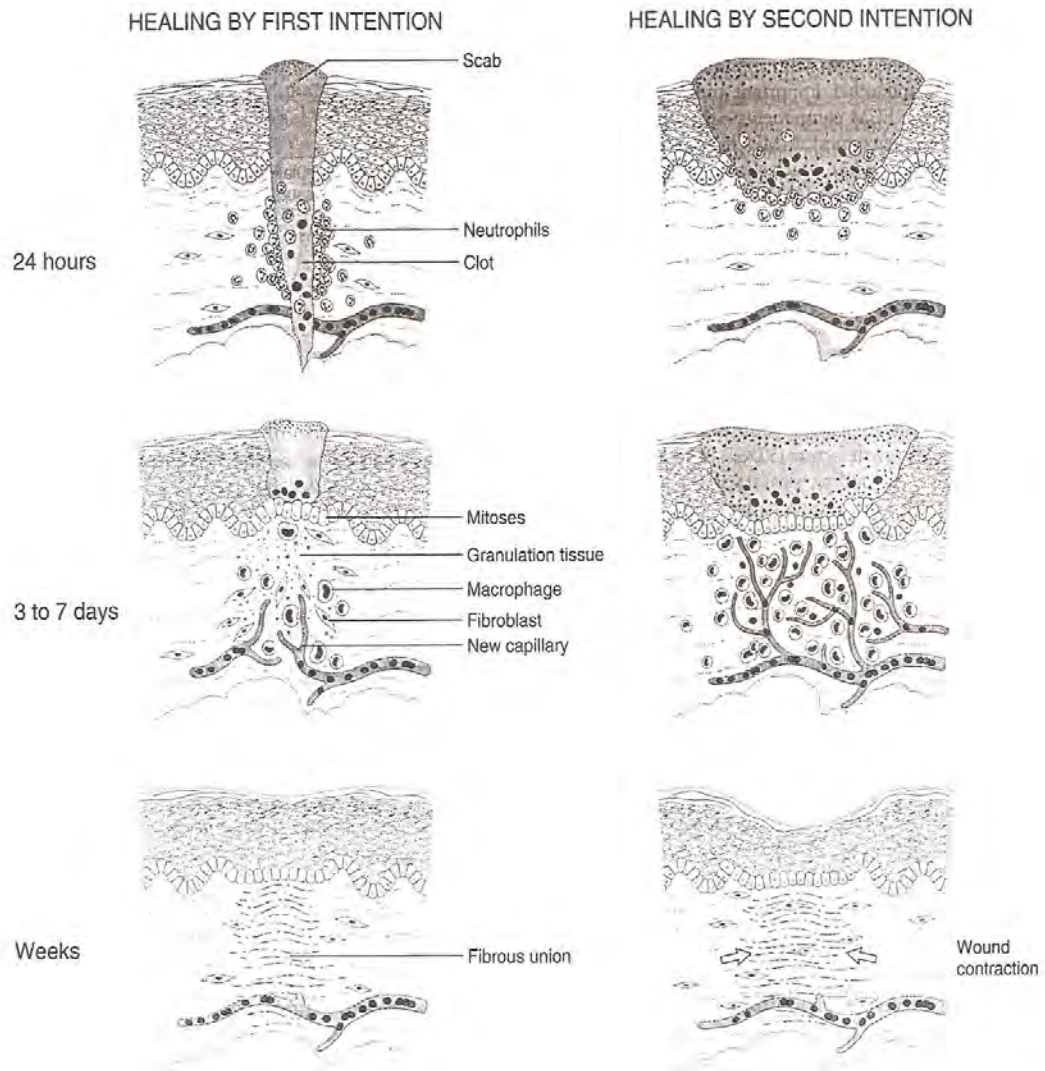


Figure 2.4 Steps in wound healing by first intention (left) and second intention (right). Note large amounts of granulation tissue and wound contraction in healing by second intention [53].

2.4 Local and systemic factors that influence wound healing

Healing is modified by a number of known influences and some unknown ones, frequently impairing the quality and adequacy of both inflammation and repair. These influences include both systemic and local host factors. Systemic factors include the following :

- Nutrition has profound effects on wound healing. Protein deficiency, for example, and particularly vitamin C deficiency, inhibit collagen synthesis and delay healing.

- Metabolic status can change wound healing. Diabetes mellitus, for example, is associated with delayed healing, as a consequence of the microangiopathy that is a frequent feature of this disease.

- Circulatory status can modulate wound healing. Inadequate blood supply, usually caused by arteriosclerosis or venous abnormalities e.g. varicose veins that delay venous drainage, also impair healing.

- Hormones, such as glucocorticoids, have well-documented anti-inflammatory effects that influence various components of inflammation. These agents also inhibit collagen synthesis.

Local factors that influence healing include the following :

- Infection is the single most important cause of delay in healing because it results in persistent tissue injury and inflammation.

- Mechanical factors, such as early motion of wounds, can delay healing, by compressing blood vessels and separating the edges of the wound.

- Foreign bodies, such as unnecessary sutures or fragments of steel, glass, or even bone, constitute impediment to healing.

- Size, location, and type of wound influence healing. Wounds in richly vascularized areas, such as the face, heal faster than those in poorly vascularized ones, such as the foot. Small injuries heal faster and with less scar formation than large excisional wounds or wounds caused by blunt trauma [53].

2.5 The burn wound and wound healing

2.5.1 Definition of a burn

A burn is an injury caused by a pathologic flux of energy within a tissue resulting in a disruption of functional integrity. The source of the energy may be thermal, chemical, electrical, or radiation. The spectrum of burn injury ranges from an inconsequential superficial burn to the fatal destruction of the entire body surface [59].

2.5.2 Types of burns

2.5.2.1 Thermal burns

The local thermal wound is the result of heat necrosis of cells. The content of cellular destruction depends on several factors: the intensity of heat tissue involved. The conductance of the tissue involved determines the rate of dissipation or absorptions of heat and depends upon several factors. These include the peripheral circulation, water content of the tissue, thickness of the skin and its pigmentation, the presence or absence of external insulting substances such as hair and skin oil. Of these factors perhaps the most important in determining the degree of injury is the peripheral circulation. The rate of blood flow through the heat exposed tissues can be altered rapidly. This mechanism is of major importance in determining the amount of cellular destruction associated with the transfer of heat to the tissue. Thermal burns may be subdivided into flame burns, flash burns, scald burns and contact burns [9].

2.5.2.2 Electrical burns

Electrical injuries result from the heat produced by the flow of electrical current through the resistance of body tissues. Factors of primary importance in determining the effect of the passage of an electric current through the human body include the type of circuit, voltage, amperage, resistance of the tissues involved, the path of the current through the body and duration of contact with the current. The chief

reason for considering these wounds as a category distinct from the more common thermal burn is the volume of tissue that is often involved in high voltage electrical injuries [9].

2.5.2.3 Chemical burns

A wide variety of agents may be responsible for chemical burns. The majority of chemical agents produce skin destruction through chemical reactions rather than hyperthermic injury. Included among these reactions are coagulation of protein by reduction, corrosion, oxidation, formation of salts, poisoning of protoplasm and desiccation. Acids promote collagen denaturation and subsequent degradations. Heat production is often a by-product of the chemical reactions with tissues and may worsen the injury [9].

2.5.2.4 Radiation burns

Radiation burns damaged organ tissue by excessive exposure to ultraviolet light, radiation therapy and X-rays [9].

2.5.3 Pathophysiology of thermal burns

2.5.3.1 Local and systemic response

The local and systemic inflammatory response to thermal injury is extremely complex, resulting in both local burn tissue damage and deleterious systemic effects on all other organ systems distant from the burn area itself.

The pathophysiological changes in the burn wound are characterized by effects caused by heat *per se* and superimposed on these is a pronounced acute inflammatory process. A sudden increase in body surface temperature results in prompt local responses by the blood vessels in the area in an attempt to dissipate heat by vasodilatation. A further increase in tissue temperature starts an inflammatory reaction caused by local release of inflammatory mediators and cascades of reactions then take

place. The inflammatory responses to injury, infection and antigen challenge with overproduction of chemical mediators, activation of leukocytes and endothelial cells and an alteration in circulating cytokines may all contribute to systemic effects. Thus in patients with major burns these effects increased susceptibility to infection, the systemic inflammatory response syndrome (SIRS), adult respiratory distress syndrome (ARDS) and multiple organ dysfunction syndrome (MODS), which may develop further into progressive organ failure and death [60].

2.5.3.2 Burn wound change over time

Usually the burn wound initially has different depths in different regions. Often the wound is characteristically made up of several zones of tissue damage due to different heat transfer. In the middle, usually the site of greatest heat transfer, irreversible skin death occurs, the zone of coagulation. This zone is surrounded by the zone of stasis, characterized by a pronounced inflammatory reaction. This potentially salvageable area could be converted to full destruction by infection or drying of the wound. Outermost is the zone of hyperemia, which is the site of minimal cell involvement and early spontaneous recovery

A number of distinctive phases over time postburn, mainly in the zone of stasis, can be discerned:

1. A period of rapid local edema formation with a maximum at about 1-3 h postburn due to vasodilatation, increased extravascular osmotic activity and increased microvascular permeability. A rapid degradation of hyaluronate and collagen fibers may be the reason for the increased extravascular osmotic activity behind the dramatic early drop in the interstitial fluid hydrostatic pressure. The initial suction of fluid out into the interstitium due to this so-called imbibition pressure is then further accentuated by fluid leakage due to increased microvascular permeability.

2. These changes are followed by heterogeneous reductions in perfusion, the so-called no reflow phenomenon leading to local tissue ischemia and further necrosis. The microcirculation is compromised to the worst extent at around 12-

24 h postburn. During this period of time attempts to improve the microcirculation by pharmacological treatment have, to some extent been, successful.

3. A period of transformation favoring adhesion on the free surfaces of endothelial cells, platelets and leukocyte. This leads to leukocyte margination followed by extravasation and their migration to the injured parenchymal cells and microorganisms. Platelets removed from the circulation contribute at different levels to hemostasis and local thrombosis.

4. A later phase of wound repair with high rates of wound perfusion to support wound metabolic requirements and maintain adequate defense against invasive burn wound infections.

5. Burn wound microbial colonization and infection. The burn wound surface is generally considered to be initially free of major microbial contamination. Gram-positive bacteria in the depths of hair follicles and sweat glands may, however, survive the heat of the initial injury. These bacteria may heavily colonize the wound within the first 48 h postburn, especially if topical chemotherapy is not applied. Coincident with improvements in survival, changes in the epidemiology of infection have occurred. The microorganisms present in the wounds of hospitalized patients change with time after injury. Usually gram-positive organisms (*Staphylococcus aureus*, *Streptococcus pyogenes*) during the first week postburn are superseded by gram-negative organisms (*Pseudomonas aeruginosa*, *Escherichia coli*) during the second week. Sometimes candida species (*Candida albicans*, *Aspergillus*, *Phycomyces*) are detected later [60].

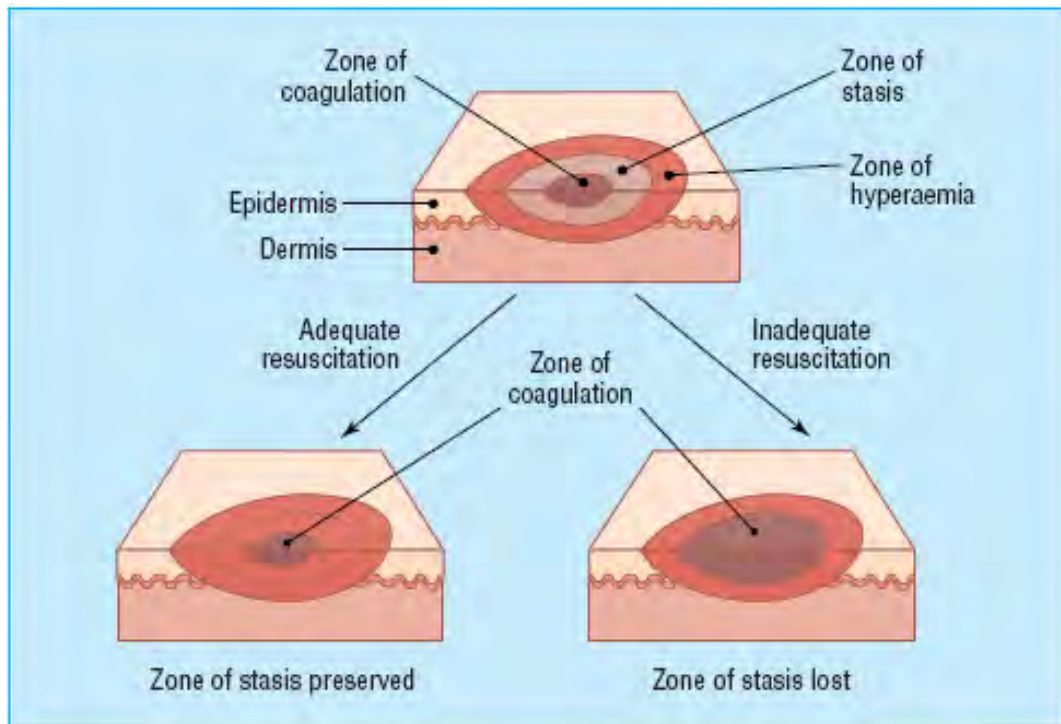


Figure 2.5 Jackson's burn zone (1994) : **Zone of coagulation** : This occurs at the point of maximum damage. In this zone there is irreversible tissue loss due to coagulation of the constituent protein. **Zone of stasis** : The surrounding zone of stasis is characterized by decreased tissue perfusion. The tissue in this zone is potentially salvageable. The main aim of burns resuscitation is to increase tissue perfusion here and prevent any damage becoming irreversible. Additional insults-such as prolonged hypotension, infection, or edema can convert this zone into an area of complete tissue loss. **Zone of hyperemia** : In this outermost zone tissue perfusion is increased. The tissue here will invariably recover unless there is severe sepsis or prolonged hypoperfusion [61].

2.5.4 Classification of burn depth

Burns are typically classified according to the depth of involvements as first-degree, second-degree and third-degree burns. The depth of a burn is largely influenced by the duration of exposure to the heat source and temperature of the heating agent.

Burns are classified into two groups by the amount of skin loss. Partial thickness burns do not extend through all skin layers, whereas full thickness burns extend through all skin layers into the subcutaneous tissues. Partial thickness burns can be further divided into superficial, superficial dermal, and deep dermal [26, 61].

2.5.4.1 First-degree burns (superficial burns)

First-degree burns involve only the outer layers of the epidermis. They are red or pink, dry and painful. There are usually no blister formation. A mild sunburn is an example. The skin maintains its ability to function as a water vapor and bacterial and heals in 3 to 10 days. First-degree burns usually require only palliative treatment, such as pain relief measures and adequate fluid intake [26, 61].

2.5.4.2 Second-degree burns

Second-degree burns involve both epidermis and dermis.

2.5.4.2.1 Second-degree burns (superficial partial-thickness burns)

Second-degree burns (superficial partial-thickness burns) involve the epidermis and various degrees of the dermis. They are painful, moist, and blistered. Underneath the blisters is weeping, bright pink or red skin that is sensitive to temperature changes, air exposure, and touch. The blister prevent the loss of body water and superficial dermal cells. It is usually important to maintain intact blisters after injury because they serve as a bandage and may help promote wound healing. These burns heal in approximately 1 to 2 weeks [26, 61].

2.5.4.2.2 Second-degree burns (deep partial-thickness burns)

Second-degree burns (deep partial-thickness burns) involve the entire epidermis and dermis. Structures that originate in the subcutaneous layer, such as hair follicles and sweat glands, remain intact. These burns can be very painful because the pain sensors remain intact. Tactile sensors may be absent or greatly diminished in the areas of deepest destruction. These burns appear as mottled pink, red, or waxy white areas with blisters and edema. The blisters resemble flat, dry tissue paper, rather than the bullous blisters seen with superficial partial-thickness injury. After healing, in approximately 1 month, these burns maintain their softness and elasticity, but there may be a loss of some sensation. Scar formation is usual. These burns require supportive medical care aimed at preventing further tissue damage, providing adequate hydration, and ensuring that the granular bed is adequate to support re-epithelialization [26, 61].

2.5.4.3 Third-degree burns (full thickness burns)

Third-degree burns (full thickness burns) extend into the subcutaneous tissue and may involve muscle and bone. Thrombosed vessels can be seen under the burned skin, indicating that the underlying vasculature is involved. Third-degree burns vary in color from waxy white or yellow to tan, brown, deep red, or black. These burns are hard, dry, and leathery. Edema is extensive in the burn area and surrounding tissues. There is no pain because the nerve sensors have been destroyed [26, 61].

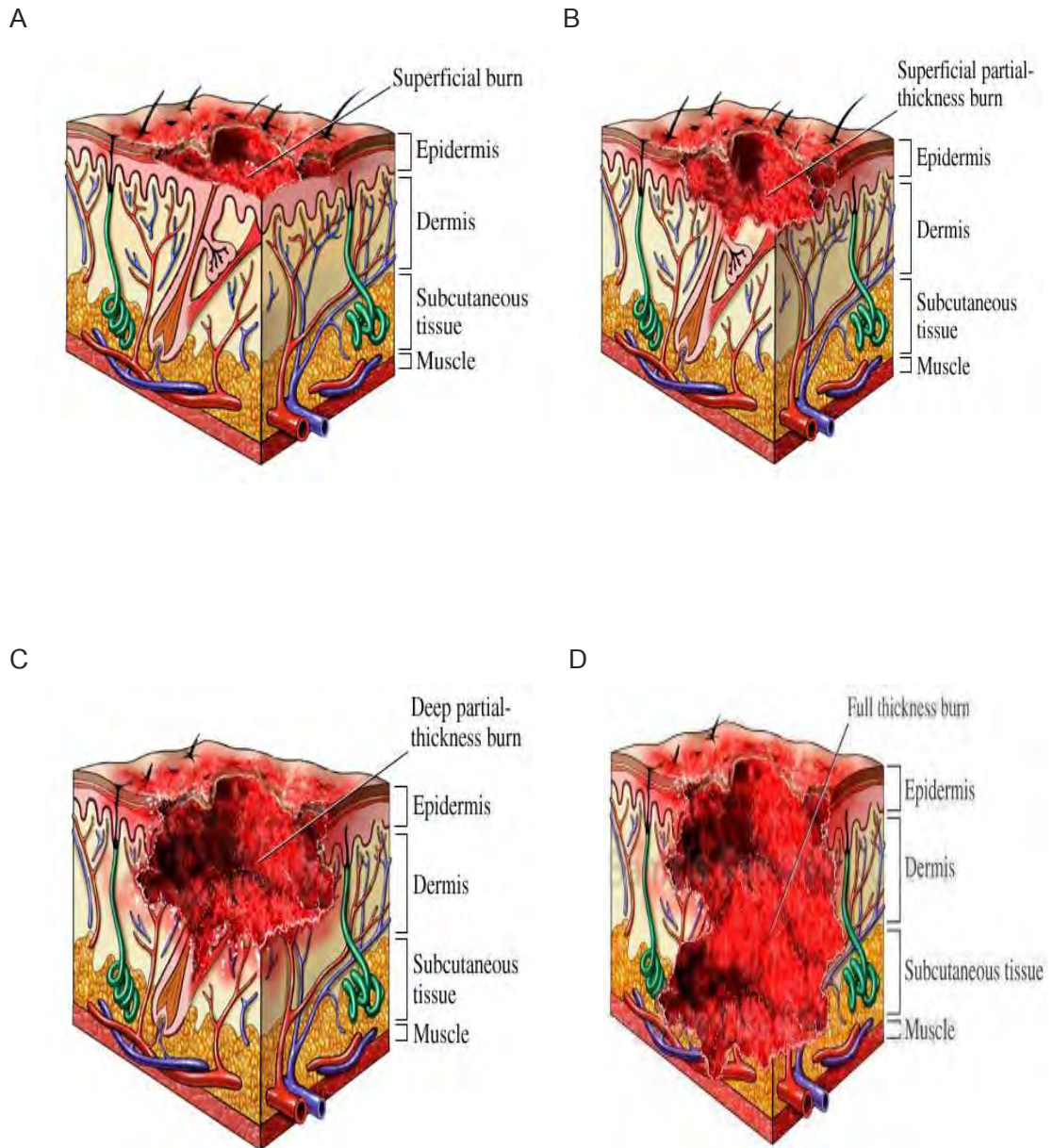


Figure 2.6 Classification of burn depth A : First-degree burns (superficial burns)

B : Second-degree burns (superficial partial-thickness burns) C : Second-degree burns (deep partial-thickness burns) D : Third-degree burns (full thickness burns) [62]

2.5.5 Assessment of burn area

Assessment of burn area, even by those who are expert at it. There are three commonly used methods of estimating burn area, and each has a role in different scenarios. When calculating burn area, erythema should not be included. This may take a few hours to fade, so some overestimation is inevitable if the burn is estimated acutely [61].

2.5.5.1 Palmar surface

The surface area of a patient's palm (including fingers) is roughly 0.8% of total body surface area. Palmar surface can be used to estimate relatively small burns (< 15% of total surface area) or very large burns (> 85%, when unburnt skin is counted). For medium sized burns, it is inaccurate.

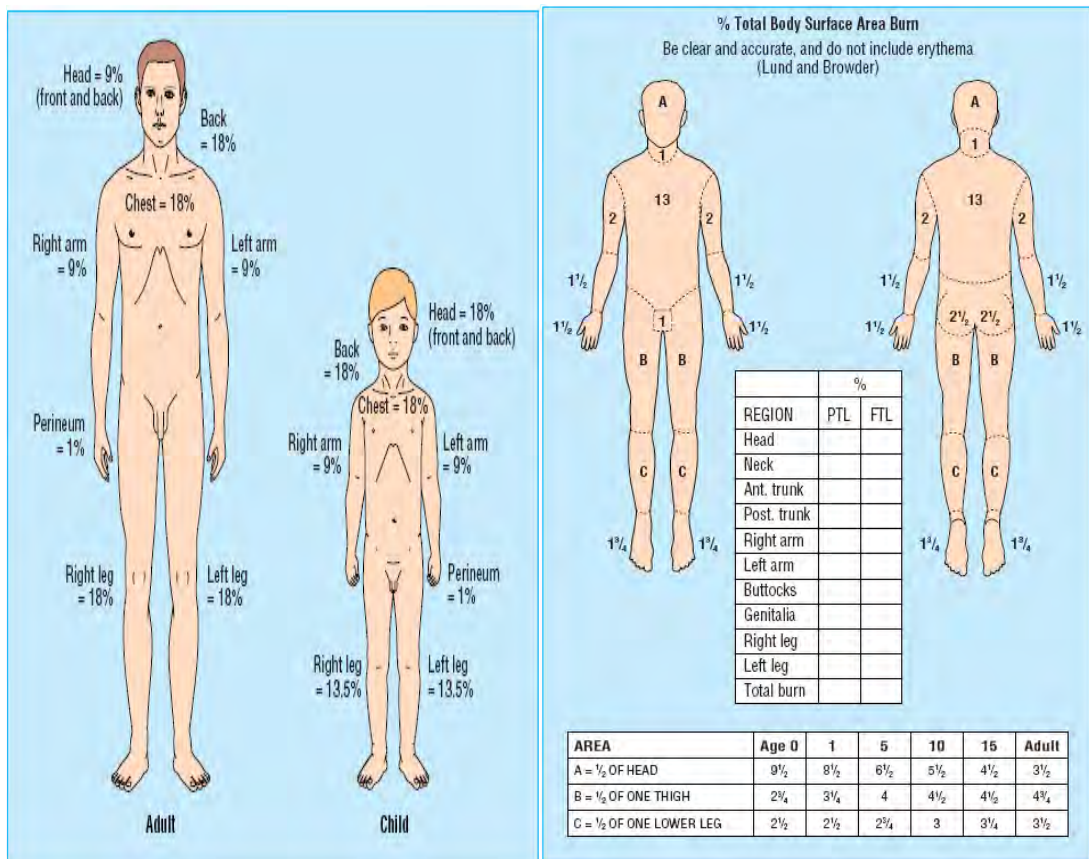
2.5.5.2 Wallace rule of nines

This is a good, quick way of estimating medium to large burns in adults. The body is divided into areas of 9%, and the total burn area can be calculated. It is not accurate in children.

2.5.5.3 Lund and Browder chart

This chart, if used correctly, is the most accurate method. It compensates for the variation in body shape with age and therefore can give an accurate assessment of burns area in children. It is important that all of the burn is exposed and assessed. During assessment, the environment should be kept warm, and small segments of skin exposed sequentially to reduce heat loss. Pigmented skin can be difficult to assess, and in such cases it may be necessary to remove all the loose epidermal layers to calculate burn size.

There are many factors involved in burns that must be observed in an assessment. Depth extension and burn localization, victim's age, existence of previous disease, concomitance of aggregating considered when assessing burn.



A

B

Figure 2.7 A : Wallace rule of nines to estimate extent of burn injury by percentage

B : Lund and Browder chart is useful in assessing the extent of burn injury (the relative proportions of body areas differ in children) [61]

2.5.6 Burn wound healing

The burn wound is thought as the pivotal factor mediating many local and systemic disturbances that characterize burn injury. These include fluid and protein loss, local and systemic sepsis, gross metabolic, endocrine, hematological and immune disturbances and the major cause of the morbidity and mortality associated with burn injury. The initial local effect of a burn is that of tissue damage and destruction. It is suggested that the local effect could be divided into several zones of differential damage and blood flow as the zone of coagulation, the zone of stasis and the zone of hyperemia and if the burn wound is large enough the entire body becomes a zone of edema [9, 63].

Regeneration is the capacity of a tissue to renew itself so that the end result is indiscernible from the preinjured tissue. It is a feature seen in superficial partial-thickness burns. The injury involves the loss of epidermis and basement membrane and the papillary dermis. There may be a highly exudative and painful wound. The exudative phase persists for several days and as it decreases, the nature of the exudates changes. The viscosity and relative protein content increase and eventually a fibrin layer seals the wound. Re-epithelialization begins not just at the wound margin but also from the appendageal structures. Typically, inflammation initiates a cascade of events with polymorphonuclear leukocytes being attracted to the wound site. Their principle role is proteolysis and phagocytosis of debris. They signal to macrophages which, when activated, enter the wound site to undertake a more detailed assessment of the damage and through a cytokine-mediated signaling process will recruit fibroblasts to begin the process of replacing the damaged collagen. Granulation tissue consisted of new fibroblasts and endothelial tissue develops as the result of an inflammatory response at the margin of the wound. The eschar becomes loosened and will finally slough. Because of the loss of skin appendages, the wound will be helped by contraction and epidermal growth from the edge. The end result of dermal repair is the deposition of disorganized collagen, which is physically apparent as scar tissue. Scarring is the major cause of long-term morbidity after a burn and can result in physical disability when function is

impaired and psychologic and social isolation when deformity impair features especially on the face and other regions of high esthetic impact [64].

2.5.7 Free radical and antioxidant therapy

Burn wound healing is a normal reaction to injury and the formation of scar tissue occurs through a series of cellular and biochemical process. Several studies have demonstrated that burn injury initiates systemic inflammatory reactions by producing burn toxins, reactive oxygen species (ROS) and finally leads to peroxidation [65]. Underlying mechanism of this event is the deformation of cell membrane phospholipids by oxidizing radicals. Cell membranes are rich sources of polyunsaturated fatty acids (PUFAs). The oxidative destruction of PUFAs is known as lipid peroxidation which causes tissue injury, leading to oxidative destruction of cellular membranes, and their destruction can lead to the production of toxic, reactive metabolites and cell death [5].

Reactive oxygen species are produced constantly in cells with normal metabolism. On the other hand, cells are able to protect themselves from destructive potential of oxygen radicals in normal physiologic condition by way of their own antioxidant mechanisms including enzyme systems, vitamins, elements, and some antioxidant molecules [66]. There is an exquisite balance between production and destruction of ROS. When this equilibrium is destroyed, ROS are produced excessively and all tissues are exposed to oxidative injury.

A good indicator of oxidative injury and end product of lipid peroxidation is the formation of malondialdehyde (MDA). Several studies demonstrated that burn is associated with elevated levels of MDA in different organ and tissue [7,8].

Since the major source of the oxidants could be neutrophils isolated in systemic organs as a systemic inflammatory reaction to a local burn affront, it can be expected that agents which inhibit the activation and adherence of neutrophils might also exert protective effects against thermal injury. It has been shown that antioxidants, when given postburn, restored antioxidant defense mechanism and attenuated tissue injury.

At is point the early intervention of antioxidant therapy will significantly help to restore cell mediated injury, decrease free radical mediated damage, minimize tissue

destruction during extensive burn injury and might help to promote the healing of burn injury [9].

2.5.8 Management of burn injuries

The goal of burns treatment can be stated as survival of the patient with rapid healing of wound and epithelialization, with minimal scarring and abnormal pigmentation [64].

Optimum treatment of the wound reduces morbidity and, in larger injuries, mortality. It also shortens the time for healing and return to normal function and reduces the need for secondary reconstruction [10].

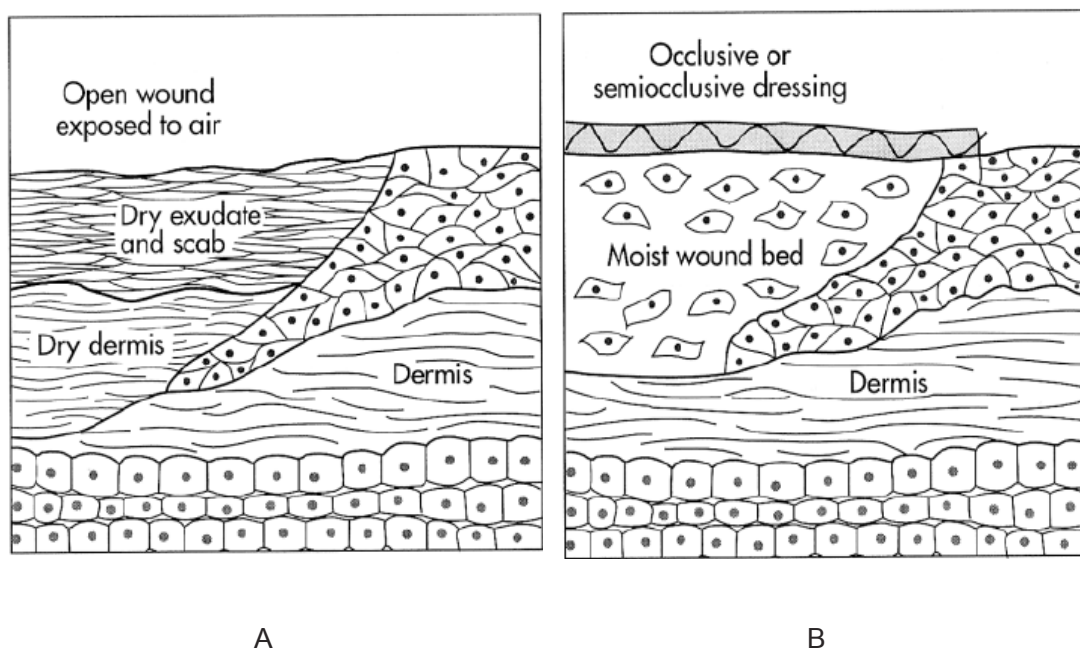


Figure 2.8 Treatment of wound A : Occlusive dressing (closed method)

B : Exposure therapy (open method) [10]

2.6 Diabetes mellitus and wound healing

Diabetes mellitus is a metabolic disorder that continues to present a major worldwide health problem. It is characterized by chronic hyperglycemia with disturbances of carbohydrate, fat and protein metabolism resulting from defects in insulin secretion and/or insulin action at target tissue or both [14]. Diabetes mellitus is a leading cause of morbidity and mortality, largely because of its vascular complications. Diabetic complications can be broadly classified into two types : microvascular complications (e.g., retinopathy, nephropathy) and macrovascular complications (e.g., coronary artery disease [CAD], cerebrovascular disease, peripheral disease).

Animal models are useful means of studying the early changes in diabetes. Experimental diabetes mellitus has been induced in laboratory animals by several methods. The method for creating diabetes in animals is injecting chemical substances such as streptozotocin (STZ) or alloxan can damage beta cells.

Diabetes mellitus which can be divided into four groups as follow [14] :

1. Type 1 diabetes

Type 1 diabetes is characterized by an absolute deficiency of insulin secretion caused by pancreatic β -cell destruction, usually resulting from an autoimmune attack. Type I diabetes accounts for approximately 10% of all cases.

2. Type 2 diabetes

Type 2 diabetes is caused by a combination of peripheral resistance to insulin action and an inadequate compensatory response of insulin secretion by the pancreatic β -cell (relative insulin deficiency). Approximately 80% to 90% patients have type 2 diabetes.

3. Gestational diabetes mellitus ; GDM

Gestational diabetes is caused by insulin resistance and relative insulin deficiency associated with pregnancy. Occurs in approximately 3% to 5% of all pregnancies.

4. Other specific types of diabetes mellitus

These types comprise a heterogenous etiologic group that includes those cases of diabetes in which the causes are established or at least partially known. The causes include known genetic defects affecting β -cell function or insulin action, diseases of the exocrine pancreas, endocrinopathies, drug or chemical-induced diabetes, infections, uncommon but specific forms of immune-mediated diabetes mellitus and other genetic syndromes sometimes associated with diabetes.

Oxidative stress results from an imbalance between the generation of oxygen derived radicals and the organism's antioxidant potential. It plays a crucial role in the pathogenesis of late diabetic complications. Factors that may promote oxidative stress in diabetes include antioxidant deficiencies, glycation and glyco-oxidation, and increased production of reactive oxygen species (ROS). Various studies have shown that diabetes mellitus is associated with increased formation of free radicals and with heavy oxidative stress. Due to an increase in the formation of free radicals in diabetes, the balance, normally present in cells between radical formation and protection against them, is disturbed. This leads to oxidative damage of cell components such as proteins, lipids, and nucleic acids [67]. Furthermore, ROS in the event following skin injury and impair healing process and delayed in the diabetic condition.

A variety of antioxidants scavenge reactive oxygen species (ROS) prevent the occurrence of oxidative damage to biological structures. The primary defense against oxidative stress in the cell rests with antioxidants, including vitamins C and E, reduced glutathione (GSH), and glutathione peroxidase (GSH-Px) [67].

Diabetes mellitus is a condition which is known to be associated with a variety of connective tissue abnormalities. The collagen content of skin is decreased, as a result of biosynthesis and/or accelerated degradation of newly synthesized collagen [68]. Deep skin wounds in non-diabetes were healed by contraction and granulation tissue formation. In contrast, diabetic wound closure is predominantly due to the formation of granulation tissue and re-epithelialization [69].

2.7 *Centella asiatica* (Linn.) Urban

Centella asiatica (Linn.) Urban has been used as a traditional herbal medicine in Asian countries for hundreds of years. It belongs to family Umbelliferae, subfamily Hydrocolyte. Its synonyms are Indian pennywort (English), Hydrocolyte asiatique (French), Tsubo-kusa (Japanese), Luei Gong Gen (Chinese). This plant is known in Thai as Bua-Bok [70].

2.7.1 Morphological description

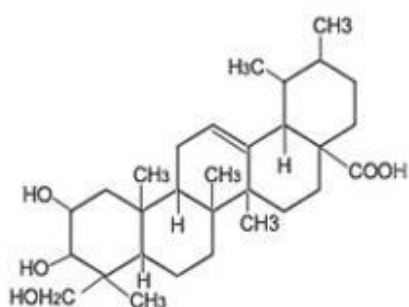
Centella asiatica (Linn.) Urban is a perennial herbaceous creeper. The stem is a glabrous, rooting at the nodes. The leaves are fleshy, orbicular-reniform, base cordate and often lobed and long-petioled. The flowers are red, pink or white, in fascicled umbels. The fruits are oblong, dull brown, laterally compressed, the pericarp hard. Thickened, woody and white [70].



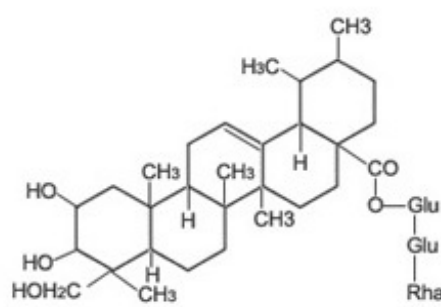
Figure 2.9 *Centella asiatica* (Linn.) Urban [71]

2.7.2 Major chemical constituents

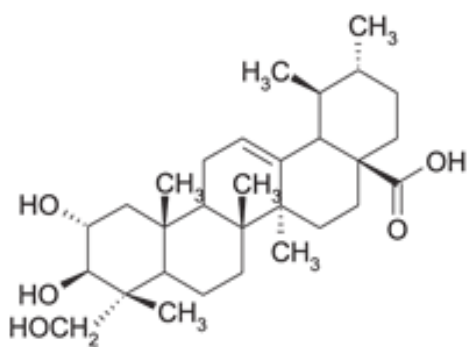
The major constituents in *Centella asiatica* are the triterpenes, mainly asiatic acid and madecassic acid, and their derived triterpene ester glycosides, asiaticoside and madecassoside. The structure are shown in Figure 2.10



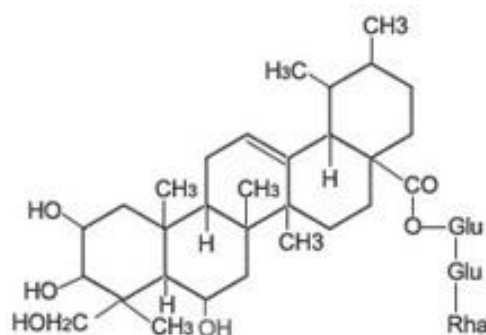
Asiatic acid



Asiaticoside



Madecassic acid



Madecassoside

Figure 2.10 Structure of asiatic acid, madecassic acid, asiaticoside and madecassoside [72, 73]

2.7.3 Traditional applications

The indications for the use of *Centella asiatica* in the field of traditional medicine are extremely wide like gastrointestinal, dermatological, infectious, nephrological, neurological and other disease [70].

- Gastrointestinal disease : it is used to treat dysentery, diarrhea, colicky abdominal pain, indigestion, gastric ulcers, gastritis and inflammatory diseases of the liver.

- Infectious disease : it was used as adjuvant treatment in cholera, syphilis and also used to treat influenza as well.

- Dermatological disease : it was used as adjuvant therapy in the treatment of leprous lesion.

- Nephrological and urogenital diseases : it is used to treat inflammatory diseases of the urogenital system and also used as diuretic.

- Neurological and psychiatric diseases : it is employed to treat psychiatric problems, epilepsy and hysteria.

- Other diseases : in addition to conditions already mentioned *C.asiatica* continues to be used to treat asthma, anemia, high blood pressure, diabetics and inflammatory disease of the eye and is also useful to combat physical and mental exhaustion.

2.7.4 Pharmacological study

2.7.4.1 Wound healing effects

Sunilkumar, Parameshwaraiah and Shivakumar (1998) investigated formulations (ointment, cream and gel) of aqueous extract of *C.asiatica*, when applied topically on the open wounds in rats, increased cellular proliferation and collagen synthesis at the wound site. The treated wounds epithelialized faster as the rate of wound contraction was higher as compared to control wounds. The process of healing was better with gel formulation when compared to other two formulations [75].

Shukla et al. (1999) reported that the wound healing activity of asiaticoside, isolated from *C.asiatica*. Asiaticoside was given by the oral at dose 1 mg/kg and topical application of 0.2% solution of asiaticoside in the guinea pig. In diabetic rats, topical application of 0.4% solution of asiaticoside. The results showed punch wounds increased hydroxyproline content, tensile strength, collagen content and epithelialization thereby facilitating the healing [22].

Later, Coldren et al. (2003) demonstrated that the molecular pathways of wound healing by titrated extract from *Centella asiatica* (TECA) as well as by the four principal triterpenoid components of *Centella*. TECA treatment effects the expression of genes involved in angiogenesis and the remodeling of extracellular matrix, as well as diverse growth factor genes [75].

In addition, Liu et al. (2008) reported that madecassoside isolated from *Centella asiatica* facilitated burn wound healing which were given at dose 12 and 24 mg/kg in mice. The result showed that madecassoside decreased nitric oxide (NO) and malondialdehyde (MDA) content in the burn skin tissue. However, glutathione (GSH) and hydroxyproline levels were increased in the same skin tissue. In addition, madecassoside promoted skin angiogenesis and enhanced epithelialization [24].

Moreover, Kimura et al. (2008) demonstrated that the topical application of a low dose (10 pg – 100 ng/wound area) of asiaticoside facilitated burn wound. These findings suggest that the enhancement of burn wound healing by asiaticoside might be due to the promotion of angiogenesis during skin wound repair as

a result of the stimulation of vascular endothelial growth factor (VEGF) production caused by the increase in monocyte chemoattractant protein-1 (MCP-1) expression in keratinocytes and increase in interleukin- β (IL- β) expression in macrophage [23].

2.7.4.2 Antioxidant activity

Jayashree et al. (2003) showed that oral treatment with 50 mg/kg/day of crude methanol extract of *Centella asiatica* for 14 days significantly increased the anti-oxidant enzymes, like superoxide dismutase (SOD), catalase and glutathione peroxidase (GSHPx), and anti-oxidants like glutathione (GSH) and ascorbic acid decreased in lymphoma-bearing mice [76].

2.7.4.3 Anti-ulcer effect

Cheng et al. (2004) showed that the healing effects of *Centella asiatica* water extract (CE) and asiaticoside (AC), an active constituent of CE, on acetic acid induced gastric ulcers (kissing ulcers) in rats. The result showed that AC and CE reduced the size of the ulcers at day 3 and 7 in a dose-dependent, with a concomitant attenuation of myeloperoxidase activity at the ulcer tissues. Epithelial cell proliferation and angiogenesis were on the other hand promoted [77].

2.7.4.4 Ant-inflammation effect

Puntureea, Christopher and Vinitketkumneuna (2004) reported that the anti-inflammatory activity of *Centella asiatica* (water extract) on modulate the production of nitric oxide (NO) and tumour necrosis factor- α (TNF- α) by J774.2 mouse macrophages. The result showed that CA (water extract) increased, in a dose-dependent manner, expression of the inducible nitric oxide synthase (iNOS) and TNF- α genes. Increases also occurred when CA was administered with lipopolysaccharide (LPS), a known macrophage activator. In contrast, an ethanol extract of CA had no effect on NO, and when administered with LPS the extract suppressed production [78].

2.7.4.5 Anti-tumor effect

Babu, Kuttan and Padikkala (1995) investigated the anti-tumor effect of the crude extract (CE) of *Centella asiatica* and partially purified fractions (AF) by both *in vitro* short and long term chemosensitivity and *in vivo* tumor model test systems. The result showed that AF dose dependently inhibited the proliferation of the transformed cell lines significantly more than the CE. Oral administration of the extracts (CE and AF) retarded the development of solid and ascites tumors and increased the life span of these tumor bearing mice which fraction acts directly on DNA synthesis [79].

2.7.4.6 Neuroprotective effect

Veeranda Kumar and Gupta (2002) investigated the aqueous extract of *Centella asiatica* at dose 200 mg/kg for 14 days to rats showed an improvement in learning and memory, while only two dose 200 and 300 mg/kg of aqueous extract showed a significant decrease in the brain levels of malondialdehyde (MDA) with simultaneous significant increase in levels of glutathione [80].

Gupta, Veerendra Kumar and Srivastava (2003) demonstrated that the administration of *Centella asiatica* (300 mg/kg orally) decreased the Pentylene-tetrazole (PTZ)-kindled seizures and showed improvement in the learning deficit induced by PTZ kindling as evidenced by decreased seizure score and increased latencies in passive avoidance behavior [81].

Toxicity study

Acute toxicity and sub-chronic toxicity study of standardized extract of *Centella asiatica* (ECa 233) have revealed very favorable toxicological profiles. No death was observed in mice acutely treated with ECa 233 in the dose up to 10 g/kg and oral administration of ECa 233 in the doses of 10-1000 mg/kg for 90 days did not cause any significant changes in all parameter observed [25].

CHAPTER III

MATERIALS AND METHODS

3.1 Materials

3.1.1 Chemical substances

- Streptozotocin (Sigma, USA)
- Citrate buffer (Sigma, USA)
- Hematoxylin stain (Bio-Optica, Italia)
- Eosin stain (Bio-Optica, Italia)
- Alcohol (Siribuncha Co., Ltd, Thailand)
- Formaldehyde (FORMALIN[®], Vidhyasom Co.,Ltd, Thailand)
- Xylene (TJ Baker, USA)
- Paraffin (Tyco Healthcare group LP, USA)
- Pentobarbital sodium (NEMBUTAL[®], Sanofi, France)
- Normal saline solution (Klean & Kare, Thailand)
- Trichloroacetic acid (Sigma, USA)
- Butylatehydroxy toluene (Sigma, USA)
- Methanol (Lab-scan Asia, Thailand)
- Thiobarbituric acid (Sigma, USA)
- Opilca (hair removal cream) (GlaxoSmithKline Co.,Ltd, Thailand)

3.1.2 Instrument

- Electrical hot plate
- Laser doppler flowmeter (Perimed AB SE-175 26, PeriFlux System 5000, Sweden)
- Spectrophotometer (Shimadzu UV-160A)
- Light microscope (Nikon 516609)

- Battalion
- Glucometer (Accu-Chek Advantage, USA)
- Glucose oxidase reagent strips (Accu-Chek Advantage, USA)
- Cover glass
- Slide
- Rotary microtome (Leica, Vashaw Scientific, Norcross, GA)
- Digital camera
- Image Tool V.3.0
- Others : Syringes, Needles, Cotton pads

3.1.3 Experimental animal

The experimental protocol was approved by Faculty of Pharmaceutical Sciences, Chulalongkorn University Animal Care and Use Committee (Approval No.09-33-005). Male Wistar rats weighing 250-300 g were obtained from the National Laboratory Animal Center, Mahidol University, Salaya, Nakornpathom. The rats were caged in the air-conditioned room maintained temperature at $25 \pm 1^\circ\text{C}$. They were provided with food and water *ad libitum* and acclimatized for 1 week before experimentation. A total of 216 male Wistar rats were divided into two groups of 108 animals for normal and diabetic rats. In each group, the animals were subdivided into six subgroups as follows : no burn, burn with no treatment (untreated), burn treated with gel base, burn treated with 0.05, 0.1 and 0.5 % ECa 233 gel.

3.1.4 Preparation of test compound

ECa 233 was prepared by Associate Professor Ekarin Saifah and Associate Professor Rutt Suttisri, Faculty of Pharmaceutical Sciences, Chulalongkorn University. Standardized extracted powder of *Centella asiatica* (ECa 233), which is a white to off-white, containing triterpenoids not less than 80% and the ratio between madecassoside and asiaticoside was kept at 1.50 ± 0.50 and it was prepared in a gel base (Jatt Intergroup Co.,Ltd, Bangkok, Thailand), in the concentration of 0.05%, 0.1% and 0.5% ECa 233.

3.2 Methods

3.2.1 Induction of diabetes

Diabetes was induced in rats by a single intravenous (i.v.) injection of streptozotocin (STZ : Sigma Chemical Co.,Ltd) at the dose of 50 mg/kg BW in 0.1 M citrate buffer, pH 4.0 [82]. Fasting blood glucose was determined by using glucometer. Sample were analyzed by applying a drop of blood with glucose oxidase reagent strips at 3 days after STZ injection. Animals with glucose levels greater than 200 mg/dl were used for study. Burn wounds were created on the 7th day after induction of diabetes [68].

3.2.2 Induction of second degree of burn injury

The effects of standardized extract of *Centella asiatica* ECa 233 on burn wound was investigated using the method of Somboonwong et al. (2000) [83] which was modified from Zawacki (1974) [84]. The animals were anesthetized with pentobarbital sodium 60 mg/kg BW., intraperitoneally (i.p.). Back of animals between lower parts of scapulas were shaved and depilated. Second-degree burn was made by placing the 90°C hot plate (diameter 2 cm) (Figure 3.1) on the selected area of the back for 10 sec [1, 5]. The wounded area of each animal was measured immediately after burning on day 3, 7 and 14 (Figure 3.2). It involves approximately 2.5% of total body surface area of animal. The color photograph of the wounds was taken by digital camera and areas of

wound were measured by Image Tool v.3.0. The rate of wound healing was calculated by the method as described by Liu et al. (2008) [24]. After recover from anesthesia, the animals were housed with free access to water and standard laboratory chow. The wounds were daily treated with 100 mg of the test substances topically. On day 3, 7 and 14 post burning, animals were sacrificed with pentobarbital sodium 100 mg/kg BW., intraperitoneally. Half-sized of the tissue sample in the healed wound was isolated from each animal for lipid peroxidation assay and histopathological examination.



Figure 3.1 Electrical hot plate

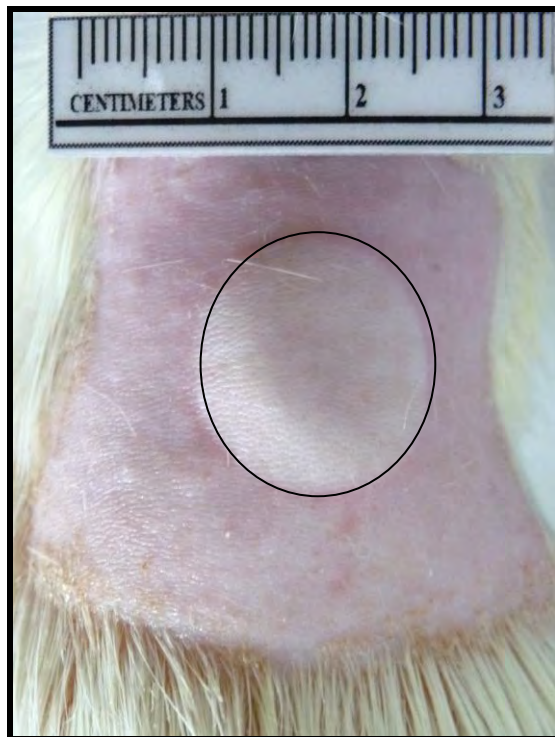


Figure 3.2 The area prepared for wounding of burn wound, the burned area of animal was measured immediately after burning. The color photograph of the wounds were taken by using digital camera, the wound area was indicated by circle line (diameter 2 cm)

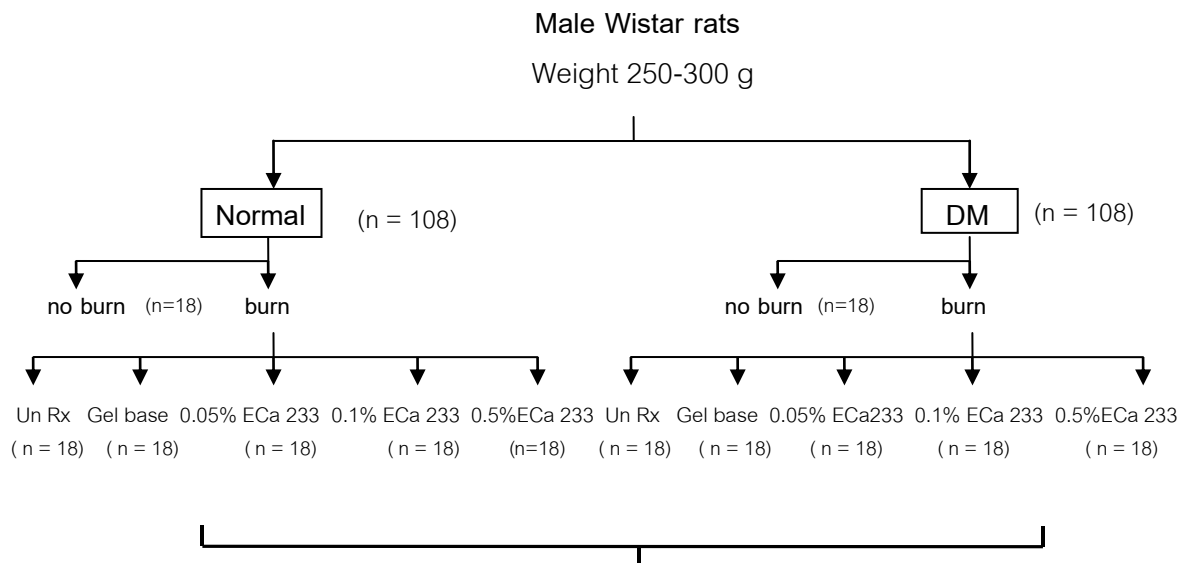
3.2.3 Animal preparation

A total of 216 male Wistar rats were divided into two groups of 108 animals each for normal and diabetic rats. In each group, the animals were subdivided into six subgroups of 18 animals each.

Normal and diabetic groups : The animals were divided randomly into six groups as follows : (Figure 3.3)

1. no burn (unwounded)
2. burn with no treatment (untreated)
3. burn treated with gel base
4. burn treated with 0.05% ECa 233 gel
5. burn treated with 0.1% ECa 233 gel
6. burn treated with 0.5% ECa 233 gel

In addition, no burn (unwounded) group were used as references in measurement of cutaneous blood flow and malondialdehyde (MDA).



Evaluation of wound at day 3, 7 and 14

1. Rate of wound healing : Size of wound
2. Cutaneous blood flow : Laser Doppler Flowmeter
3. Antioxidant activity : Lipid peroxidation assay (MDA)
4. Histopathological study : Hematoxylin and Eosin dyes

Figure 3.3 Diagram of experimental animal groups

3.3 Evaluation of burn wound

3.3.1 General appearance of the wound

The lesion of wounds was grossly examined on day 3, 7 and 14 post burning. The wounds were examined in terms of color, exudates, swelling of wound surface and the consistency of surrounding wound tissue.

3.3.2 Rate of wound healing

On day 3, 7 and 14 post burning, photographs of the wounds were taken by digital camera. The areas of wound were measured by Image Tool v.3.0 and the rate of wound healing was calculated using the following formula [24].

$$\text{Wound healing rate (\%)} = \frac{[(\text{wound area on day 0 (cm}^2\text{)} - \text{wound area on day N (cm}^2\text{)}) / \text{wound area on day 0 (cm}^2\text{)}] \times 100\%}$$

3.3.3 Cutaneous blood flow

Measurement of cutaneous blood flow was carried out by a Laser doppler flowmeter (Perimed AB SE-175, Periflux System 5000, Figure 3.4) [85]. The method modified from Eun (1995) and Fagrell (1995) was used in this study [86, 87]. The needle probe was fixed perpendicularly on skin. Five different measurements (at the center and four corners) (Figure 3.5) were performed at each time and the mean value was used for calculation. Cutaneous blood flow in all burn groups were expressed as percentage of the cutaneous blood flow of their respective no burn (unwounded) groups.



Figure 3.4 Laser Doppler Flowmeter

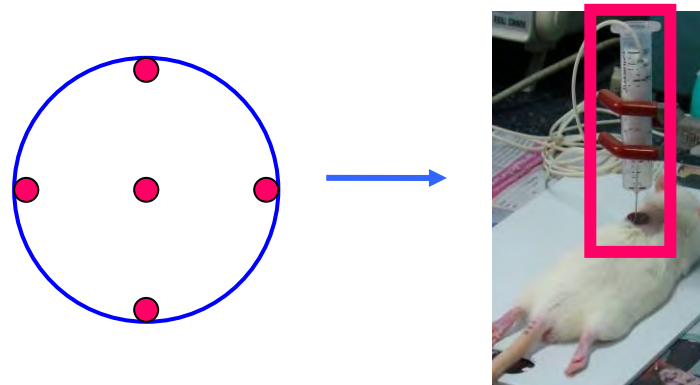


Figure 3.5 Selected position in the wound area for measurement of cutaneous blood flow

3.3.4 Lipid peroxidation assay

Lipid peroxidation was determined by measuring the level of malondialdehyde (MDA) which is an end product of lipid peroxidation using the method as described by Wei et al., 2002. Sample of skin were homogenized in 1.8 ml of 10% trichloroacetic acid and 0.2 ml of butylatedhydroxy toluene in methanol (0.5 g/L). The homogenate was heated at 100° c for 30 min and then cooled down at room temperature. After centrifugation at 5000 rpm, the resultant supernatant was mixed with equal volume of 0.67% 2-thiobarbituric acid and incubated at 100° c for another 30 min and then centrifuged at 5000 rpm for 5 min. Concentration of malondialdehyde (MDA) was calculated based on the absorbance determined by a spectrophotometer at 532 nm and the final was express as μmol of MDA per g/tissue of skin [88].

3.3.5 Histopathological analysis

The specimen of skin, 0.5x0.5 cm in size was taken from the half of burn area. The tissue were preserved in the fresh fixative aqueous 10% neutral buffered formaldehyde solution for at least 24 hrs and embedded in paraffin. The section of 10 μm in thickness were cut and stained with hematoxylin and eosin dyes. The light microscope (Nikon 516609) with x4 and x10 objective lens was used to examine the specimen.

3.3.6 Histopathological evaluation of hair follicles

Quantitative evaluation of hair follicles was performed on a complete section located mostly closed to the mid line of the wound. Center of the section was marked under light microscope (Nikon 5216609) with x4 magnification and transmitted to a computer screen where histological inspection was made. The area of 0.75 mm x 0.75 mm at the center of the section was identified using Image Tool V.3.0 and numbers of hair follicle in the assigned field were counted by an investigator unaware of the treatment. One fields/section/animal from all animals in each group was used.

3.4 Statistical analysis

Results are presented as mean \pm standard error of mean, (S.E.M.). The differences among experimental groups were compared by one-way analysis of variance (ANOVA) followed by Duncan post hoc test and were considered statistically when P was less than 0.05.

CHAPTER IV

RESULTS

4.1 Effects of ECa 233 on rate of wound healing

Rate of wound healing was calculated on day 3, 7 and 14 post burning by using the formula previously described [24].

4.1.1 Normal rats

4.1.1.1 On day 3 post burning

On day 3 post burning in normal rats, rate of wound healing of untreated group ($14.12 \pm 2.48\%$) was not significantly different from gel base-treated group ($16.12 \pm 2.64\%$). The rate of wound healing in 0.05% ($22.75 \pm 1.68\%$) and 0.1% ($21.76 \pm 2.44\%$) ECa 233 gel-treated groups were significantly different from untreated group but rate of wound healing in 0.5% ECa 233 gel-treated group ($20.94 \pm 2.05\%$) was not significantly different from untreated group.

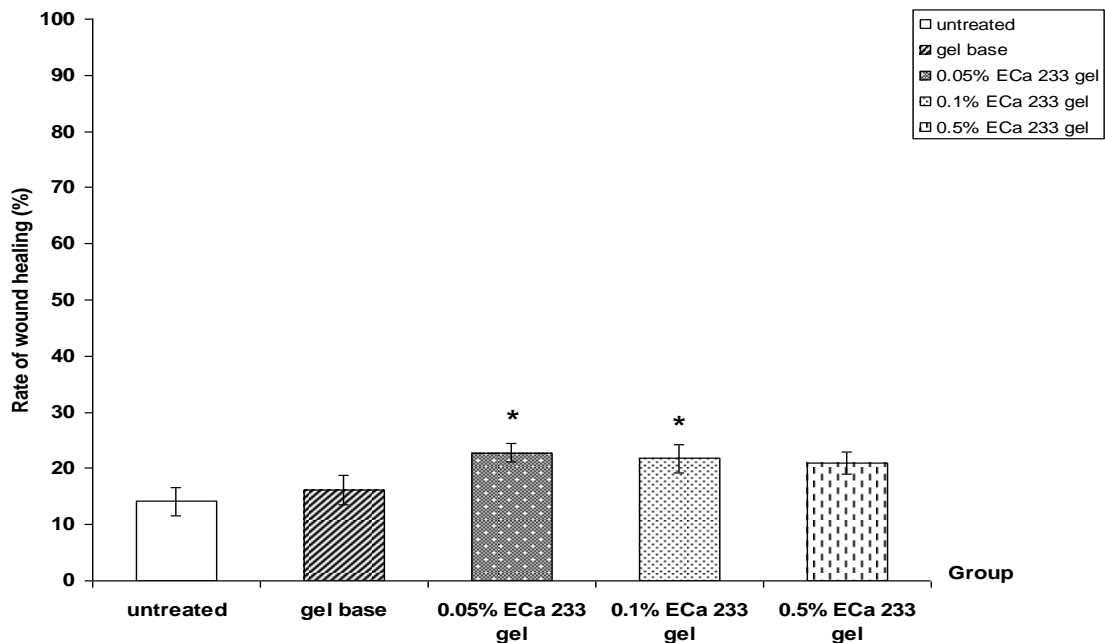


Figure 4.1 Rate of wound healing on day 3 post burning in normal rats : untreated, gel base, 0.05% ECa 233 gel, 0.1% ECa 233 gel, 0.5% ECa 233 gel treated groups.

The data is presented as mean \pm S.E.M. (n=6).

* $p < 0.05$ denotes statistically significant difference from untreated group.

4.1.1.2 On day 7 post burning

On day 7 post burning in normal rats, further increase rate of wound healing was noted in all experiment groups. The rate of wound healing in untreated group ($24.91 \pm 3.78\%$) was not significantly different from gel base-treated group ($27.78 \pm 2.23\%$). The rate of wound healing ($42.52 \pm 1.88\%$, $37.96 \pm 1.91\%$, $35.34 \pm 1.60\%$) were observed in 0.05%, 0.1% and 0.5% ECa 233 gel-treated groups were significantly different from untreated and gel base-treated groups.

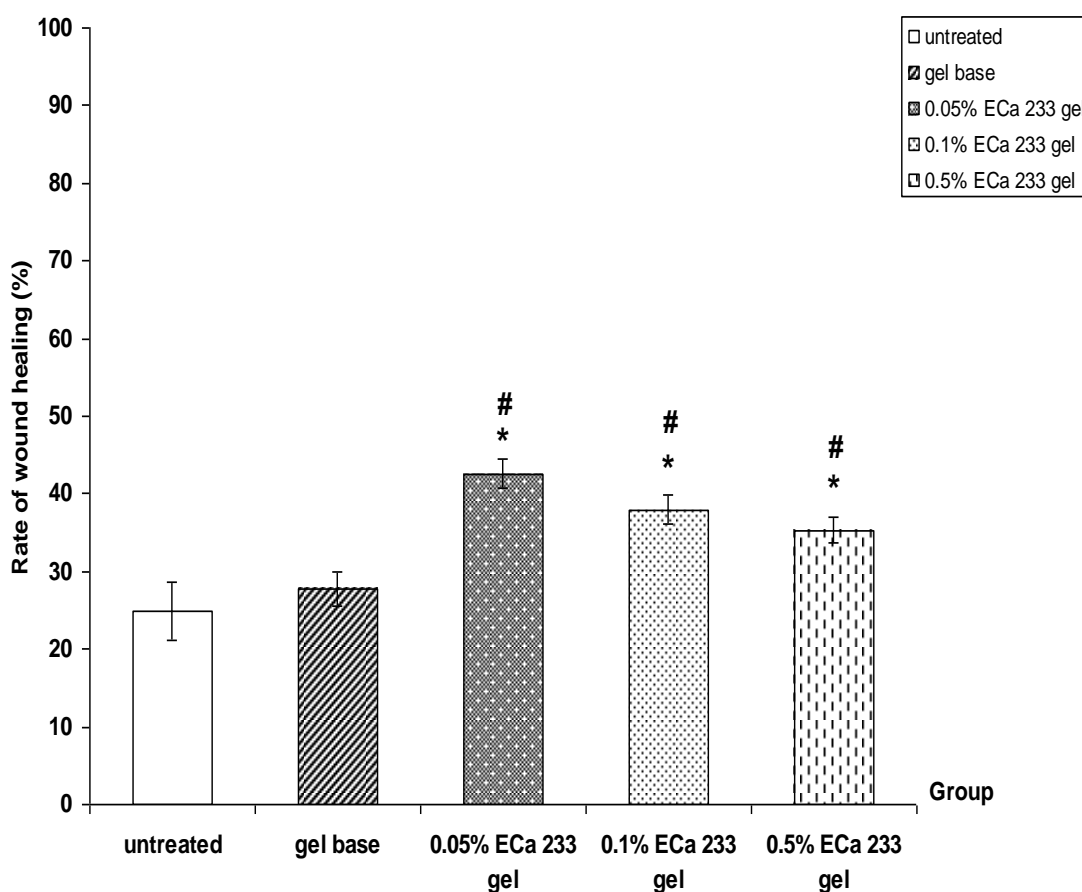


Figure 4.2 Rate of wound healing on day 7 post burning in normal rats : untreated, gel base, 0.05% ECa 233 gel, 0.1% ECa 233 gel, 0.5% ECa 233 gel treated groups. The data is presented as mean \pm S.E.M. (n=6).

* $p < 0.05$ denotes statistically significant difference from untreated group.

$p < 0.05$ denotes statistically significant difference from gel base-treated group.

4.1.1.3 On day 14 post burning

On day 14 post burning in normal rats, further increase rate of wound healing was noted in all experiment groups. The rate of wound healing in untreated group ($48.36 \pm 8.34\%$) was not significantly different from gel base-treated group ($54.94 \pm 8.04\%$). In the 0.05% ECa 233 gel-treated group, rate of wound healing ($78.40 \pm 3.74\%$) was significantly different from untreated and gel base-treated groups but rate of wound healing in 0.1% ($69.30 \pm 6.33\%$) and 0.5% ($65.14 \pm 7.07\%$) ECa 233 gel-treated groups were not significantly different from untreated and gel base-treated groups.

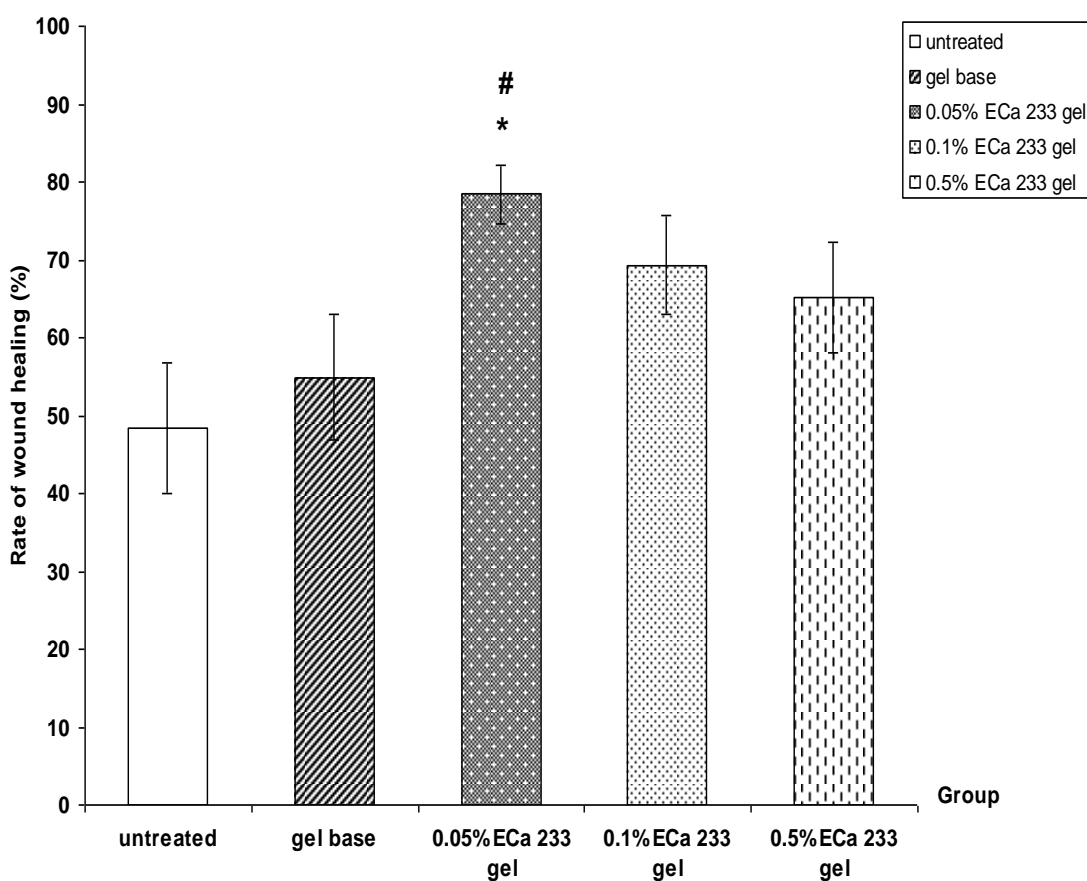


Figure 4.3 Rate of wound healing on day 14 post burning in normal rats :untreated, gel base, 0.05% ECa 233 gel, 0.1% ECa 233 gel, 0.5% ECa 233 gel treated groups. The data is presented as mean \pm S.E.M. (n=6).

* $p < 0.05$ denotes statistically significant difference from untreated group.

$p < 0.05$ denotes statistically significant difference from gel base-treated group.

4.1.2 Diabetic rats

4.1.2.1 On day 3 post burning

No significant effects on rate of wound healing in diabetic rats were observed on day 3 post burning, rate of wound healing in untreated group ($12.32 \pm 3.59\%$) was not significantly different from gel base-treated group ($14.76 \pm 2.87\%$). In the 0.05%, 0.1% and 0.5% ECa 233 gel-treated groups, rate of wound healing ($19.78 \pm 3.24\%$, $16.09 \pm 3.25\%$, $16.10 \pm 2.40\%$) were not significantly different from untreated group.

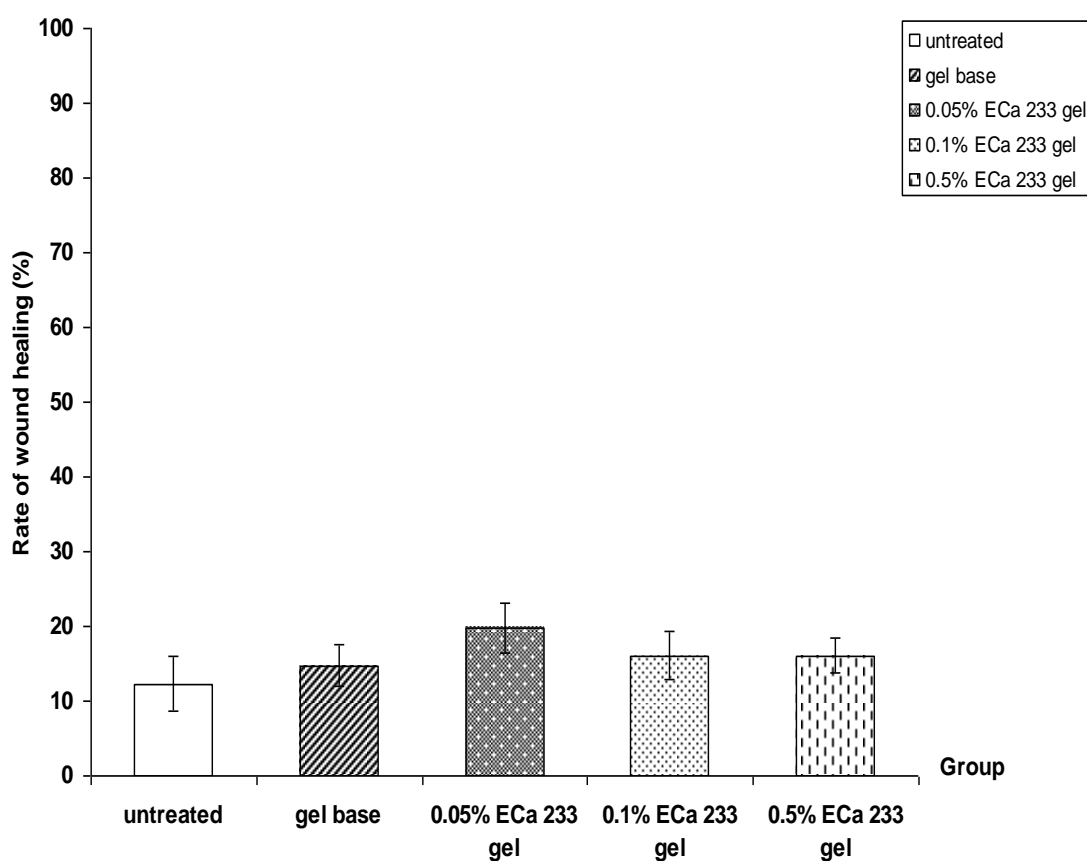


Figure 4.4 Rate of wound healing on day 3 post burning in diabetic rats : untreated, gel base, 0.05% ECa 233 gel, 0.1% ECa 233 gel, 0.5% ECa 233 gel treated groups. The data is presented as mean \pm S.E.M. (n=6).

4.1.2.2 On day 7 post burning

On day 7 post burning in diabetic rats, rate of wound healing in untreated group ($23.20 \pm 2.54\%$) was not significantly different from gel base-treated group ($26.96 \pm 2.04\%$). In the 0.05% ECa 233 gel-treated group, rate of wound healing ($38.62 \pm 1.77\%$) was significantly different from untreated and gel base-treated groups. The rate of wound healing in 0.1% ECa 233 gel-treated group ($34.11 \pm 4.15\%$) was significantly different from untreated group but 0.5% ECa 233 gel-treated group ($31.74 \pm 3.17\%$) was not significantly different from untreated and gel base-treated groups.

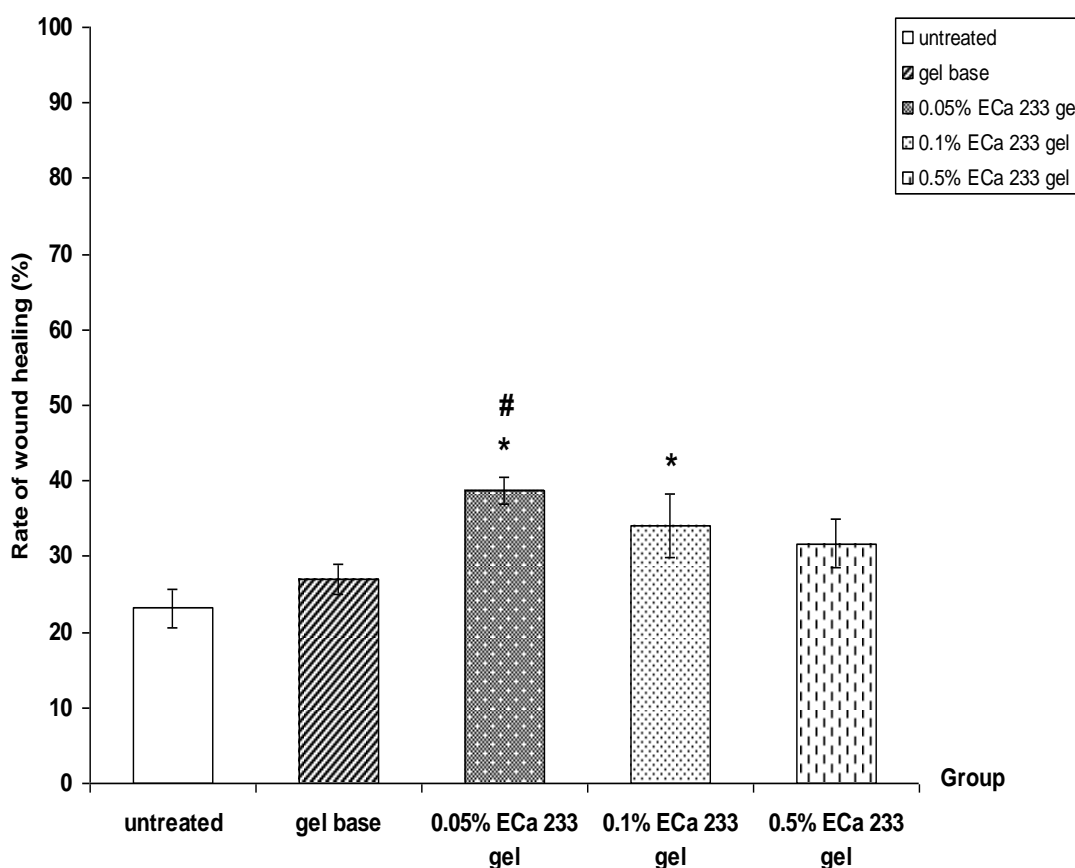


Figure 4.5 Rate of wound healing on day 7 post burning in diabetic rats : untreated, gel base, 0.05% ECa 233 gel, 0.1% ECa 233 gel, 0.5% ECa 233 gel treated groups.

The data is presented as mean \pm S.E.M. (n=6).

* $p < 0.05$ denotes statistically significant difference from untreated group.

$p < 0.05$ denotes statistically significant difference from gel base-treated group.

4.1.2.3 On day 14 post burning

On day 14 post burning in diabetic rats, rate of wound healing in untreated group ($35.80 \pm 6.54\%$) was not significantly different from gel base-treated group ($48.94 \pm 3.06\%$). In the 0.05% ECa 233 gel-treated group, rate of wound healing ($57.41 \pm 3.48\%$) was significantly different from untreated group but rate of wound healing in 0.1% ($53.54 \pm 7.12\%$) and 0.5% ($53.62 \pm 7.18\%$) ECa 233 gel-treated group were not significantly different from untreated and gel base-treated groups.

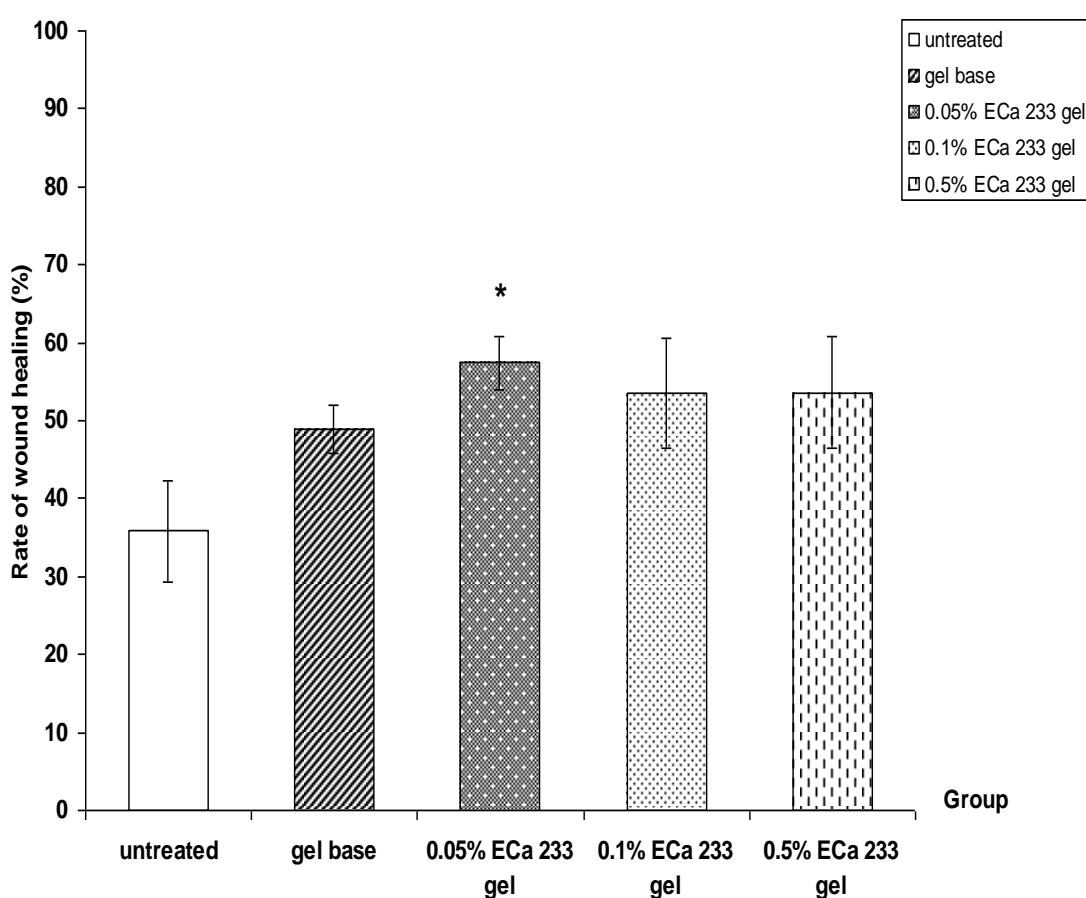


Figure 4.6 Rate of wound healing on day 14 post burning in diabetic rats : untreated, gel base, 0.05% ECa 233 gel, 0.1% ECa 233 gel, 0.5% ECa 233 gel treated group.

The data is presented as mean \pm S.E.M. (n=6).

* $p < 0.05$ denotes statistically significant difference from untreated group.

4.2 Gross pathology evaluation

Gross pathology evaluation was made on day 3, 7 and 14 post burning by an observation of wound lesion and assessment of rate of wound healing.

4.2.1 General appearance of the wound in normal rats

On day 3 post burning in normal rats, wound in untreated and gel base-treated groups became swelling and exudate (Figure 4.7A, 4.7B). In comparison, the wound in all ECa 233 gel-treated groups showed a mild degree of swelling and wound surface was rather dry and smooth (Figure 4.7C, 4.7D, 4.7E).

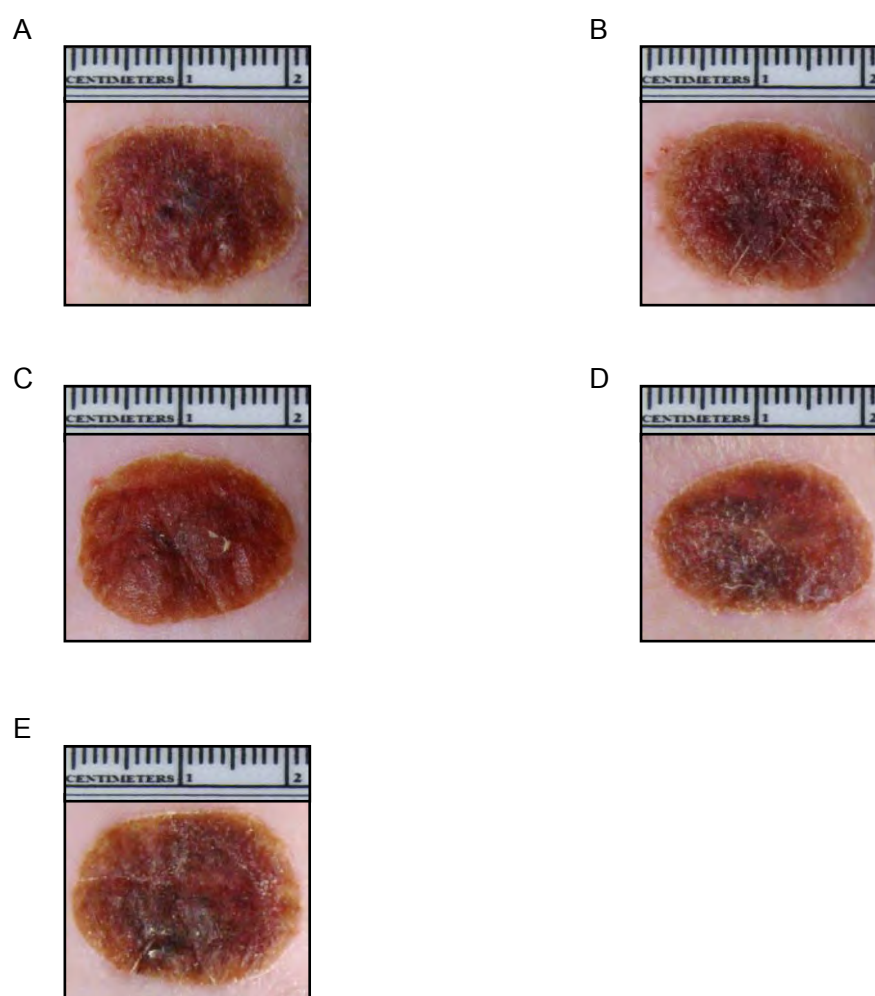


Figure 4.7 The wound appearance on day 3 post burning in normal rats.

A) Untreated wound

B) Gel base-treated wound

C) 0.05% ECa 233 gel-treated wound

D) 0.1% ECa 233 gel-treated wound

E) 0.5% ECa 233 gel-treated wound

On day 7 post burning in normal rats, wound in untreated, gel base, 0.05%, 0.1% and 0.5% ECa 233 gel-treated groups show red color, thickening of the wound size remain reduced from the first day. Most of wounds treated with all ECa 233 gel showed apparent wound contraction, becoming smaller in diameter when compared to the untreated and gel base-treated groups (Figure 4.8 A-E).

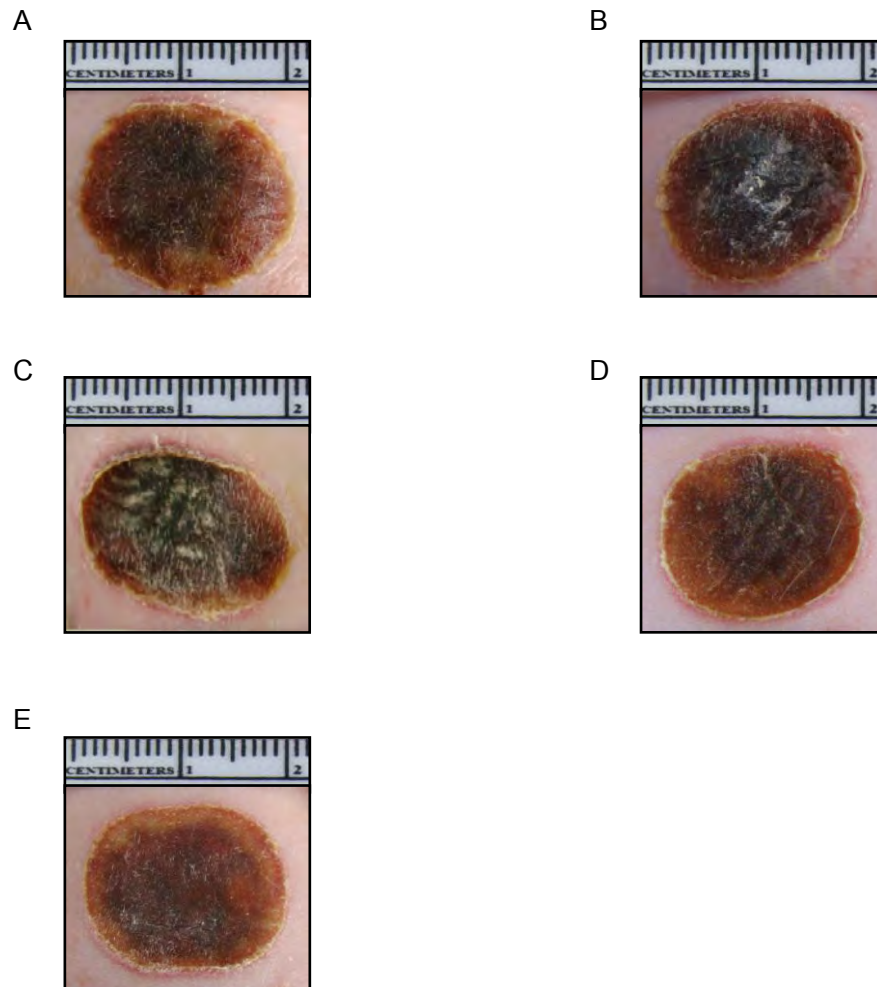


Figure 4.8 The wound appearance on day 7 post burning in normal rats.

A) Untreated wound

B) Gel base-treated wound

C) 0.05% ECa 233 gel-treated wound

D) 0.1% ECa 233 gel-treated wound

E) 0.5% ECa 233 gel-treated wound

4.2.2 General appearance of the wound in diabetic rats

On day 3 post burning in diabetic rats, wound in untreated and gel base-treated groups showed modulate exudation and swelling. All wound in all ECa 233 gel-treated groups showed dry wound surface, progressive wound contraction and reduced of wound size (Figure 4.10 A-E).

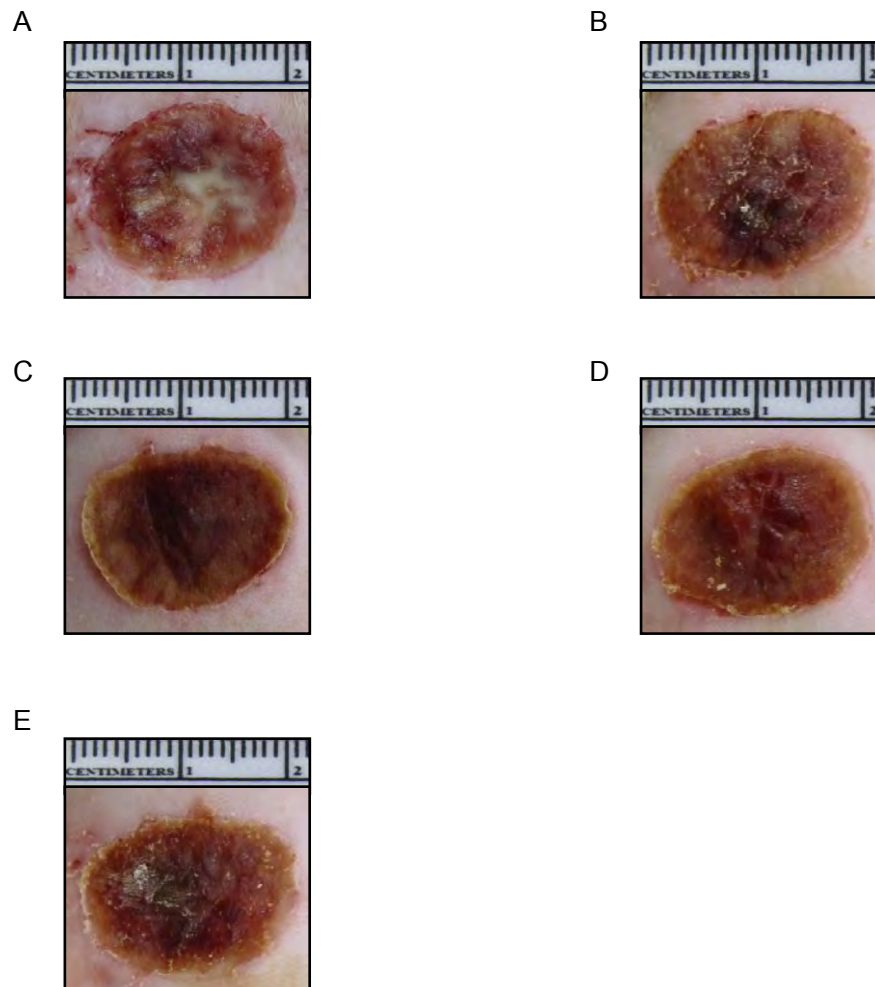


Figure 4.10 The wound appearance on day 3 post burning in diabetic rats.

A) Untreated wound

B) Gel base-treated wound

C) 0.05% ECa 233 gel-treated wound

D) 0.1% ECa 233 gel-treated wound

E) 0.5% ECa 233 gel-treated wound

On day 7 post burning in diabetic rats, wound in untreated and gel base-treated groups showed swelling and dark red color, thickening of skin at wound and wound size slightly decreased compared with those at beginning. All wound in ECa 233 gel-treated groups showed decreased in wound size (Figure 4.11 A-E).

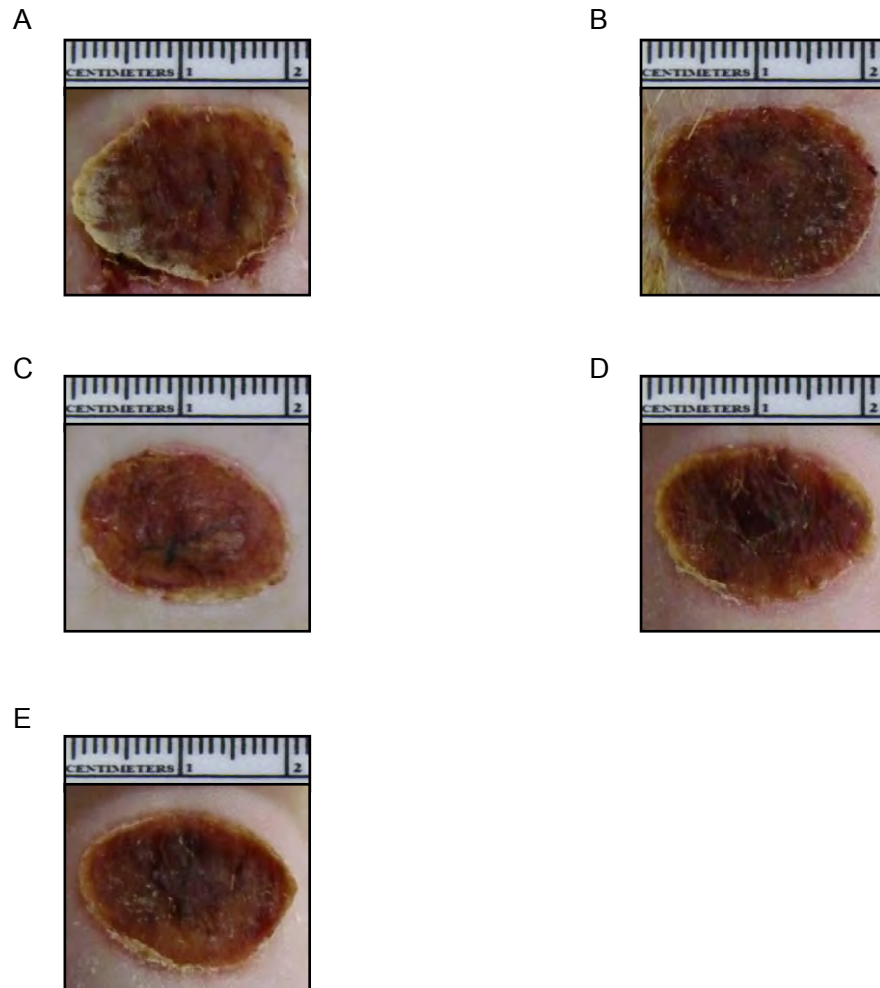


Figure 4.11 The wound appearance on day 7 post burning in diabetic rats.

A) Untreated wound

B) Gel base-treated wound

C) 0.05% ECa 233 gel-treated wound

D) 0.1% ECa 233 gel-treated wound

E) 0.5% ECa 233 gel-treated wound

On day 14 post burning in diabetic rats, wound in untreated and gel base-treated groups remain swelling and wound surface covered by scabs. All wound in ECa 233 gel-treated groups showed remarkable decrease in wound size (Figure 4.12 A-E).

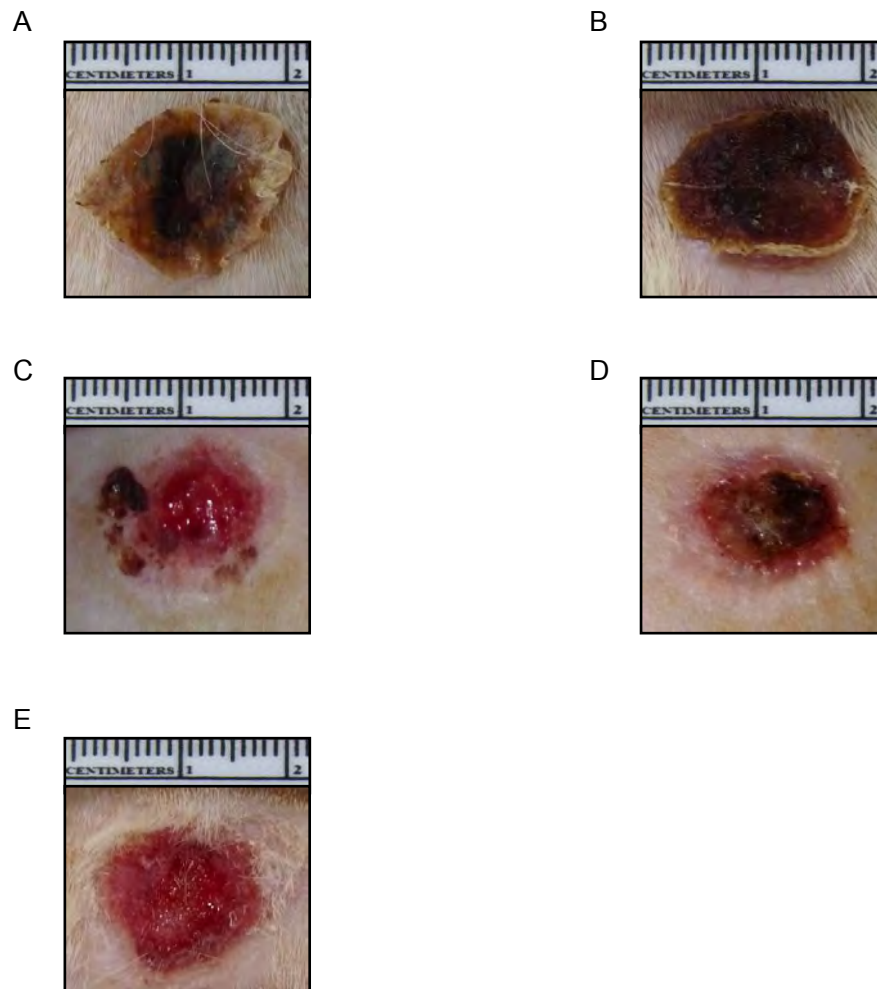


Figure 4.12 The wound appearance on day 14 post burning in diabetic rats.

A) Untreated wound

B) Gel base-treated wound

C) 0.05% ECa 233 gel-treated wound

D) 0.1% ECa 233 gel-treated wound

E) 0.5% ECa 233 gel-treated wound

4.2 Effects of ECa 233 on cutaneous blood flow (Laser Doppler Flowmeter measurement)

4.3.1 Normal rats

4.3.1.1 Cutaneous blood flow on day 3

Cutaneous blood flow measured at the wound, on day 3 after burning at the center and surround area see figure 3.5. In comparison to no burn (unwounded) skin, blood flow was found to be increased in all groups of animal with wound.

On day 3 post burning, cutaneous blood flow of each groups ($144.44 \pm 10.75\%$, $166.35 \pm 12.90\%$, $168.41 \pm 14.61\%$, $148.78 \pm 10.38\%$ in gel base-treated, 0.05%, 0.1% and 0.5% ECa 233 gel-treated groups, respectively) were significantly different from untreated group ($109.59 \pm 8.21\%$) (Figure 4.13).

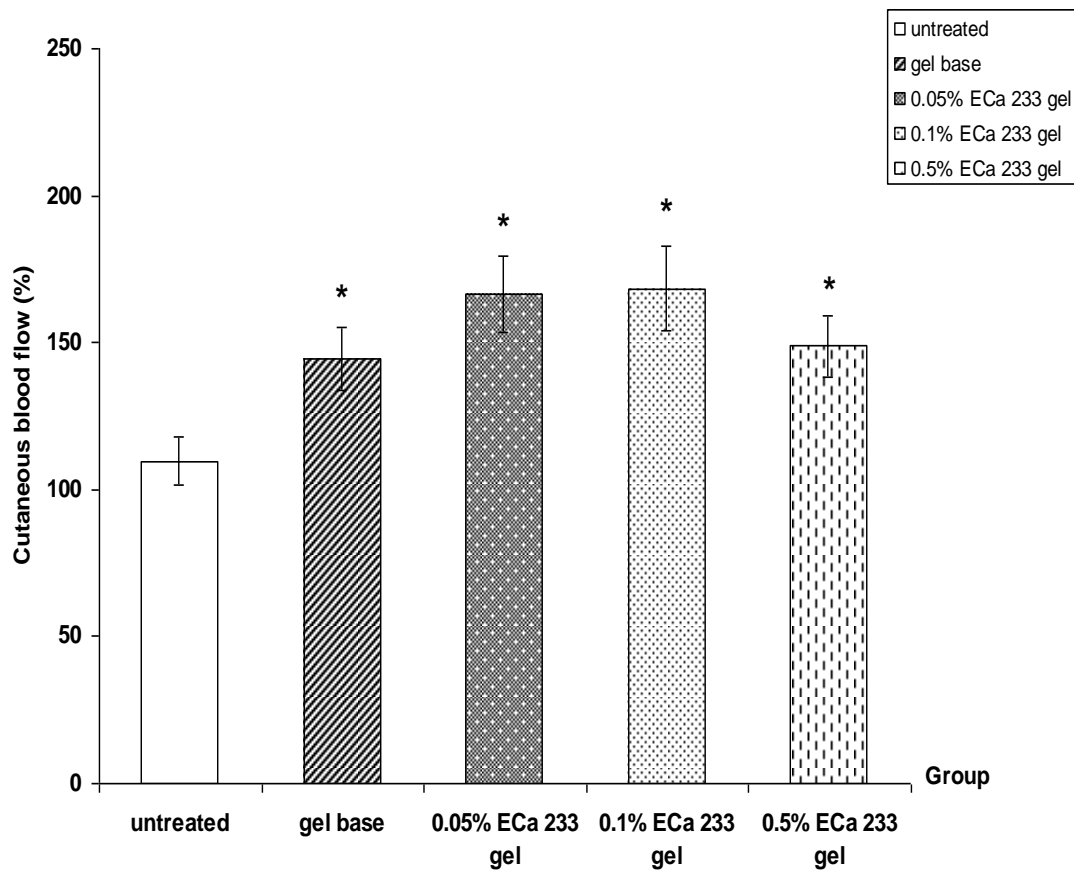


Figure 4.13 Cutaneous blood flow on day 3 post burning in normal rats : untreated, gel base, 0.05% ECa 233 gel, 0.1% ECa 233 gel, 0.5% ECa 233 gel treated groups.

The data is presented as mean \pm S.E.M. (n=6).

* $p < 0.05$ denotes statistically significant difference from untreated group.

4.3.1.2 Cutaneous blood flow on day 7

On day 7 post burning in normal rats, cutaneous blood flow of each groups ($148.14 \pm 8.77\%$, $148.77 \pm 8.22\%$, $147.85 \pm 16.38\%$ in 0.05%, 0.1% and 0.5% ECa 233 gel-treated groups, respectively) were significantly different from untreated group ($106.52 \pm 9.18\%$) but gel base-treated group ($127.92 \pm 7.16\%$) was not significantly different from untreated group (Figure 4.14).

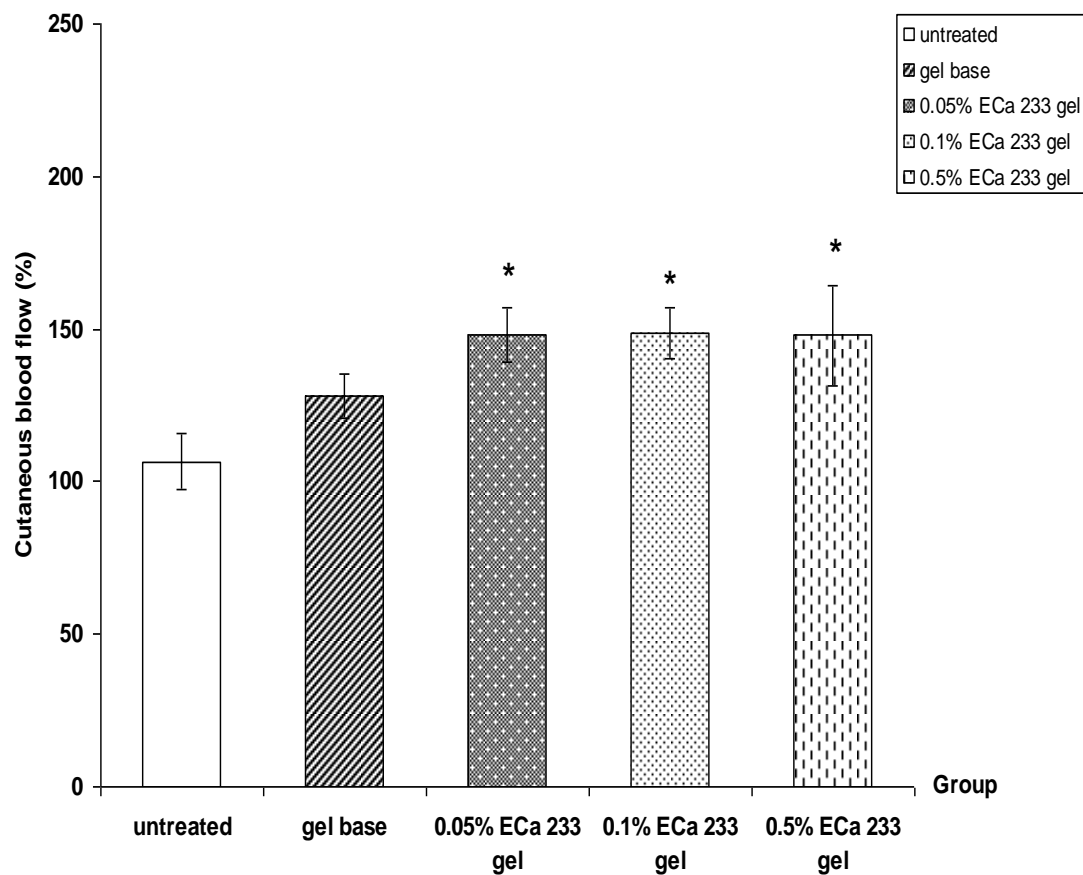


Figure 4.14 Cutaneous blood flow on day 7 post burning in normal rats : untreated, gel base, 0.05% ECa 233 gel, 0.1% ECa 233 gel, 0.5% ECa 233 gel treated groups. The data is presented as mean \pm S.E.M. (n=6).

* $p < 0.05$ denotes statistically significant difference from untreated group.

4.3.1.3 Cutaneous blood flow on day 14

On day 14 post burning in normal rats, cutaneous blood flow of untreated group ($112.79 \pm 7.74\%$) was not significantly different as compared to other groups ($127.86 \pm 11.63\%$, $132.11 \pm 18.87\%$, $143.51 \pm 8.17\%$, $128.24 \pm 16.78\%$ in gel base-treated, 0.05%, 0.1% and 0.5% ECa 233 gel treated-groups, respectively) (Figure 4.15).

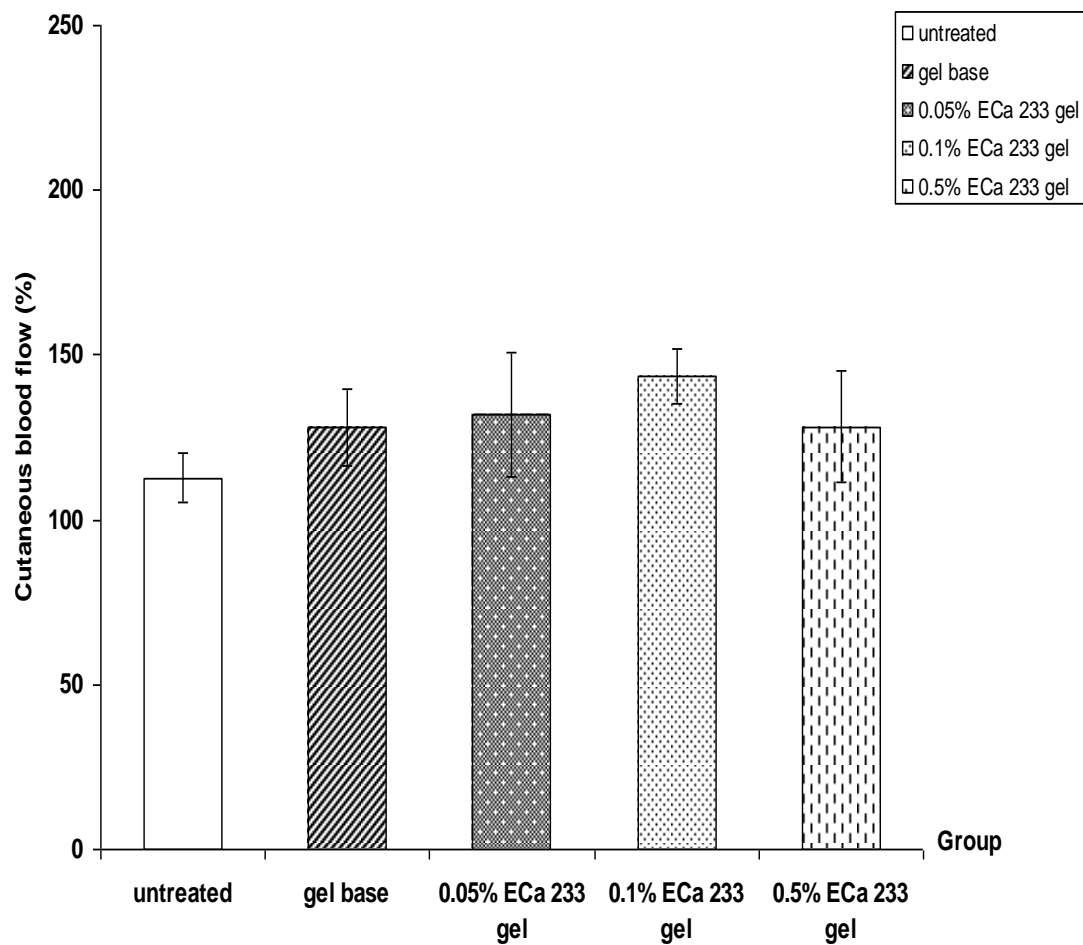


Figure 4.15 Cutaneous blood flow on day 14 post burning in normal rats : untreated, gel base, 0.05% ECa 233 gel, 0.1% ECa 233 gel, 0.5% ECa 233 gel treated groups.

The data is presented as mean \pm S.E.M. (n=6).

4.3.2 Diabetic rats

4.3.2.1 Cutaneous blood flow on day 3

On day 3 post burning in diabetic rats, cutaneous blood flow of only 0.05% ECa 233 gel-treated group ($143.56 \pm 14.04\%$) was significantly different from gel base-treated group ($115.52 \pm 4.88\%$) but not significantly different from untreated group ($119.17 \pm 4.55\%$). The cutaneous blood flow of 0.1% ($125.04 \pm 8.22\%$) and 0.5% ($123.84 \pm 8.16\%$) ECa 233 gel-treated groups were not significantly different from untreated and gel base-treated groups (Figure 4.16).

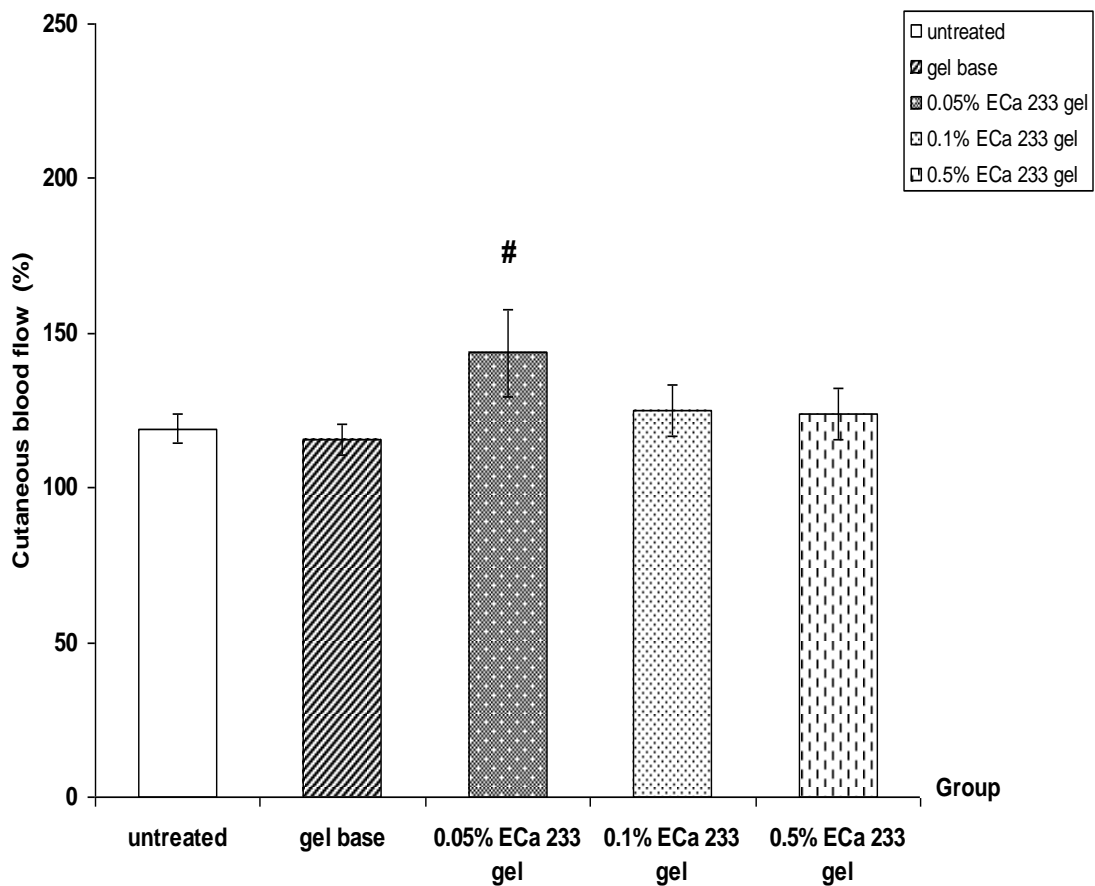


Figure 4.16 Cutaneous blood flow on day 3 post burning in diabetic rats : untreated, gel base, 0.05% ECa 233 gel, 0.1% ECa 233 gel, 0.5% ECa 233 gel treated groups.

The data is presented as mean \pm S.E.M. (n=6).

$p < 0.05$ denotes statistically significant difference from gel base-treated group.

4.3.2.2 Cutaneous blood flow on day 7

On day 7 post burning in diabetic rats, cutaneous blood flow of only the 0.05% ECa 233 gel-treated group ($153.90 \pm 4.68\%$) was significantly different compared to untreated group ($122.21 \pm 9.56\%$), gel base-treated group ($123.28 \pm 7.15\%$) and 0.5% ECa 233 gel-treated group ($130.04 \pm 8.89\%$). The cutaneous blood flow of 0.1% ECa 233 gel-treated group ($136.12 \pm 9.99\%$) was not significantly different from untreated and gel base-treated groups (Figure 4.17).

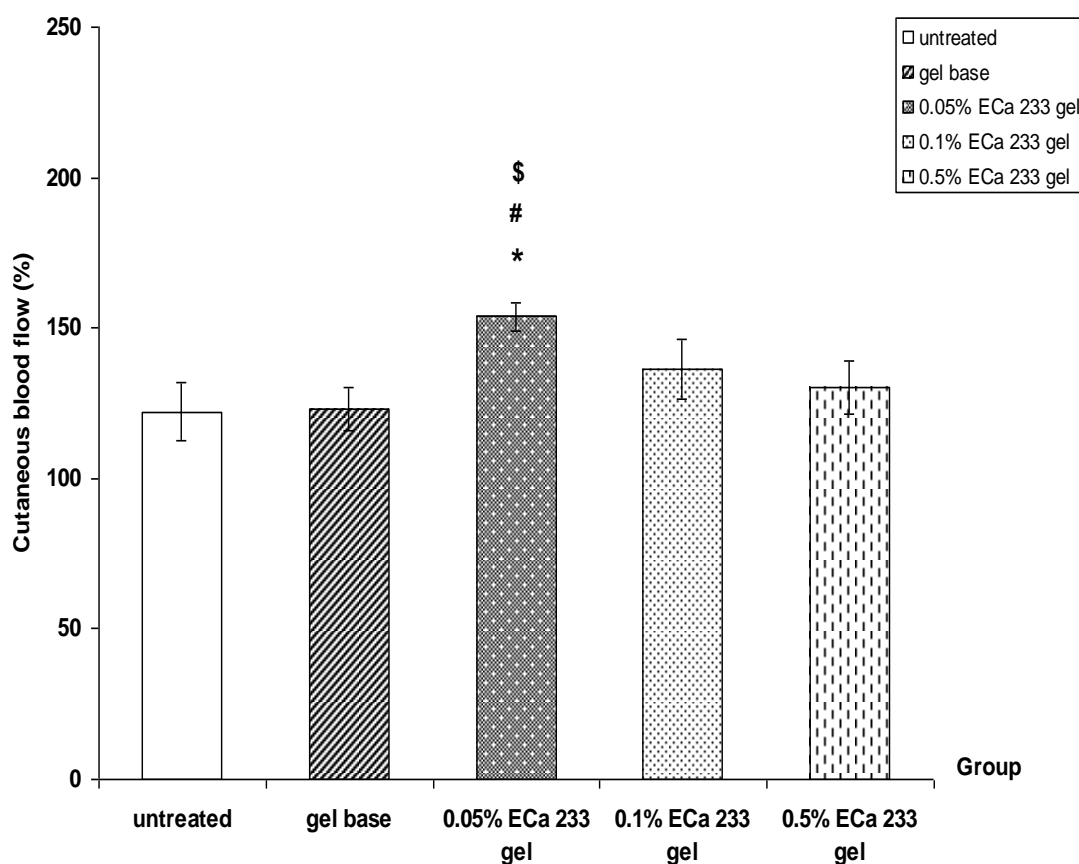


Figure 4.17 Cutaneous blood flow on day 7 post burning in diabetic rats : untreated, gel base, 0.05% ECa 233 gel, 0.1% ECa 233 gel, 0.5% ECa 233 gel treated groups.

The data is presented as mean \pm S.E.M. (n=6).

* $p < 0.05$ denotes statistically significant difference from untreated group.

$p < 0.05$ denotes statistically significant difference from gel base-treated group.

\$ $p < 0.05$ denotes statistically significant difference from 0.5% ECa 233-treated group.

4.3.2.3 Cutaneous blood flow on day 14

On day 14 post burning in diabetic rats, cutaneous blood flow of only the 0.05% ECa 233 gel-treated group ($139.76 \pm 10.29\%$) was significantly different from untreated group ($101.63 \pm 6.04\%$). The cutaneous blood flow of each groups ($121.63 \pm 9.13\%$, $125.15 \pm 16.71\%$, $126.40 \pm 12.88\%$ in gel base-treated, 0.1% and 0.5% ECa 233 gel- treated groups) were not significantly different from untreated group (Figure 4.18).

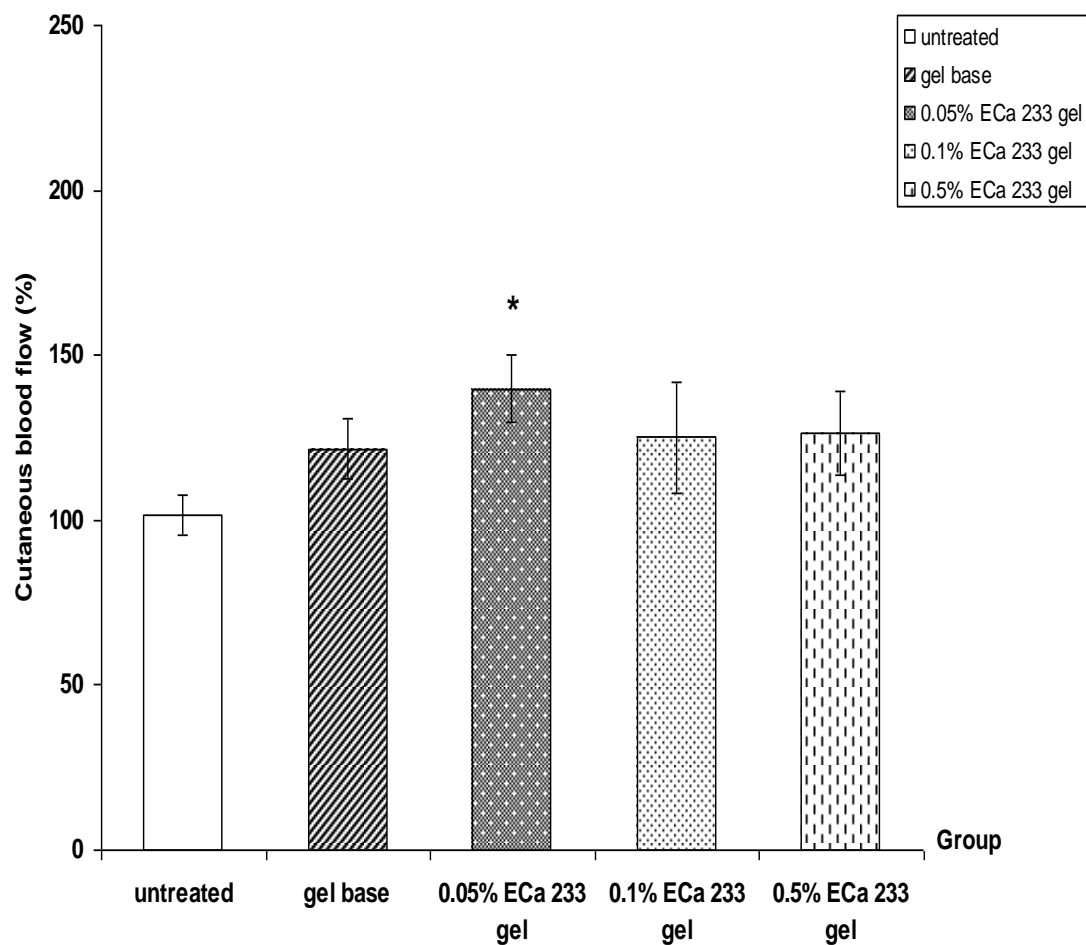


Figure 4.18 Cutaneous blood flow on day 7 post burning in diabetic rats : untreated, gel base, 0.05% ECa 233 gel, 0.1% ECa 233 gel, 0.5% ECa 233 gel treated groups.

The data is presented as mean \pm S.E.M. (n=6).

* $p < 0.05$ denotes statistically significant difference from untreated group.

4.3 Effects of ECa 233 on lipid peroxidation assay

4.4.1 Normal rats

4.4.1.1 Lipid peroxidation on day 3

The level of malondialdehyde (MDA) in skin after burn injury on day 3 in normal rats, the group of 0.05% ECa 233 gel-treated ($10.87 \pm 1.23 \mu\text{mol/g tissue}$) was significantly different as compared to untreated group ($16.72 \pm 3.11 \mu\text{mol/g tissue}$). However, gel base-treated, 0.1% and 0.5% ECa 233 gel-treated groups (14.36 ± 1.45 , 12.40 ± 1.09 , $14.24 \pm 1.81 \mu\text{mol/g tissue}$) were not significantly different from untreated group (Figure 4.19).

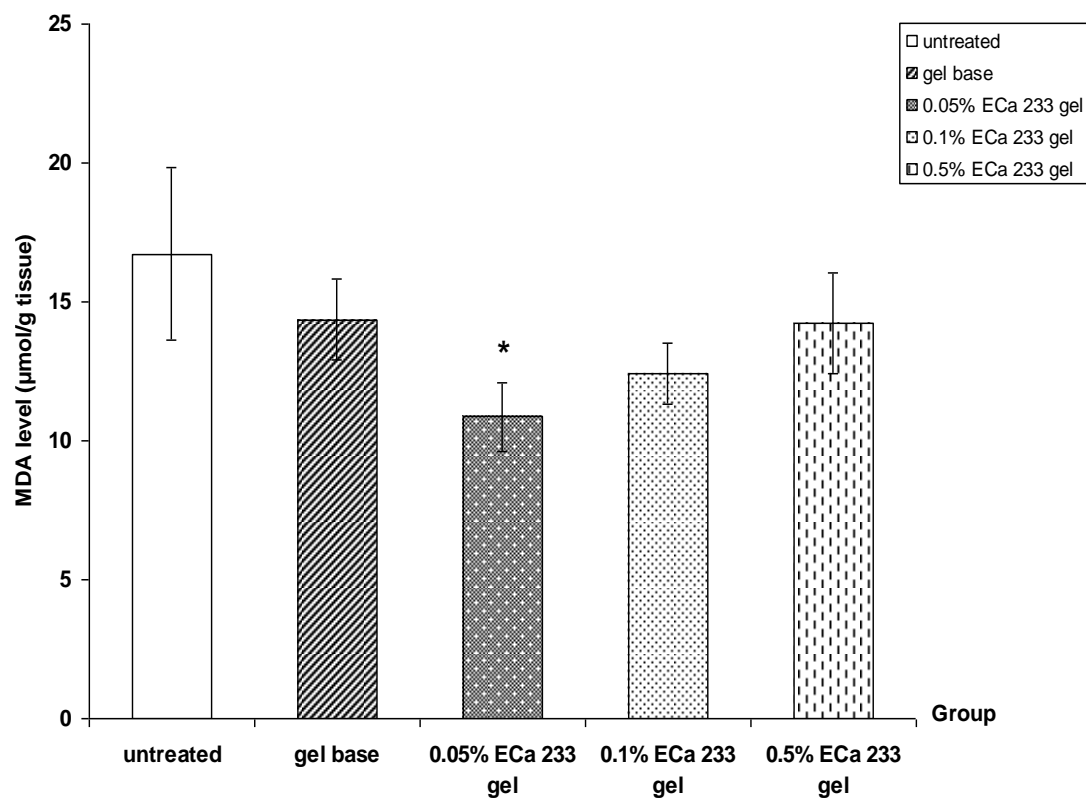


Figure 4.19 Malondialdehyde (MDA) level on day 3 post burning in normal rats : untreated, gel base, 0.05% ECa 233 gel, 0.1% ECa 233 gel, 0.5% ECa 233 gel treated groups. The data is presented as mean \pm S.E.M. (n=6).

* $p < 0.05$ denotes statistically significant difference from untreated group.

4.4.1.2 Lipid peroxidation on day 7

The level of malondialdehyde (MDA) in skin after burn injury on day 7 in normal rats, the group of 0.05% ($7.59 \pm 0.46 \mu\text{mol/g tissue}$), 0.1% ($8.51 \pm 0.73 \mu\text{mol/g tissue}$) and 0.5% ($8.83 \pm 1.74 \mu\text{mol/g tissue}$) ECa 233 gel-treated groups were significantly different as compared to untreated group ($13.73 \pm 1.73 \mu\text{mol/g tissue}$). However, untreated, 0.05%, 0.1% and 0.5% ECa 233 gel-treated groups were not significantly different from gel base-treated group ($9.81 \pm 2.23 \mu\text{mol/g tissue}$). Our results showed that ECa 233 gel-treated groups inhibited burn induced MDA production in the wound sites (Figure 4.20).

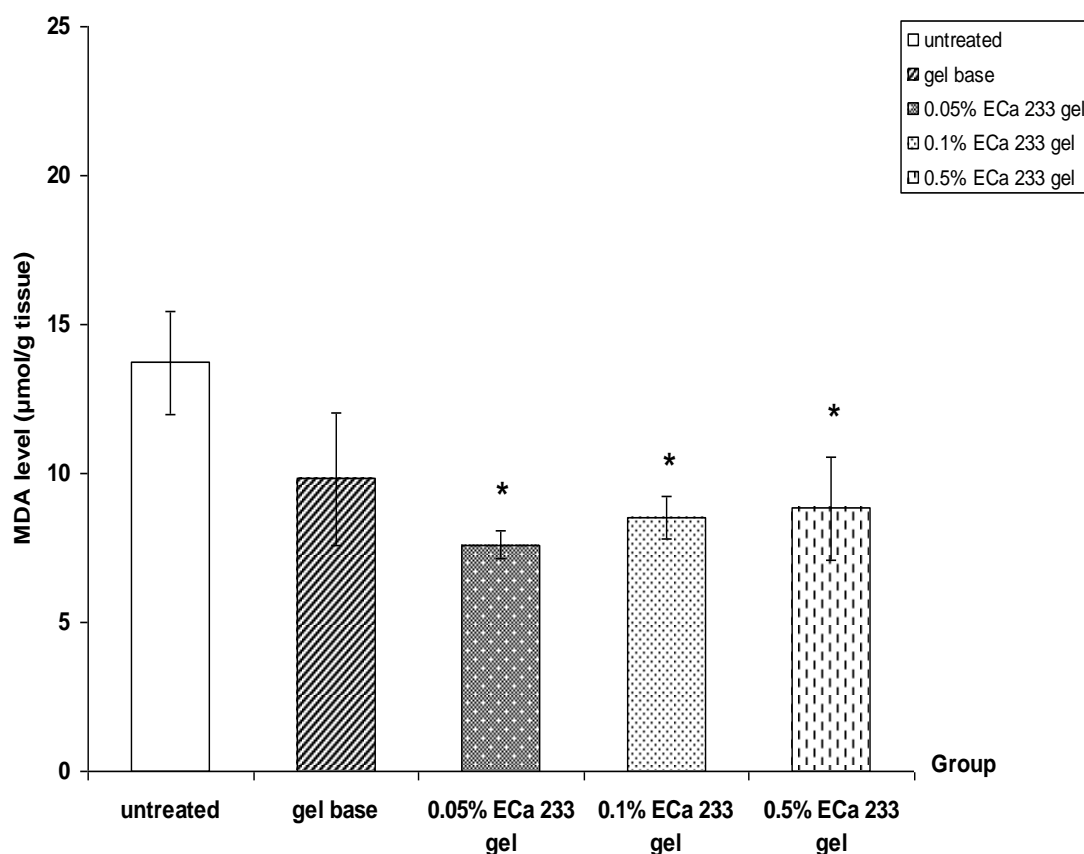


Figure 4.20 Malondialdehyde (MDA) level on day 7 post burning in normal rats : untreated, gel base, 0.05% ECa 233 gel, 0.1% ECa 233 gel, 0.5% ECa 233 gel treated groups. The data is presented as mean \pm S.E.M. (n=6).

* $p < 0.05$ denotes statistically significant difference from untreated group.

4.4.1.3 Lipid peroxidation on day 14

The level of malondialdehyde (MDA) in skin after burn injury on day 14 in normal rats, the group of 0.05% ECa 233 gel-treated group ($4.42 \pm 0.62 \mu\text{mol/g tissue}$) was significantly different as compared to untreated group ($8.06 \pm 1.12 \mu\text{mol/g tissue}$). However, gel base-treated, 0.1% and 0.5% ECa 233 gel-treated groups (6.53 ± 1.24 , 5.86 ± 1.66 , $5.52 \pm 0.77 \mu\text{mol/g tissue}$) were not significantly different from untreated group (Figure 4.21).

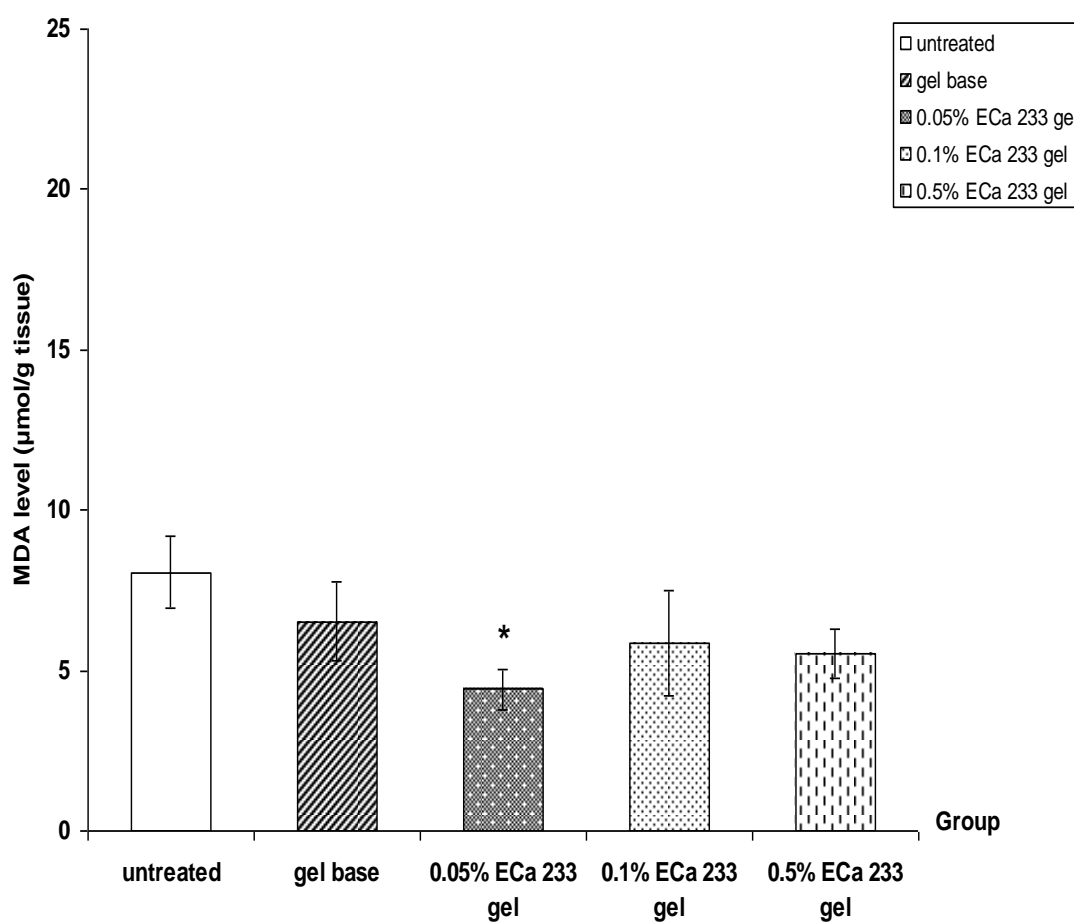


Figure 4.21 Malondialdehyde (MDA) level on day 14 post burning in normal rats : untreated, gel base, 0.05% ECa 233 gel, 0.1% ECa 233 gel, 0.5% ECa 233 gel treated groups. The data is presented as mean \pm S.E.M. (n=6).

* $p < 0.05$ denotes statistically significant difference from untreated group.

4.4.2 Diabetic rats

4.4.2.1 Lipid peroxidation on day 3

The level of malondialdehyde (MDA) in skin after burn injury on day 3 in diabetic rats, MDA level of each groups were not significantly different as compared to untreated group (8.34 ± 1.36 , 6.33 ± 0.97 , 5.33 ± 0.80 , 5.80 ± 1.00 , 5.58 ± 0.87 $\mu\text{mol/g}$ tissue in untreated, gel base-treated, 0.05%, 0.1% and 0.5% ECa 233 gel-treated groups, respectively) (Figure 4.22).

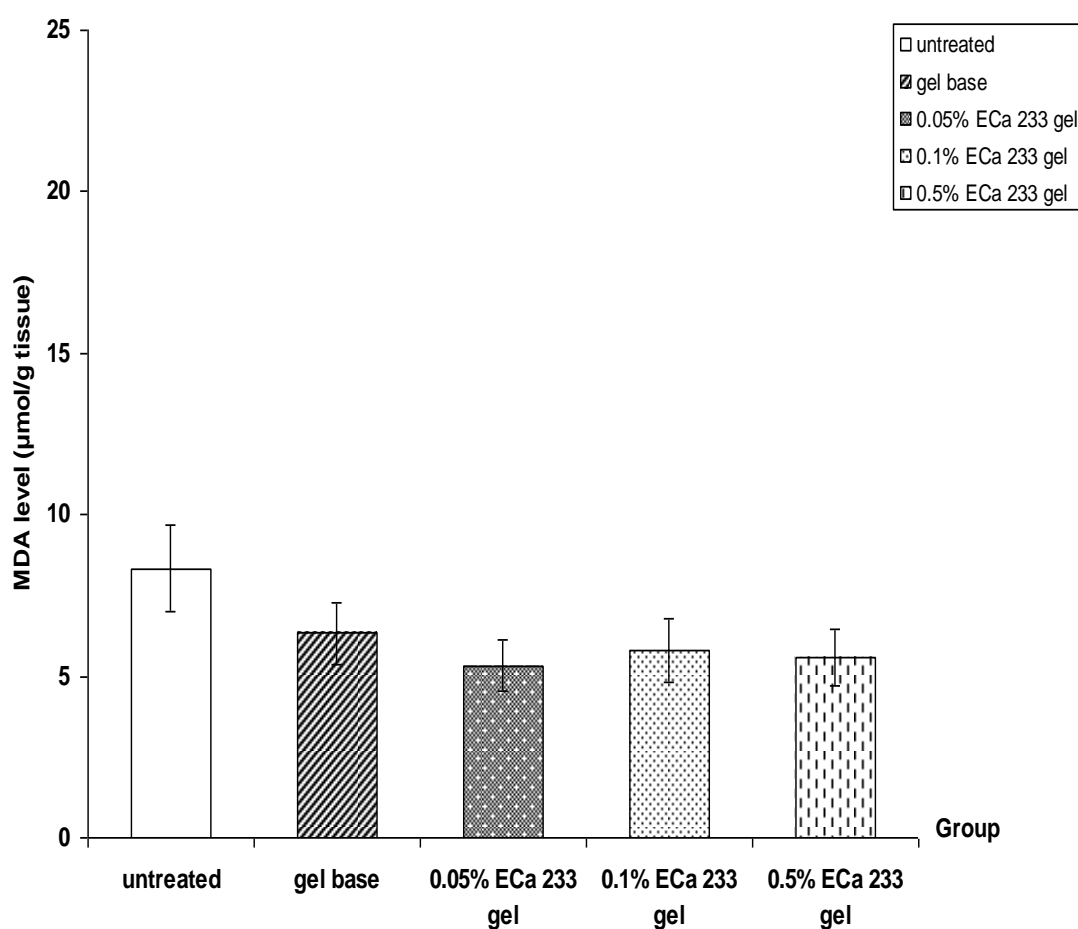


Figure 4.22 Malondialdehyde (MDA) level on day 3 post burning in diabetic rats : untreated, gel base, 0.05% ECa 233 gel, 0.1% ECa 233 gel, 0.5% ECa 233 gel treated groups. The data is presented as mean \pm S.E.M. (n=6).

4.4.2.2 Lipid peroxidation on day 7

The level of malondialdehyde (MDA) in skin after burn injury on day 7 in diabetic rats, MDA level of each groups were not significantly different as compared to untreated group (9.78 ± 0.91 , 9.46 ± 1.77 , 8.43 ± 0.88 , 8.47 ± 1.03 , 8.49 ± 1.15 $\mu\text{mol/g}$ tissue in untreated, gel base-treated, 0.05%, 0.1% and 0.5% ECa 233 gel-treated groups, respectively) (Figure 4.23).

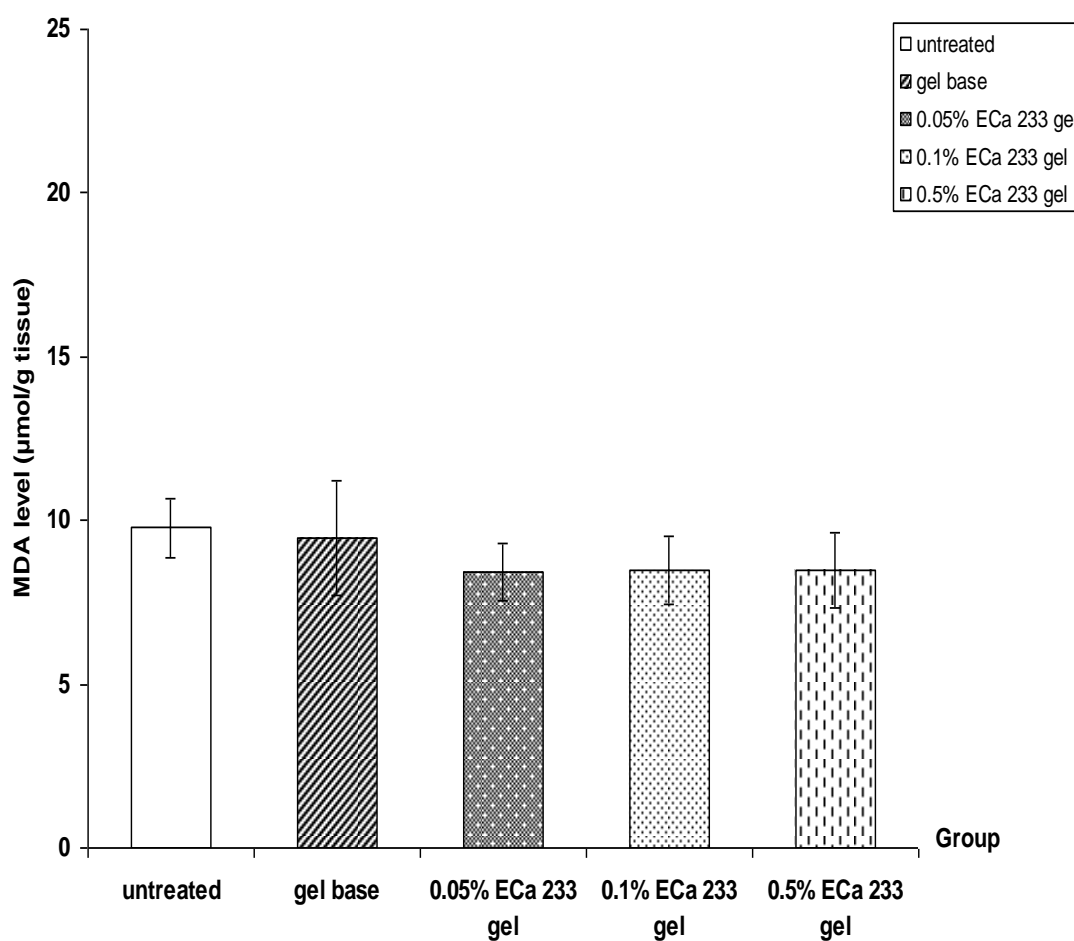


Figure 4.23 Malondialdehyde (MDA) level on day 7 post burning in diabetic rats : untreated, gel base, 0.05% ECa 233 gel, 0.1% ECa 233 gel, 0.5% ECa 233 gel treated groups. The data is presented as mean \pm S.E.M. (n=6).

4.4.2.3 Lipid peroxidation on day 14

The level of malondialdehyde (MDA) in skin after burn injury on day 14 in diabetic rats, 0.05% ($6.16 \pm 0.89 \mu\text{mol/g tissue}$), 0.1% ($6.90 \pm 1.15 \mu\text{mol/g tissue}$) and 0.5% ($7.46 \pm 0.78 \mu\text{mol/g tissue}$) ECa 233 gel-treated groups were significantly different as compared to untreated ($10.75 \pm 1.48 \mu\text{mol/g tissue}$) and gel base-treated groups ($13.40 \pm 1.28 \mu\text{mol/g tissue}$). However, the level of MDA in untreated group was not significantly different from gel base-treated group (Figure 4.24).

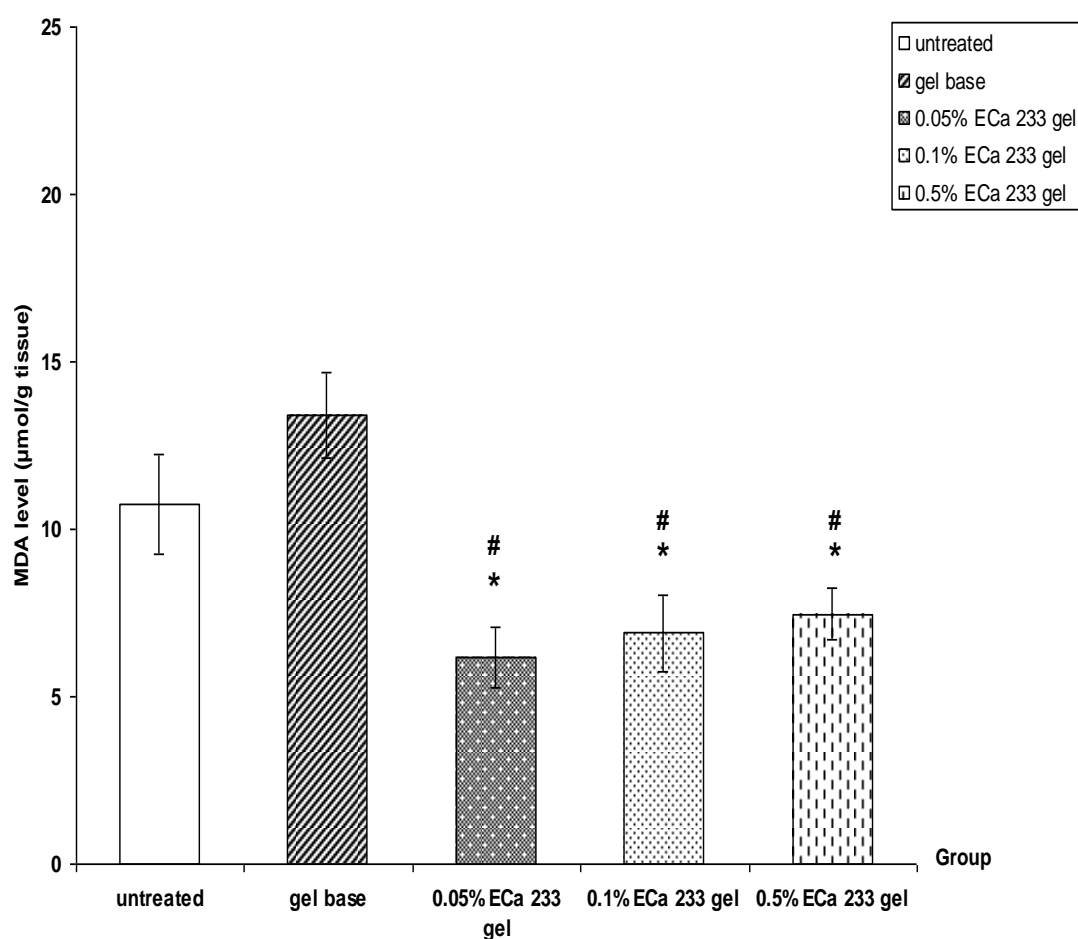


Figure 4.24 Malondialdehyde (MDA) level on day 14 post burning in diabetic rats : untreated, gel base, 0.05% ECa 233 gel, 0.1% ECa 233 gel, 0.5% ECa 233 gel treated groups. The data is presented as mean \pm S.E.M. (n=6).

* $p < 0.05$ denotes statistically significant difference from untreated group.

$p < 0.05$ denotes statistically significant difference from gel base-treated group.

4.5 Histopathological observation

Histopathological observation of wound healing in this study was examined on day 3, 7 and 14 post burning in normal and diabetic rats.

4.5.1 Histopathological observation in normal rats

On day 3 post burning, the untreated and gel base-treated groups demonstrated damage in epidermis, dermis and increased of inflammatory cell infiltrate distributed across the adipose tissue and necrosis of blood vessels. The wound in all ECa 233 gel-treated groups showed no vasculitis and fewer leukocytic infiltration (Figure 4.25).

On day 7 post burning, the untreated and gel base-treated groups demonstrated damage in epidermis and dermis. All ECa 233 gel-treated groups showed a prominent angiogenesis, fibroblast and keratinocytes migrate into the wound bed from surrounding tissue. There was decrease inflammation (Figure 4.26).

On day 14 post burning, in all ECa 233 gel-treated groups showed fully developed epithelialization and keratinization. Skin appendages can be observed near to normal skin. In addition to, hair formation was also noted in 0.05% ECa 233 gel-treated group (Figure 4.27).

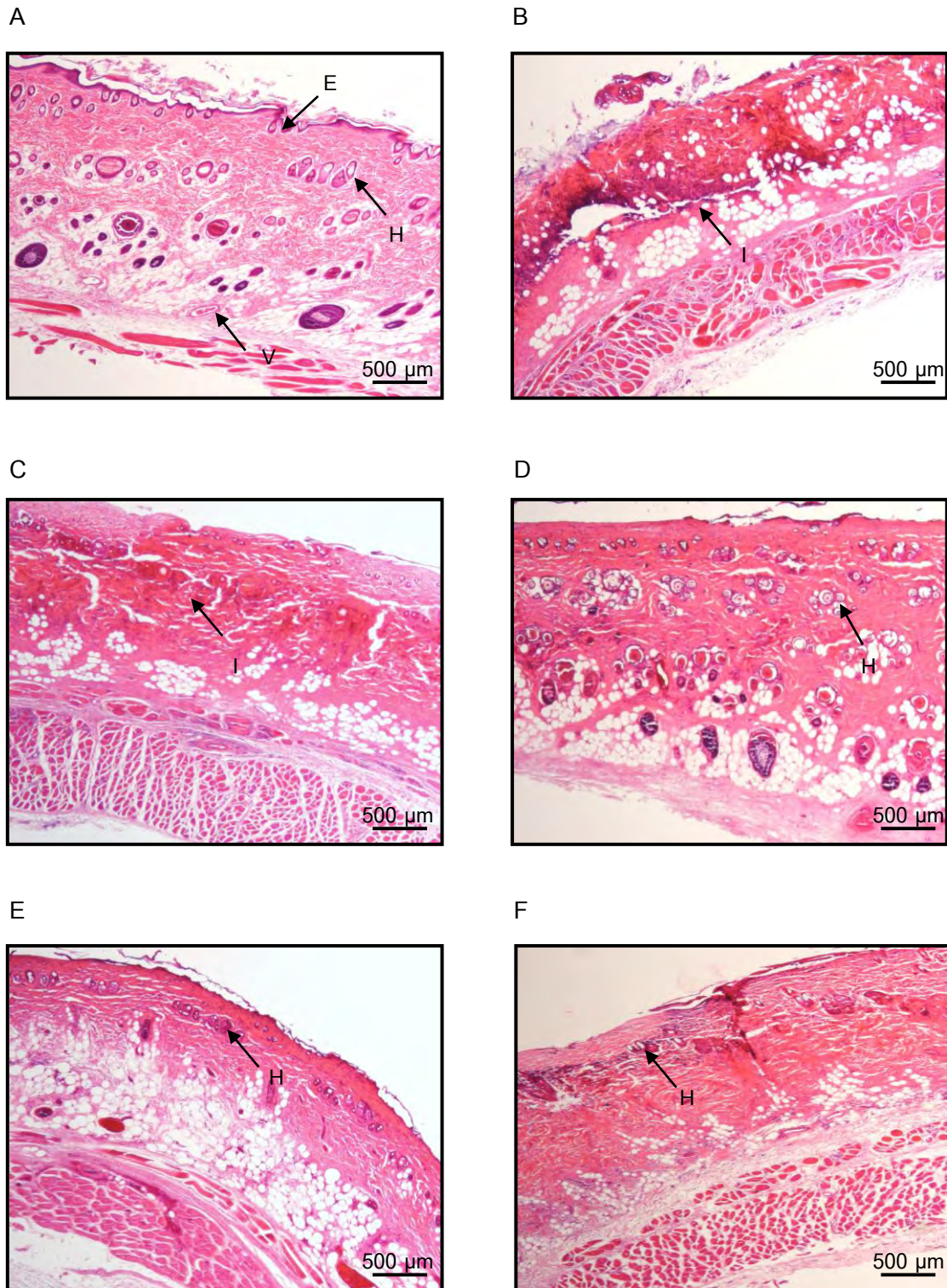


Figure 4.25 Hematoxylin-eosin stains. Histopathological change of skin section on day 3 post burning in normal rats. A) no burn B) untreated wound C) burn treated gel base D) burn treated 0.05% ECa 233 gel E) burn treated 0.1% ECa 233 gel F) burn treated 0.5% ECa 233 gel
E = epidermis, H = hair follicle, I = inflammatory cell, V = vessel (objective lens x4)

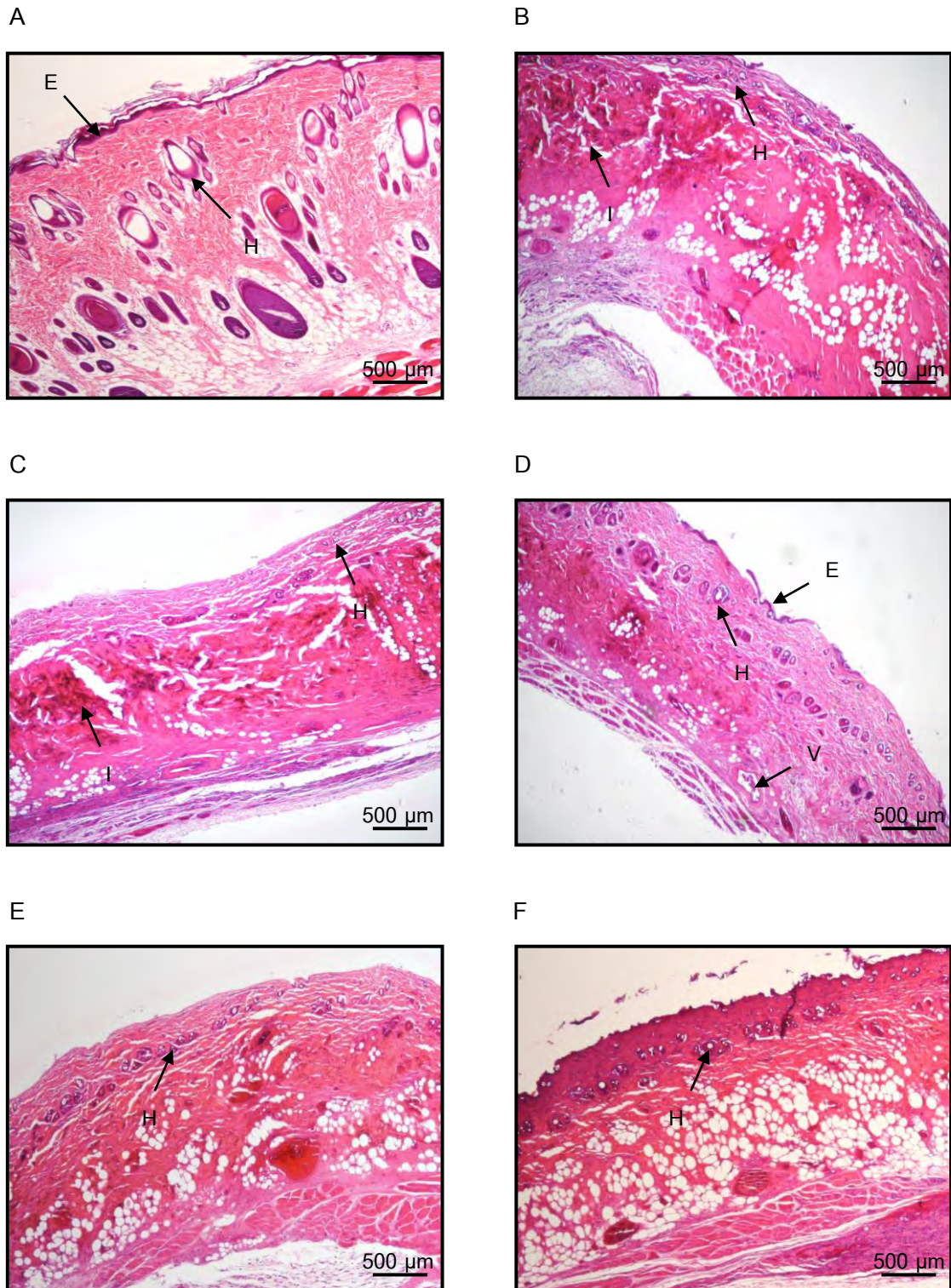


Figure 4.26 Hematoxylin-eosin stains. Histopathological change of skin section on day 7 post burning in normal rats. A) no burn B) untreated wound C) burn treated gel base D) burn treated 0.05% ECa 233 gel E) burn treated 0.1% ECa 233 gel F) burn treated 0.5% ECa 233 gel

E = epidermis, H = hair follicle, I = inflammatory cell, V = vessel (objective lens x4)

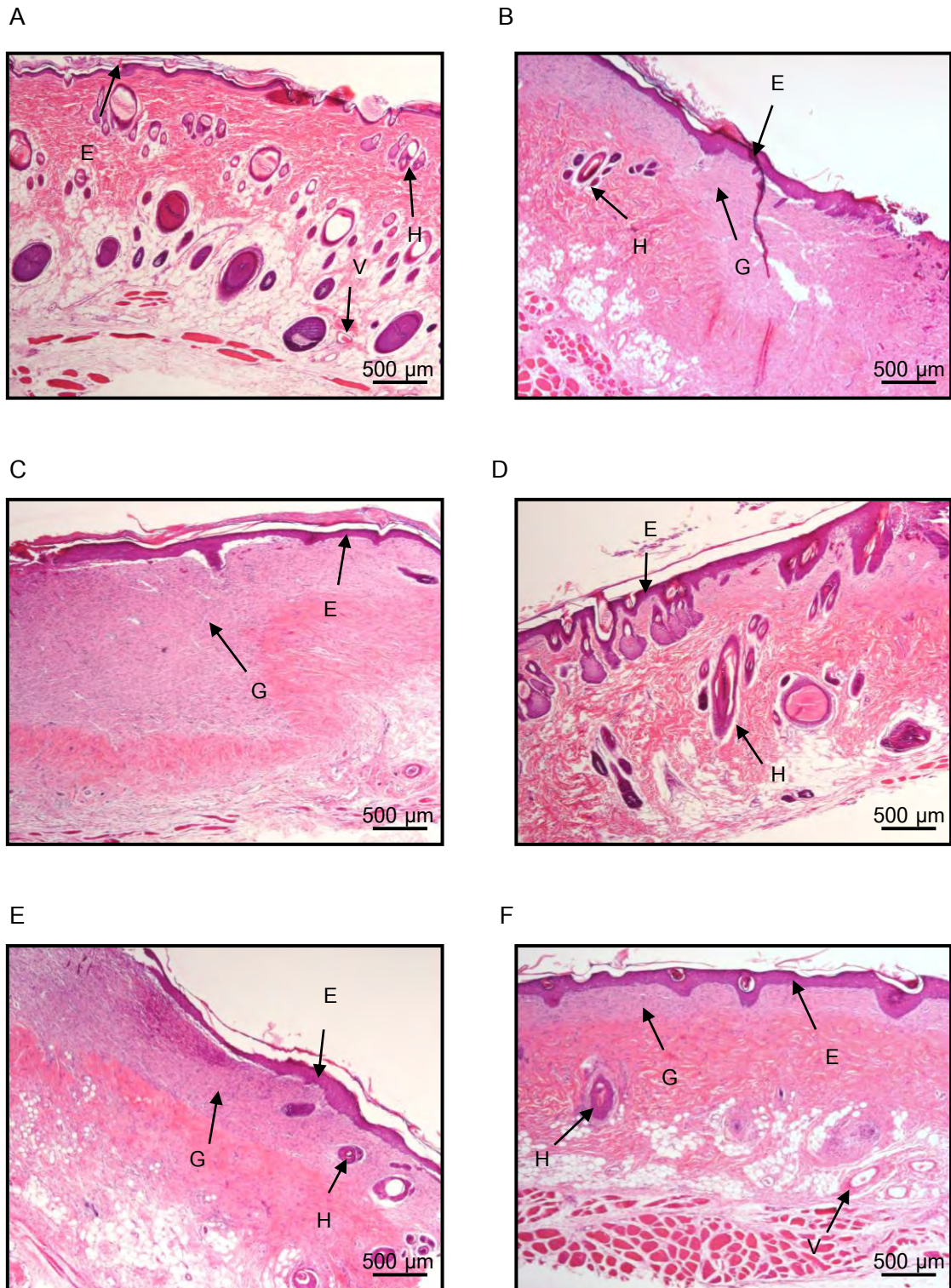


Figure 4.27 Hematoxylin-eosin stains. Histopathological change of skin section on day 14 post burning in normal rats. A) no burn B) untreated wound C) burn treated gel base D) burn treated 0.05% ECa 233 gel E) burn treated 0.1% ECa 233 gel F) burn treated 0.5% ECa 233 gel
 E = epidermis, H = hair follicle, G = granulation tissue, V = vessel (objective lens x4)

4.5.2 Histopathological observation in diabetic rats

Histopathological observation of wound healing in this study was examined on day 3, 7 and 14 post burning in diabetic rats.

On day 3 post burning, the burn wound in untreated and gel base-treated groups demonstrated an increased of inflammatory cells distributed across the adipose tissue and in the underlying skeletal muscle tissue. In addition, necrosis of blood vessels. The wound in all ECa 233 gel-treated groups showed no vasculitis and fewer leukocytic infiltration (Figure 4.28).

On day 7 post burning, damage of epidermis and dermis was observed in untreated and gel base-treated groups. Fewer leukocytic infiltration than those found on day 3 was noted. In all ECa 233 gel-treated groups showed a prominent angiogenesis, fibroblast and keratinocytes migrate into the wound bed from surrounding tissue. There was decreased inflammation (Figure 4.29).

On day 14 post burning, in all ECa 233 gel-treated group showed fully developed epithelialization and keratinization. Skin appendages can be observed near to normal skin and hair formation was also noted in 0.05% ECa 233 gel-treated group (Figure 4.30).

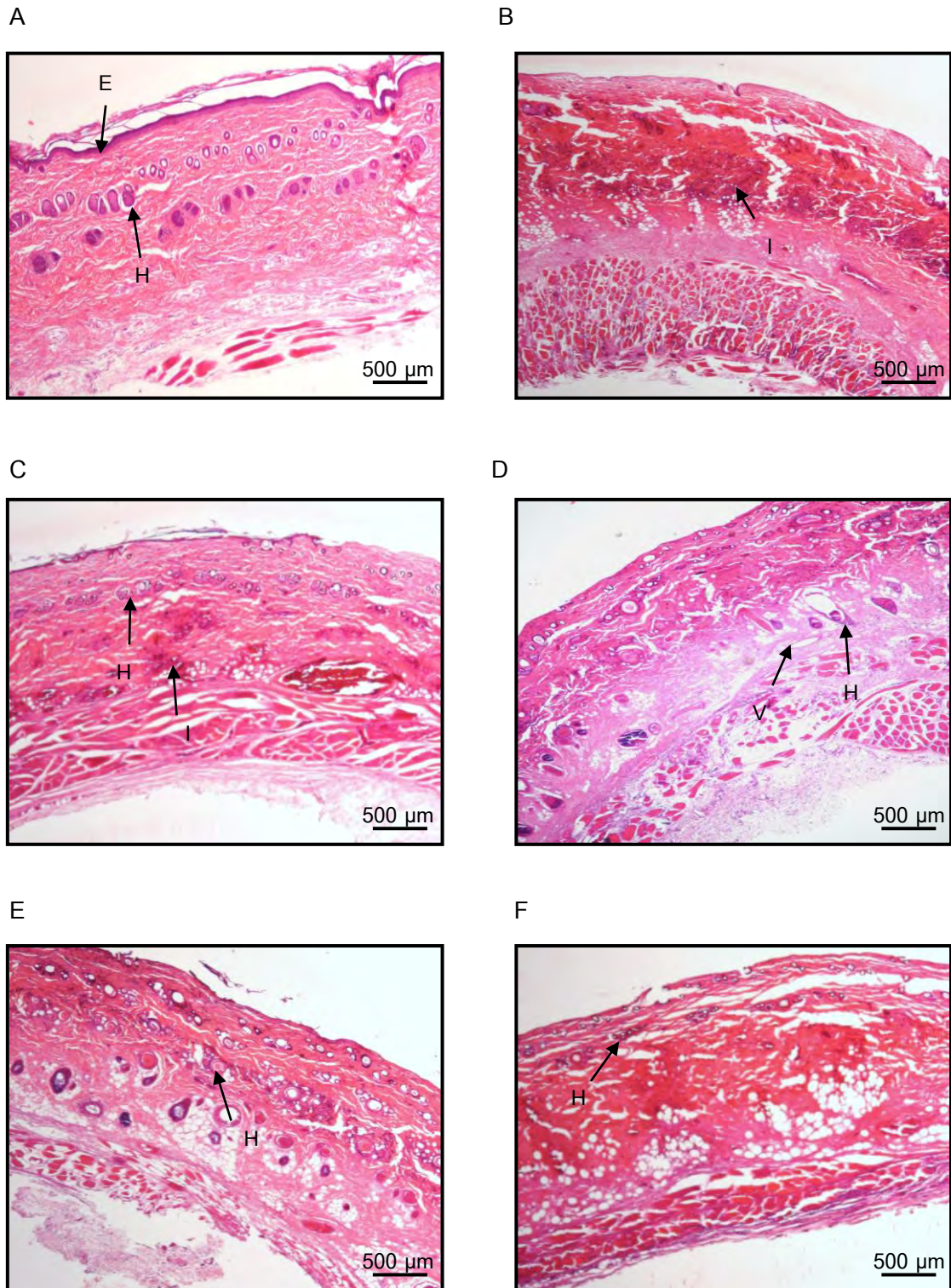


Figure 4.28 Hematoxylin-eosin stains. Histopathological change of skin section on day 3 post burning in diabetic rats. A) no burn B) untreated wound C) burn treated gel base D) burn treated 0.05% ECa 233 gel E) burn treated 0.1% ECa 233 gel F) burn treated 0.5% ECa 233 gel

E = epidermis, H = hair follicle, I = inflammatory cell, V= vessel (objective lens x4)

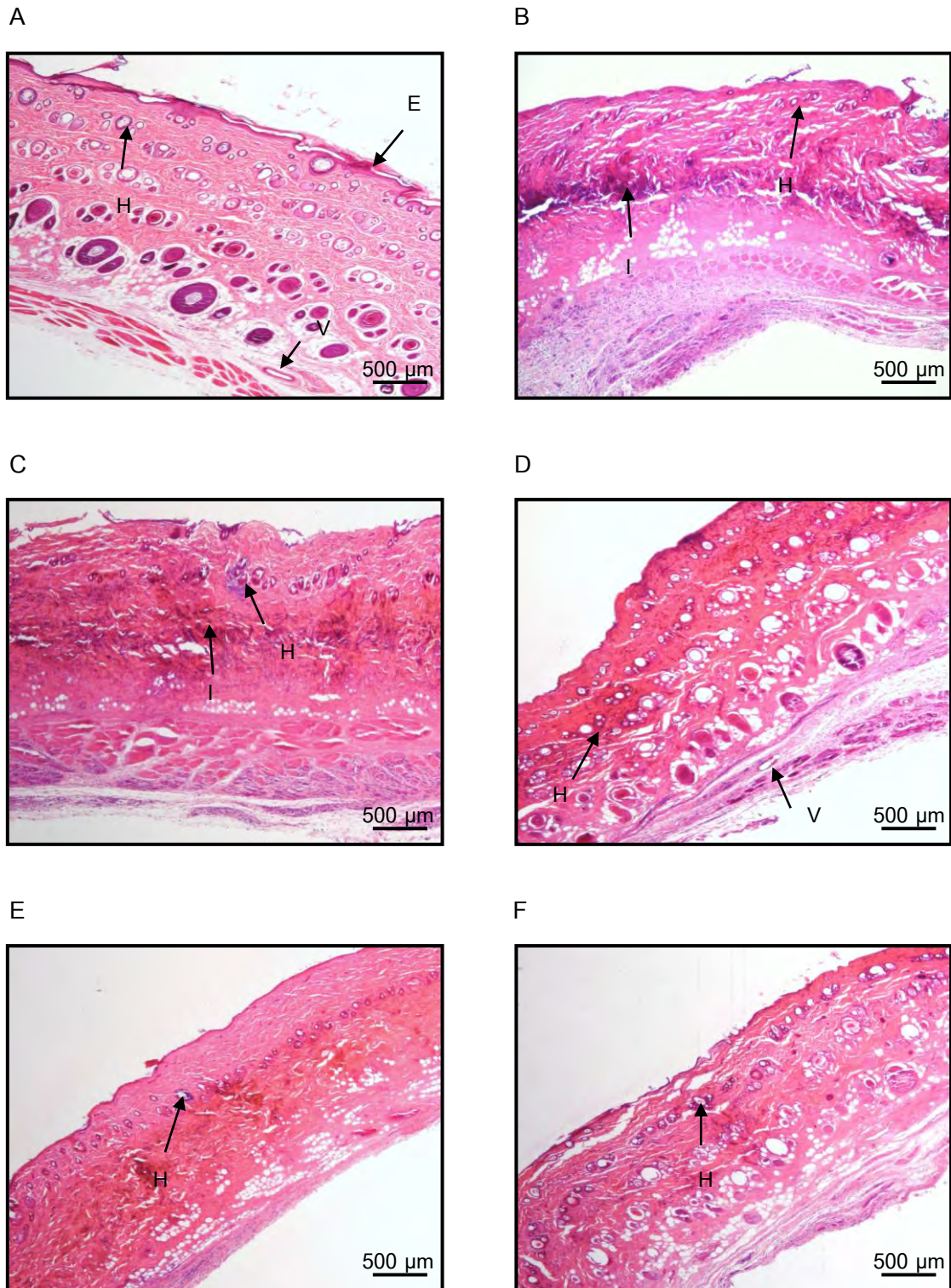


Figure 4.29 Hematoxylin-eosin stains. Histopathological change of skin section on day 7 post burning in diabetic rats. A) no burn B) untreated wound C) burn treated gel base D) burn treated 0.05% ECa 233 gel E) burn treated 0.1% ECa 233 gel F) burn treated 0.5% ECa 233 gel
E = epidermis, H = hair follicle, I = inflammatory cell, V = vessel (objective lens x4)

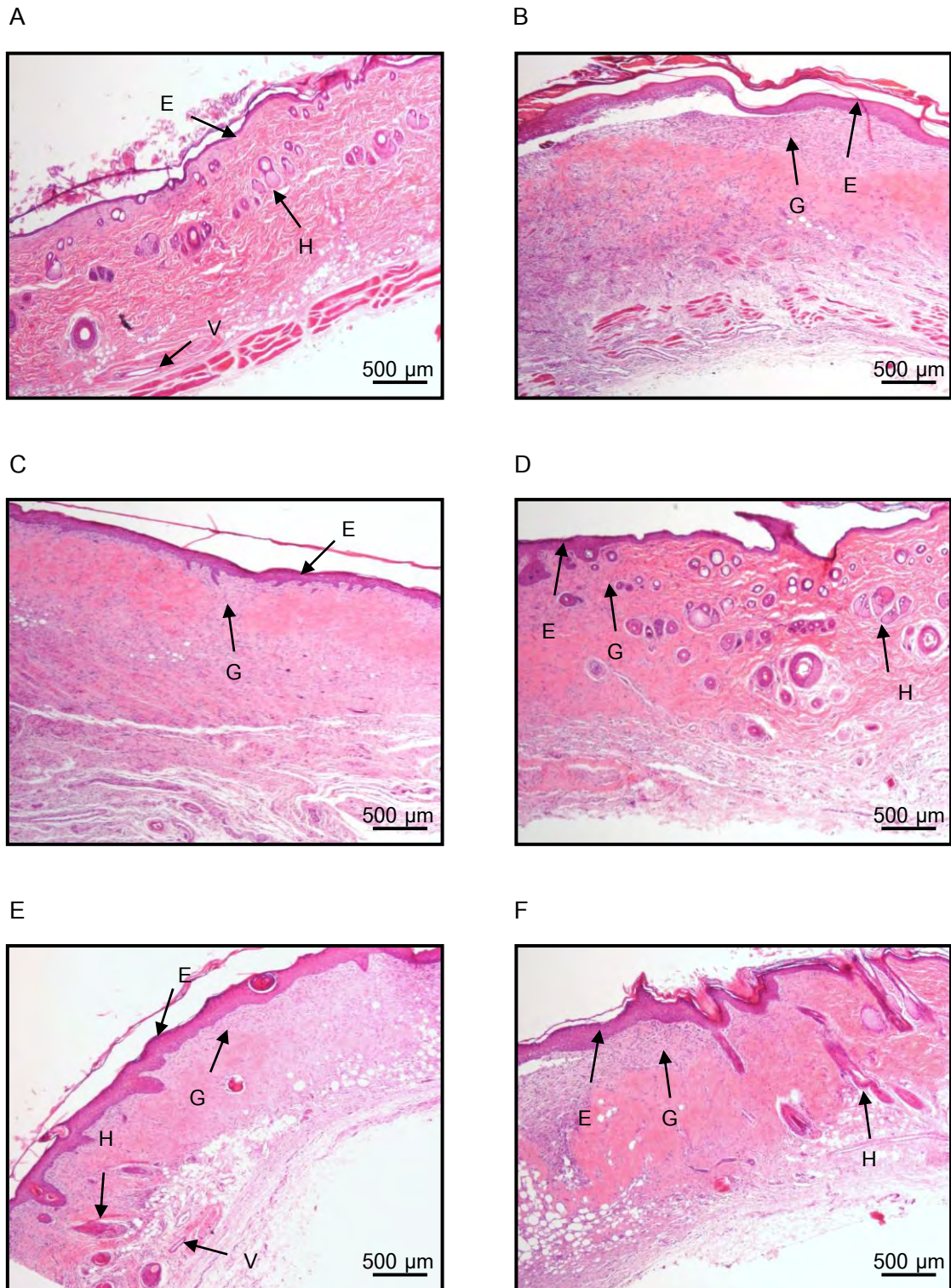


Figure 4.30 Hematoxylin-eosin stains. Histopathological change of skin section on day 14 post burning in diabetic rats. A) no burn B) untreated wound C) burn treated gel base D) burn treated 0.05% ECa 233 gel E) burn treated 0.1% ECa 233 gel F) burn treated 0.5% ECa 233 gel E = epidermis, H = hair follicle, G = granulation tissue, V = vessel (objective lens x4)

4.6 Effects of ECa 233 on hair follicles

4.6.1 Normal rats

4.6.1.1 The number of hair follicles per mm^2 on day 3

On day 3 post burning in normal rats, the number of hair follicles of only the 0.05% ECa 233 gel-treated group ($23.11 \pm 3.28/\text{mm}^2$) was significantly different compared to untreated group ($10.96 \pm 2.36/\text{mm}^2$) and gel base-treated group ($13.33 \pm 2.74/\text{mm}^2$). The number of hair follicles of 0.1% ($18.07 \pm 3.23/\text{mm}^2$) and 0.5% ($20.44 \pm 3.64/\text{mm}^2$) ECa 233 gel-treated groups were not significantly different from untreated and gel base-treated groups (Figure 4.31).

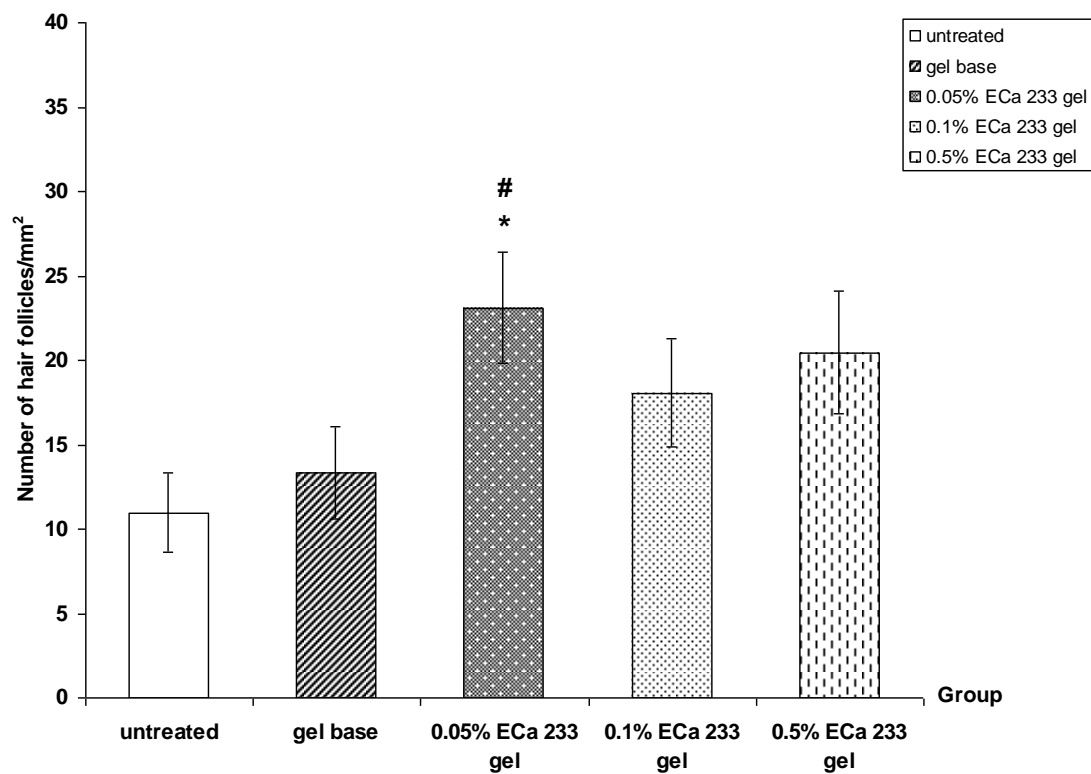


Figure 4.31 The number of hair follicles per mm^2 on day 3 post burning in normal rats : untreated, gel base, 0.05% ECa 233 gel, 0.1% ECa 233 gel, 0.5% ECa 233 gel treated groups. The data is presented as mean \pm S.E.M. (n=6).

* $p < 0.05$ denotes statistically significant difference from untreated group.

$p < 0.05$ denotes statistically significant difference from gel base-treated group.

4.6.1.2 The number of hair follicles per mm² on day 7

On day 7 post burning in normal rats, the number of hair follicles of only the 0.05% ECa 233 gel-treated group ($29.04 \pm 4.12/\text{mm}^2$) was significantly different compared to untreated group ($10.96 \pm 1.55/\text{mm}^2$), gel base-treated group ($12.44 \pm 3.28/\text{mm}^2$) and 0.1% ECa 233 gel-treated group ($17.48 \pm 5.12/\text{mm}^2$). The number of hair follicles of 0.5% ECa 233 gel-treated group ($19.85 \pm 3.42/\text{mm}^2$) was not significantly different from untreated and gel base-treated groups (Figure 4.32).

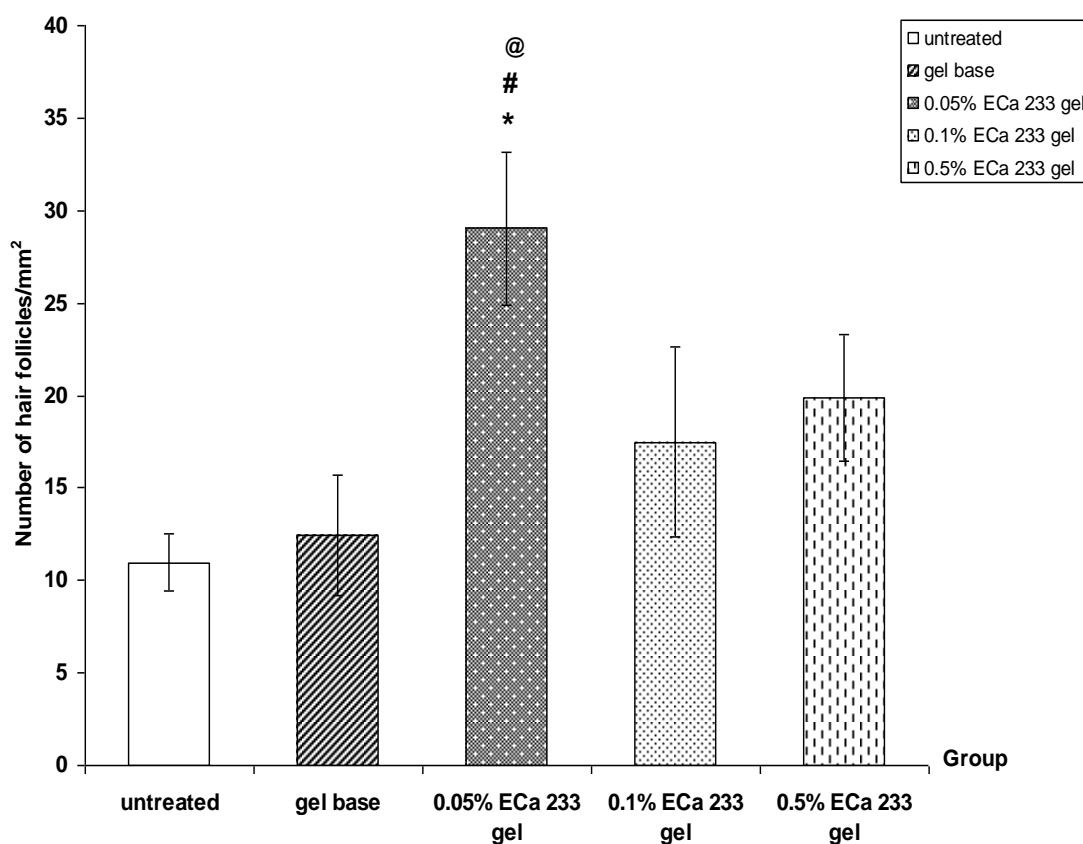


Figure 4.32 The number of hair follicles per mm² on day 7 post burning in normal rats : untreated, gel base, 0.05% ECa 233 gel, 0.1% ECa 233 gel, 0.5% ECa 233 gel treated groups. The data is presented as mean \pm S.E.M. (n=6).

* $p < 0.05$ denotes statistically significant difference from untreated group.

$p < 0.05$ denotes statistically significant difference from gel base-treated group.

@ $p < 0.05$ denotes statistically significant difference from 0.1% ECa 233-treated group.

4.6.1.3 The number of hair follicles per mm² on day 14

On day 14 post burning in normal rats, the number of hair follicles of untreated group ($2.67 \pm 1.70/\text{mm}^2$) was not significantly different as compared to other groups ($3.56 \pm 1.78/\text{mm}^2$, $8 \pm 3.00/\text{mm}^2$, $8 \pm 3.72/\text{mm}^2$, $4.74 \pm 1.35/\text{mm}^2$ in gel base-treated, 0.05%, 0.1% and 0.5% ECa 233 gel-treated groups, respectively) (Figure 4.33).

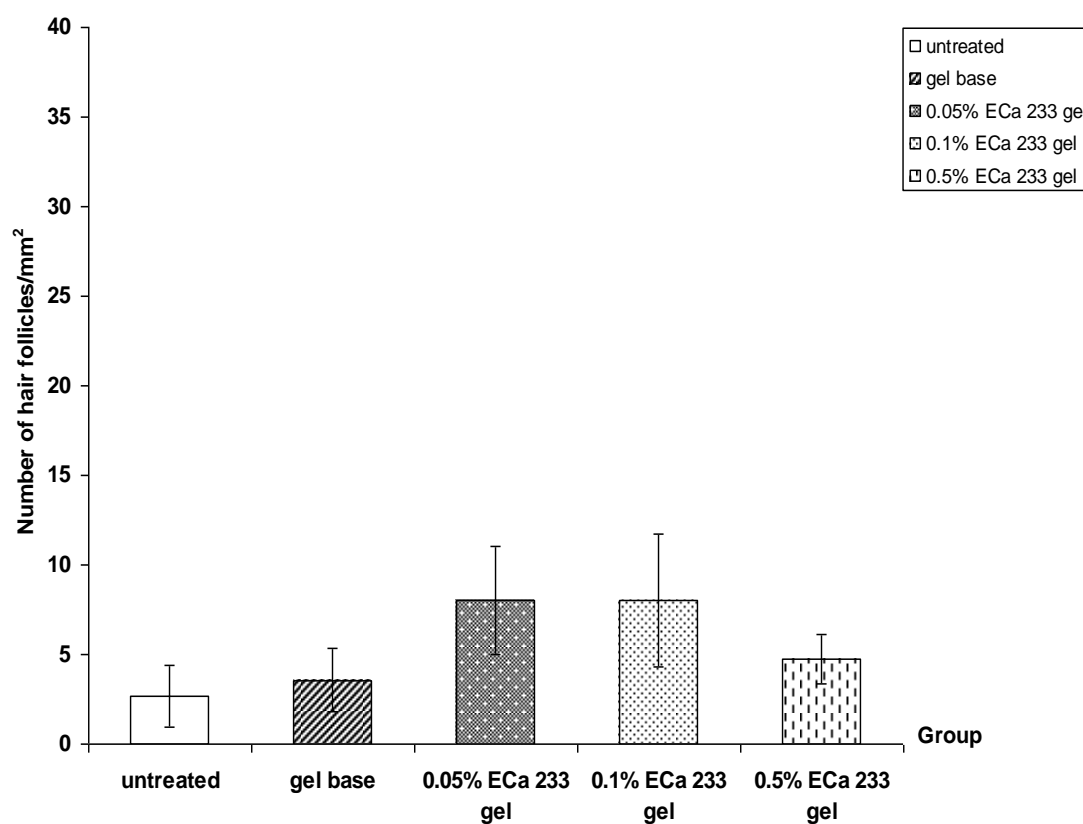


Figure 4.33 The number of hair follicles per mm² on day 14 post burning in normal rats : untreated, gel base, 0.05% ECa 233 gel, 0.1% ECa 233 gel, 0.5% ECa 233 gel treated groups. The data is presented as mean ± S.E.M. (n=6).

4.6.2 Diabetic rats

4.6.2.1 The number of hair follicles per mm^2 on day 3

On day 3 post burning in diabetic rats, the number of hair follicles of each groups ($16.30 \pm 1.68/\text{mm}^2$, $24.59 \pm 1.41/\text{mm}^2$, $20.45 \pm 2.19/\text{mm}^2$, $20.74 \pm 3.33/\text{mm}^2$ in gel base-treated, 0.05%, 0.1% and 0.5% ECa 233 gel-treated groups, respectively) were significantly different compared to untreated group ($8.30 \pm 2.14/\text{mm}^2$). In the 0.05% ECa 233 gel-treated group was significantly different from untreated and gel base-treated groups (Figure 4.34).

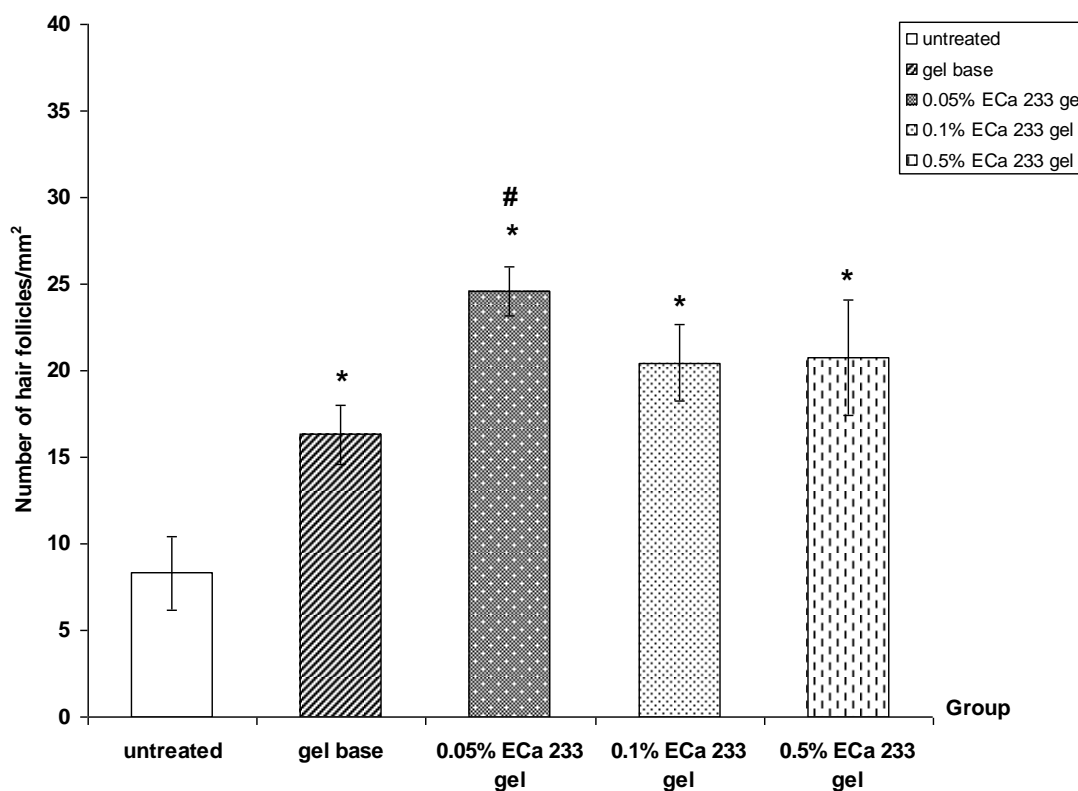


Figure 4.34 The number of hair follicles per mm^2 on day 3 post burning in diabetic rats : untreated, gel base, 0.05% ECa 233 gel, 0.1% ECa 233 gel, 0.5% ECa 233 gel treated groups. The data is presented as mean \pm S.E.M. (n=6).

* $p < 0.05$ denotes statistically significant difference from untreated group.

$p < 0.05$ denotes statistically significant difference from gel base-treated group.

4.6.2.2 The number of hair follicles per mm² on day 7

On day 7 post burning in diabetic rats, the number of hair follicles of only the 0.05% ECa 233 gel-treated group ($29.04 \pm 5.69/\text{mm}^2$) was significantly different compared to untreated group ($10.96 \pm 2.36/\text{mm}^2$) and gel base-treated group ($11.56 \pm 2.04/\text{mm}^2$). In the 0.1% ($17.78 \pm 2.60/\text{mm}^2$) and 0.5% ($21.93 \pm 6.97/\text{mm}^2$) ECa 233 gel-treated groups were not significantly different from untreated and gel base-treated groups (Figure 4.35).

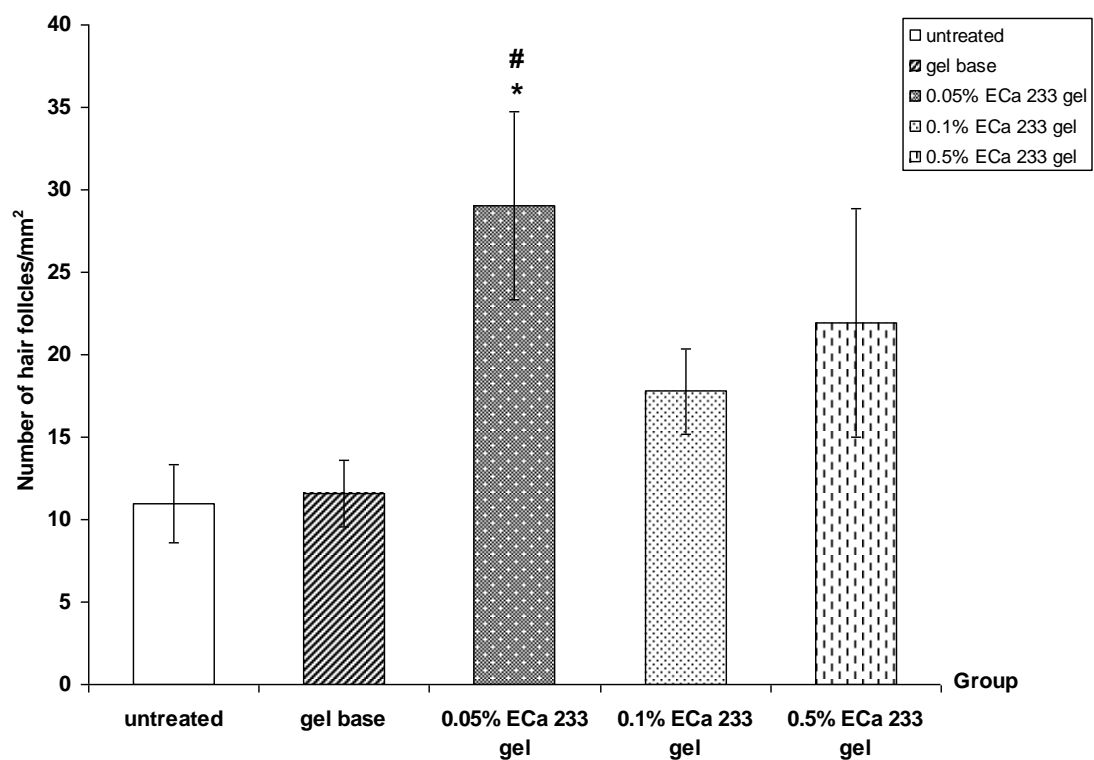


Figure 4.35 The number of hair follicles per mm² on day 7 post burning in diabetic rats : untreated, gel base, 0.05% ECa 233 gel, 0.1% ECa 233 gel, 0.5% ECa 233 gel treated groups. The data is presented as mean ± S.E.M. (n=6).

* $p < 0.05$ denotes statistically significant difference from untreated group.

$p < 0.05$ denotes statistically significant difference from gel base-treated group.

4.6.2.3 The number of hair follicles per mm² on day 14

On day 14 post burning in diabetic rats, the number of hair follicles of untreated group ($4.74 \pm 4.74/\text{mm}^2$) was not significantly different as compared to other groups ($6.82 \pm 2.07/\text{mm}^2$, $14.82 \pm 7.72/\text{mm}^2$, $18.96 \pm 7.88/\text{mm}^2$, $11.85 \pm 3.66/\text{mm}^2$ in gel base-treated, 0.05%, 0.1% and 0.5% ECa 233 gel-treated groups, respectively) (Figure 4.36).

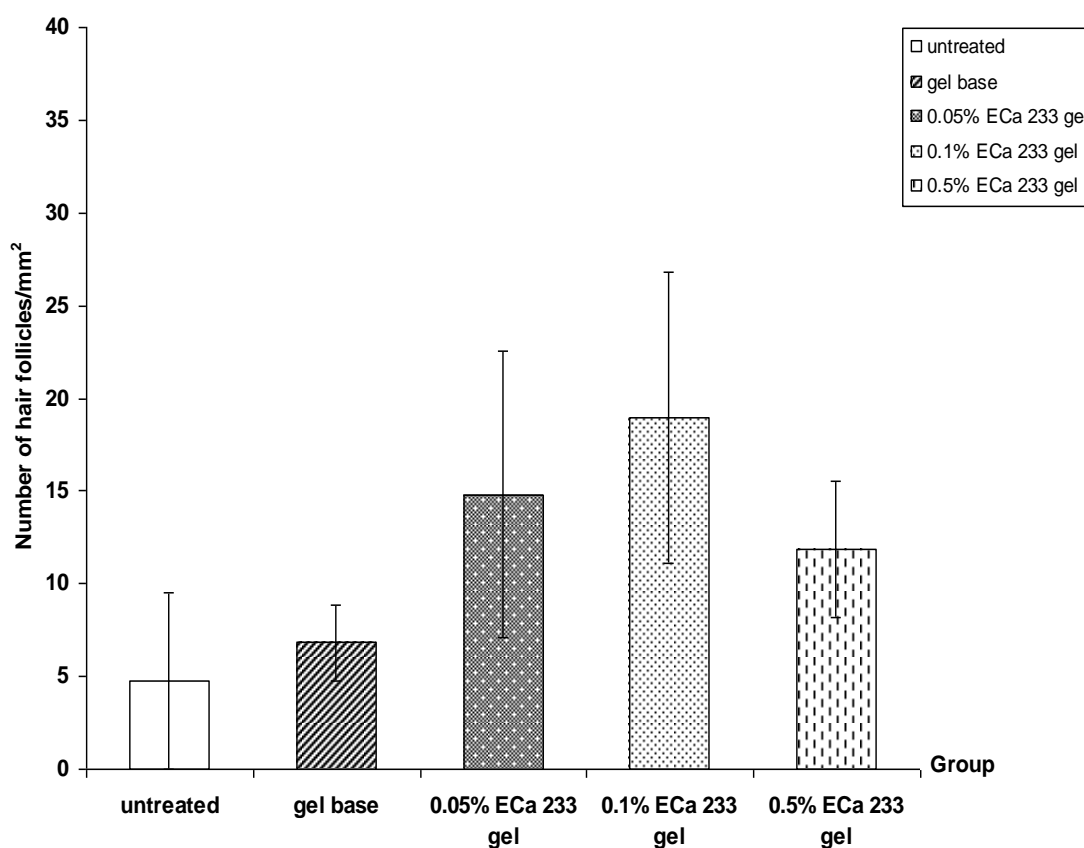


Figure 4.36 The number of hair follicles per mm² on day 14 post burning in diabetic rats : untreated, gel base, 0.05% ECa 233 gel, 0.1% ECa 233 gel, 0.5% ECa 233 gel treated groups. The data is presented as mean \pm S.E.M. (n=6).

CHAPTER V

DISCUSSION AND CONCLUSION

The present study demonstrated the wound healing effects of topically applied standardized extract of *Centella asiatica* ECa 233 on burn wound model in normal and Streptozotocin (STZ)-induced diabetic rats. Evaluation of wound healing was made by estimation of rate of wound healing, measurement of cutaneous blood flow, the level of malondialdehyde (MDA) and histopathological observation were performed at day 3, 7 and 14 post burning.

In burn wound, microcirculation is generally compromised to the worst extent at around 12-24 h post burn [60] resulting in a restriction or cessation of blood flow which in turn causes ischemia and subsequently a reperfusion and thus a generation of oxidative stress [89]. Intervention that could restore blood flow or scavenging the free radicals should, in principle reduce the damage due to oxidative stress [60, 90, 91].

In normal rats, on day 3 post burning, despite an increase in cutaneous blood flow in all groups except untreated group. Rate of wound healing in 0.05% and 0.1% ECa 233 gel-treated group were significantly higher than those of other groups. The wound in all ECa 233 gel-treated groups showed a mild degree of swelling and wound surface was rather dry and smooth. In comparison to, the wound in untreated and gel base-treated groups become swelling and exudated. A sign of inflammation in untreated and gel base-treated groups was also evident in microscopic evaluation in which vasculitis and distribution of inflammatory cell in all layers were clearly observed.

In contrast, no vasculitis and fewer leukocytic infiltration were observed in ECa 233 gel-treated groups. These finding are supported by preliminary study has shown anti-inflammatory effect of ECa 233 in formalin test [92] and previous study that the anti-inflammatory activity of *Centella asiatica* on nitric oxide (NO) and tumor necrosis- α (TNF- α) production in mouse macrophages. The result showed an ethanol extract of CA inhibited NO production through the suppression of TNF- α production. *Centella asiatica* might reduce inflammatory process by its anti-inflammatory activity [78].

Burn caused oxidative damage demonstrated by an increase in the level of malondialdehyde (MDA) in skin tissue after burn injury [7, 8]. In the group of 0.05% ECa 233 gel-treated, lipid peroxidation detected as the level of MDA was significantly decreased indicating the ability of the test compound to counteract the oxidative injury generated by burning. The result obtained agreed well with previous study by Liu and coworkers (2008) demonstrated that oral administration of madecassoside in the dose of 12 and 24 mg/kg significantly decreased MDA content in the burn skin tissue. In addition, the number of hair follicles representing keratinization was also increased in 0.05% ECa 233 gel-treated group [38].

On day 7 post burning, the cutaneous blood flow in untreated and gel base-treated groups were rather similar whereas significant increase of cutaneous blood flow was exclusively maintained in all ECa 233 gel-treated groups. Rate of wound healing in all ECa 233-treated groups were significantly increased in comparison to untreated and gel base-treated groups. Most of wounds treated with all ECa 233 gel showed apparent wound contraction, becoming smaller in diameter when compared to the untreated and gel base-treated groups. These results indicated that ECa 233 gel-treated groups were in the late proliferative phase whereas untreated and gel base-treated groups remained in the late inflammatory phase as indicated by the presence of leukocytic infiltration in all layers of the skin, though to a lesser extent than those observed in day 3. In correlation with response of cutaneous blood flow, rate of wound healing was significantly higher in all ECa 233-treated groups. Increase in cutaneous blood flow by ECa 233 should provide adequate perfusion and subsequently oxygen and nutrient essential for wound healing process resulting in a higher rate of wound healing observed [53]. Kloppenberg et al. (2001) have shown that all burns that healed within 1 or 2 weeks showed an initial increased perfusion. High perfusion was ascribed to inflammatory reactions like vasodilatation, increased blood flow and increased metabolism [93]. Histopathological observation in 0.05% ECa 233 gel-treated group showed a prominent angiogenesis. These findings are supported by preliminary study of ECa 233 on angiogenesis activity revealed that 0.25% and 0.5% ECa 233 promoted angiogenesis in the chick chorioallantoic membrane (CAM) model [94]. The result obtained agree well with previous study by Kimura et al. (2008) demonstrated that topical application of

asiaticoside facilitate burn wound due to promotion of angiogenesis during skin wound repair as a result of stimulation of vascular endothelial growth factor (VEGF) production [23] and Liu et al. (2008) demonstrated that oral administration of madecassoside promoted skin angiogenesis in mouse burn skins, correlating with findings in vitro that it stimulated endothelial cell growth in rat aortic ring assay [24].

In addition, contents of malondialdehyde (MDA), an end product of lipid peroxidation and a good indicator of oxidative injury, was also increased after burn. These results revealed that ECa 233 gel-treated groups inhibited burn-induced MDA production in the wound sites. Interestingly, the number of hair follicles was also increased in 0.05% ECa 233 gel-treated group.

On day 14 post burning, which was the end of the experiment, untreated and gel base-treated groups showed delay epithelialization and the wounds size were slightly decreased compared with those at the beginning. In histopathological observation, massive of granulation tissue was observed in dermis layer of untreated and gel base-treated groups, indicating early phase of proliferation [52]. The wound in all ECa 233 gel-treated groups showed remarkable decrease in wound size. In addition, hair formation was also noted in 0.05% ECa 233 gel-treated group. The rate of wound healing in 0.05% ECa 233 gel-treated group was significantly higher than those of untreated and gel base-treated groups. In histopathological observation, the wound in all ECa 233 gel-treated groups showed fully developed epithelialization and keratinization. Skin appendages can be observed near to normal skin. In comparison to untreated group the level of MDA in 0.05% ECa 233 gel-treated group was significantly decreased. Cutaneous blood flow was then normalized in all experimental groups.

Interestingly, rather similar profile of responses to ECa 233 was observed in streptozotocin (STZ)-induced diabetic rats, however with a delay of onset. No significant effects on rate of wound healing were observed on day 3 post burning. In the 0.05% ECa 233 gel-treated group, rate of wound healing was significantly higher than those of untreated and gel base-treated groups at day 7 post burning and continued throughout the end of experiment (day 14 post burning), whereas the effect of 0.1% ECa 233 gel-treated group was noted in day 7 post burning. Topical application of 0.05% ECa 233 gel-treated group was found to significantly increase cutaneous blood flow on day 3, 7

and 14 post burning. However, progression of wound healing processes as reflected by signs of inflammation, characteristics of tissue observed, formation of collagen, completeness of epithelialization indicated a delay of responses in diabetic rats. At day 3, 7 and 14, higher degree and longer duration of inflammation than their respective counterpart normal rats, was observed in diabetic rats. For example at day 14, inflammatory cell which was not observed in any of normal rats, was consistently found in all group of diabetic rats. Moreover at day 14 where complete closure in conjunctions with complete re-epithelialization was demonstrated in normal rat receiving 0.05% ECa 233 gel, incomplete closure together with incomplete re-epithelialization was elicited by the same concentration of ECa 233 in diabetic rats. Therefore the wound healing effects of ECa 233 was confirmed in diabetic rats. A delay in responses observed is likely to be due to malfunction of wound healing process previously described in diabetes. Ferguson et al. (1996) observed an increase in inflammatory cell, absence of cellular growth and lack of migration of the epidermis over the wound together with narrowing of blood vessel at the edge of the wound as well as impaired leukocyte function resulting in delayed wound healing in diabetic patients [95].

Furthermore, various studies have shown that diabetes mellitus is associated with increased formation of free radicals [96, 97]. and hyperglycemia-induced oxidative stress ultimately leads to tissue damage [98, 99]. An antioxidant property of ECa 233 was not evident at day 3 and 7 post burning in diabetic rats. Protection of newly formed tissues from hyperglycemia and burn injury-induced oxidative stress of ECa 233 gel-treated group could be attribute to the finding on day 14.

In addition, the number of hair follicles was also increased in 0.05% ECa 233 gel-treated group on day 3 and 7 post burning in diabetic rats indicating more complete re-epithelialization as well as keratinization [38].

In conclusion topical application of standardized extract of *Centella asiatica* ECa 233 clearly facilitated burn wound healing in normal and diabetic rats. In addition to shortening of inflammatory process by its anti-inflammatory, ECa 233 was shown to possess an antioxidant property by decreasing the lipid peroxidation, increased cutaneous blood flow and increased the number of hair follicles and some other mechanism should be further investigated.

REFERENCES

- [1] Cakir, B., and Yegen, B.C. Systemic responses to burn injury. Turkish Journal of Medical Science 34 (2004): 215-26.
- [2] Cetinkale, O., Belce, A., Konukoglu, D., Senyuva, C., Gumustas, M.K., and Tas, T. Evaluation of lipid peroxidation and total antioxidant status in plasma of rats following thermal injury. Burns 23(2) (1997): 114-6.
- [3] Shukla, A., Rasik, A., and Patnaik, G. Depletion of reduced glutathione, ascorbic acid, vitamin E and antioxidant defence enzymes in a healing cutaneous wound. Free radical research 26(2) (1997): 93-101.
- [4] McDaniel, D.H., Ash, K., Lord, J., Newman, J., and Zukowski, M. Accelerated laser resurfacing wound healing using a triad of topical antioxidants. Dermatologic Surgery 24(6) (1998): 661-4.
- [5] Sener, G., Sehirli, A.O., Satiroglu, H., Keyer-Uysal, M., and Yegen, B.C. Melatonin improves oxidative organ damage in a rat model of thermal injury. Burns 28(5) (2002): 419-25.
- [6] Horton, J.W. Free radicals and lipid peroxidation mediated injury in burn trauma: the role of antioxidant therapy. Toxicology 189(1-2) (2003): 75-88.
- [7] Sehirli, A.O., Sener, G., Satiroglu, H., and Ayanoglu-Dulger, G. Protective effect of *N*-acetylcysteine on renal ischemia/reperfusion injury in the rat. Journal of Nephrology 16 (2003): 75-80.
- [8] Ocal, K., et al. The effect of *N*-acetylcysteine on oxidative stress in intestine and bacterial translocation after thermal injury. Burns 30(8) (2004): 778-84.
- [9] Latha, B., and Babu, M. The involvement of free radicals in burn injury: a review. Burns 27(4) (2001): 309-17.
- [10] Papini, R. Management of burn injuries of various depths. British Medical Journal 329 (2004): 158-60.
- [11] Cioffi, W.G. What's new in burns and metabolism. Journal of the American College of Surgeons 192(2) (2001): 241-54.
- [12] Sim, K.M. Management of severe burns injuries-a metabolic perspective. Current Anaesthesia and Critical Care 13(2) (2002): 76-82.

- [13] Napoli, B., D'Arpa, N., Laia, A., Sferrazza, G., and Masellis, M. Antibiotic salicylate vaseline : a topical treatment of choice in burned diabetic patients. Annals of Burns and Fire Disasters 123(3) (1999): n 3.
- [14] World Health Organization. Definition, diagnosis and classification of diabetes mellitus and its complications part 1 : diagnosis and classification of diabetes mellitus. Report of a WHO Consultation, pp. 2-30. Geneva, 1999.
- [15] Duckworth, W.C. Hyperglycemia and cardiovascular disease. Current Atherosclerosis Reports 3 (2001): 383-91.
- [16] Abdollahi, M.R.A., Shadnia, S., Nikfar, S., and Rezaiee, A. Pesticides and oxidative stress : a review. Medical Science Monitor 10(6) (2004): RA144-RA 7.
- [17] Evans, J.L.G., I.R.A.O., Maddux, B.A., and Grodsky, G. Oxidative stress and stress-activated signaling pathways : A unifying hypothesis of type 2 diabetes. Endocrine reviews 23(5) (2002): 599-622.
- [18] Falanga, V. Wound healing and its impairment in the diabetic foot. Lancet 366 (2005): 1736-43.
- [19] Noronha, C., and Almeida, A. Local burn treatment-topical antimicrobial agents. Annals of Burns and Fire Disasters 13 (2000): n 4.
- [20] Inamdar, P.K., Yeole, R.D., Ghogare, A.B., and de Souza, N.J. Determination of biologically active constituents in *Centella asiatica*. Journal of Chromatography A 742(1-2) (1996): 127-30.
- [21] Jia, G., and Lu, X. Enrichment and purification of madecassoside and asiaticoside from *Centella asiatica* extracts with macroporous resins. Journal of Chromatography A 1193(1-2) (2008): 136-41.
- [22] Shukla, A., Rasik, A.M., Jain, G.K., Shankar, R., Kulshrestha, D.K., and Dhawan, B.N. In vitro and in vivo wound healing activity of asiaticoside isolated from *Centella asiatica*. Journal of Ethnopharmacology 65(1) (1999): 1-11.
- [23] Kimura, Y., Sumiyoshi, M., Samukawa, K-i., Satake, N., and Sakanaka, M. Facilitating action of asiaticoside at low doses on burn wound repair and its mechanism. European Journal of Pharmacology 584(2-3) (2008): 415-23.
- [24] Liu, M., et al. Madecassoside isolated from *Centella asiatica* herbs facilitates burn wound healing in mice. Planta Medica 74 (2008): 809-15.

- [25] Tantisira, M.H. Bioactive standardized extract of *Centella asiatica* (ECa233).
Proceedings of the Eighth NRCT-JSPS Joint Seminar : Innovative Research in Natural Products for Sustainable Development, pp. 25. December 3-4, 2008.
Faculty of Pharmaceutical Sciences, Chulalongkorn University, Bangkok 2008.
- [26] Porth, C. Essentials of pathophysiology : concepts of altered health states. 2nd ed.
Philadelphia: Lippincott Williams & Wilkins, 2007.
- [27] Wolff, K., Goldsmith, L.A., Katz, S.I., Gilchrest, B.A., Paller, A.S., and Leffell, D.J.
Fitzpatrick's dermatology in general medicine. 7th ed. New York: McGraw-Hill,
2008.
- [28] MedlinePlus Medical Encyclopedia Image. Skin [Online]. U.S. National Library of
Medicine and National Institutes of Health, 2009. Available from:
<http://www.nlm.nih.gov/medlineplus/ency/imagepages/19679.htm> [2009, Dec 8]
- [29] Marieb, E. Essentials of Human Anatomy and Physiology. 9th ed. San Francisco:
Pearson Benjamin Cummings, 2009.
- [30] Rogers, G.E. Hair follicle differentiation and regulation. International Journal
Developmental Biology 48 (2004): 163-170.
- [31] Patzelt, A., Knorr, F., Blume-Peytavi, U., Sterry, W., and Lademann, J. Hair follicles,
their disorders and the opportunities. Drug Discovery Today: Disease
Mechanisms 5 (2008): 173-81.
- [32] Cotsarelis, G. Epithelial stem cells: a folliculocentric view. Journal of Investigative
Dermatology. 126 (2006): 1459-68.
- [33] Millar, S.E. Molecular mechanism regulating hair follicle development. Journal of
Investigative Dermatology 118 (2002): 216-25.
- [34] Meidan, V.M., Bonner, M.C., and Michniak, B.B. Transfollicular drug delivery-is it a
reality?. International Journal of Pharmaceutics 306 (2005): 1-14.
- [35] Vogt, A., et al. Biology of the human hair follicle. New knowledge and the clinical
significance. Hautarzt 54 (2003): 692-8.
- [36] Kumamoto, T., et al. Hair follicles serve as local reservoirs of skin mast cell
precursors. Blood 102 (2003): 1654-60.
- [37] Wosicka, H., and Cal, K. Targeting to the hair follicles: current status and potential.
Journal of Dermatological Science. 57 (2010): 83-9.

- [38] Sun, T.T., Cotsarelis, G., and Lavker, R.M. Hair follicular stem cells: the bulge activation hypothesis. Journal of Investigative Dermatology 96 (1991): 77S-8S.
- [39] Li, J., Chen, J., and Kirsner, R. Pathophysiology of acute wound healing. Clinics in Dermatology 25(1) (2007): 9-18.
- [40] Langton, A.K., Herrick, S.E., and Headon, D.J. An extended epidermal response heals cutaneous wounds in the absence of a hair follicle stem cell contribution. Journal of Investigative Dermatology 128 (2008): 1311-18.
- [41] Leaper, D.J., and Gottrup, F. Surgical wounds. In Leaper, D.J., and Harding, K.G. (eds.), Wounds: Biology and management, pp. 23-40. Hong Kong: Oxford University Press, 1998.
- [42] Strodbeck, F. Physiology of wound healing. Newborn and Infant Nursing Reviews 1(1)(2001): 43-52.
- [43] Leaper, D.J., and Harding, K.G. ABC of wound healing traumatic and surgical wounds. British Medical Journal 332 (2006): 532-5.
- [44] Hass, A.F. Wound healing. Dermatology Nursing 7 (1995): 28-34.
- [45] Cooper, D.M. Wound healing : New understandings. Nurse Practitioner Forum 10(1999):74-86.
- [46] Russell, L. Understanding physiology of wound healing and how dressings help. British Journal of Nursing 9 (1999): 10-21.
- [47] Williamson, D., and Harding, K. Wound healing. Basic Science 12 (2004): 4-7.
- [48] Hart, J. Inflammation I : Its role in the healing of acute wounds. Journal of wound Care 11 (2002): 205.
- [49] Sylvia, C.T. The role of neutrophil apoptosis in influencing tissue repair. Journal of Wound Care 12 (2003): 13.
- [50] Diegelmann, R.F., and Evans, M.C. Wound healing : an overview of acute, fibrotic and delayed healing. Frontiers in Bioscience 9 (2004): 283-9.
- [51] Artuc, M., Hermes, B., Steckelings, U.M., Grutzkau, A., and Henz, B.M. Mast cells and their mediators in cutaneous wound healing-active participants or innocent bystanders. Experimental Dermatology 8 (1999): 1.

- [52] Midwood, K.S, Williams, L.V., and Schwarzbauer, J.E. Tissue repair and the dynamics of the extracellular matrix. The International Journal of Biochemistry & Cell Biology 36(6) (2004): 1031-7.
- [53] Kumar, V., Abbas, A.K., and Fausto, N. Robbins Basic Pathology. 8th ed. Philadelphia: PA, 2008.
- [54] Yates, R.A., Nanney, L.B., Gates, R.E., King, L.E., and Jr. Epidermal growth factor and related growth factors. International Journal of Dermatology 30 (1991):687.
- [55] Clark, R.A.F. Wound repair : Overview and general consideration. In Clark, R.A.F. (eds.), The molecular and cellular biology of wound repair, pp. 3-50. New York: Plenum Press, 1995.
- [56] Garrett, B. Cellular communication and the action of growth factors during wound healing. Journal of Wound Care 6 (1997): 277-80.
- [57] Iocono, J., Ehrlich, H., Gottrup, F., and Leaper, D.J. The biology of healing. In Leaper, D.J. and Harding, K.G. (eds.), Wounds: Biology and management, pp.10-22. England: Oxford University Press, 1998.
- [58] Waldrop, J., and Daughy, D. Wound-healing physiology. In Bryant, R.A. (eds.), Acute and chronic wounds. Nursing Management, pp. 17-39. St. Louis, MO, Mosby,1991.
- [59] Lee, R.C., and Astumian, R.D. The physiochemical basic for thermal non-thermal 'burn' injuries. Burns 22 (1996): 509-19.
- [60] Arturson, G. Pathophysiology of the burn wound and pharmacological treatment. The Rudi Hermans Lecture, 1995. Burns 22 (4) (1996): 255-74.
- [61] Hettiaratchy, S., and Dziewulski, P. ABC of burns pathophysiology and types of burns. British Medical Journal 328 (2004): 1427-9.
- [62] Nucleus Medical Medica. Classification of skin burns [Online]. Available from: <http://www.nucleusinc.com> [2009, Nov 16]
- [63] Sheridan, R.L. Evaluation and management of the thermally injured patient. In Freedberg, I.M., Eisen, A.Z., Woff, K., Austen, K.F., Goldsmith, L.a., and Katz, S.I. (eds.), Fitzaptrick's dermatology in general medicine, pp. 1220-9. New York: McGraw-Hill, 2003.

- [64] Burd, A., and Chiu, T. Allogenic skin in the treatment of burns. Clinical in Dermatology 23(2005): 376-87.
- [65] Hosnuter, M.b, Gurel, A., Babuccu, O., Armutcu, F., Kargi, E., and Isikdemir, A. The effect of CAPE on lipid peroxidation and nitric oxide levels in the plasma of rats following thermal injury. Burns 30(2) (2004): 121-5.
- [66] Guemouri, L., Artur, Y., Herbeth, B., Jeandel, C., Cuny, G., and Siest, G. Biological variability of superoxide dismutase, glutathione peroxidase, and catalase in blood. Clinical Chemistry 37 (1991): 1932-7.
- [67] Naziroglu, M., and Butterworth, P. Protective effects of moderate exercise with dietary vitamin C and E on blood antioxidative defense mechanism with streptozotocin-induced diabetes. Canadian Journal of Applied Physiology 30(2) (2005): 172-85.
- [68] Chithra, P., Sajithlal, G.B., and Chandrakasan, G. Influence of aloe vera on the healing of dermal wounds in diabetic rats. Journal of Ethnopharmacology 59(3) (1998): 195-201.
- [69] Albertson, S. PDGF and FGF reverse the healing impairment in protein-malnourished diabetic mice. Surgery 114 (1993): 368-72.
- [70] Brinkhaus, B., Lindner, M., Schuppan, D., and Hahn, E.G. Chemical, pharmacological and clinical profile of the East Asian medical plant *Centella asiatica*. Phytomedicine 7(5) (2000): 427-48.
- [71] Medplant. *Centella asiatica* [Online]. Available from: <http://www.medplant.mahidol.ac.th/pubhealth/centella.html> [2009, Oct 3]
- [72] Jadzuka. Asiatic acid and asiaticoside [Online]. Available from: <http://www.jadzuka.wordpress.com> [2009, Oct 5]
- [73] Chemblink. Madecassic acid [Online]. Available from: <http://www.chemblink.com/products/18449-41-7.htm> [2009, Oct 5]
- [74] Sunikumar, Parameshwaraiah, S., and Shivakumar, H.G. Evaluation of topical formulations of aqueous extract of *Centella asiatica* on open wound in rats. India Journal Experimental Biology 36(6) (1998): 569-72.

- [75] Coldren, C., Hashim, P., Ali, J., Oh, S., Sinskey, A., and Rha, C. Gene expression change in the human fibroblast induced by *Centella asiatica* triterpenoids. Planta Medica 69(8) (2003): 725-32.
- [76] Jayashree, G., Muraleedhara, G.K., Sudarshal, S., and Jacob, V.B. Anti-oxidant activity of *Centella asiatica* on lymphoma-bearing mice. Fitoterapia 74 (2003): 431-4.
- [77] Cheng, C.L., Guo, J.S., Luk, J., and Koo, M.W.L. The healing effects of *Centella* extract and asiaticoside on acetic acid induced gastric ulcers in rats. Life Sciences 74 (2004): 2237-49.
- [78] Punturee, K., Wild, C.P., and Vinitketkumneun, U. Thai medicinal plants modulate nitric oxide and tumor necrosis factor-in J774.2 mouse macrophages. Journal of Ethnopharmacology 95 (2004): 183-9.
- [79] Babu, T.D., Kuttan, G., and Padikkala, J. Cytotoxic and anti-tumour properties of certain taxa of Umbelliferae with special reference to *Centella asiatica* (L.) Urban. Journal of Ethnopharmacology 48(1) (1995): 53-7.
- [80] Veerendra Kumar, M.H., and Gupta, Y.K. Effect of different extracts of *Centella asiatica* on cognition and markers of oxidative stress in rats. Journal of Ethnopharmacology 79(2) (2002): 253-60.
- [81] Gupta, Y.K., Veerendra Kumar, M.H., and Srivastava, A.K. Effect of *Centella asiatica* on pentylenetetrazole-induced kindling, cognition and oxidative stress in rats. Pharmacology Biochemistry and Behavior 74(3) (2003): 579-85.
- [82] Ago, Dall,P., Fernandes, T.G., Machado, U.F., Bello, A.A., and Irigoyen M.C. Baroreflex and chemoreflex dysfunction in streptozotocin-diabetic rats. Brazilian Journal of Medical and Biological Research. 30 (1997): 119-24.
- [83] Somboonwong, J., Thanamitramanee, S., Jariyapongskul, A., and Patumraj, S. Therapeutic effects of Aloe vera on cutaneous microcirculation and wound healing in second degree burn model in rats. Journal of Medical Association of Thailand 83 (2000): 417-25.
- [84] Zawacki, B.E. Reversal of capillary stasis and prevention of necrosis in burns. Annals of Surgery 180(1) (1974): 98-102.

- [85] Lindblom, L., Cassuto, J., Yregard, L., Tarnow, P., Rantfors, J., and Henden, P.L. Importance of vasoactive intestinal polypeptide in the regulation of burn perfusion. Burns 26 (2000): 435-42.
- [86] Eun, H. Evaluation of skin blood flow by Laser Doppler Flowmetry. Clinical Dermatology 13(1995): 337-47.
- [87] Fagrell, B. Advances in microcirculation network evaluation : an update. 15(1) (1995): 34-40.
- [88] Wei, H., Zhang, X., Wang, Y., and Lebwohl, M. Inhibition of ultraviolet light-induced oxidative events in the skin and internal organs of hairless mice by isoflavone genistein. Cancer Letters 185(1) (2002): 21-9.
- [89] Lalonde, C., Knox, J., Youn, YK., and Demling, R. Relationship between hepatic blood flow and tissue lipid peroxidation in the early postburn period. Critical Care Medicine 20 (1992): 789-96.
- [90] Mallikarjuna, Rao, C., Ghosh, A., Raghothama, C., and Bairy, K.L. Does metronidazole reduce lipid peroxidation in burn injuries to promote healing. Burns 28(5) (2002): 427-9.
- [91] Parihar, A., Parihar, M.S., Milner, S., and Bhat, S. Oxidative stress and anti-oxidative mobilization in burn injury. Burns 34(1) (2008): 6-17.
- [92] Thiensukont, N., Tianwattanatada, S., Bamrungsuk, K., and Chompoopong, C. Evaluation of antinociceptive activities of pyridoxine and *Centella asiatica* in rats. Proceedings of the International Anatomical Science and Cell Biology Conference (IASCBC). May 26-29, 2010 in Singapore. Department of Anatomy, Faculty of Medicine, Siriraj Hospital, Mahidol University, Bangkok, 2010.
- [93] Kloppenberg, F.W.H, Beerthuisen, G.I.J.M., and Duis, ten, H.J. Perfusion of burn wounds assessed by laser doppler imaging is related to burn depth and healing time. Burns 27 (2000): 359-63.
- [94] Pukum, S., and Tongyud, W. Effect of standardized *Centella asiatica* extract ECa 233 on angiogenesis activity. Senior project, Department of Pharmacology and Physiology, Faculty of Pharmaceutical Sciences, Chulalongkorn University.2009.
- [95] Furgerson, M.W., Herrick, S.E., Spencer, M.J., Shaw, S.E., Boulton, A.J., and Sloan, P. The histology of diabetic foot ulcers. Diabetes Medical 13 (1996): s30-3.

- [96] Yim, M.B., Yim, H.S., Lee, C., Kang S.O., and Chock, P.B. Protein glycation creation of catalytic sites for free radical generation. Annals of the New York Academy of Sciences 928 (2001): 48-53.
- [97] Baynes, J.W., and Thorpe, S.R. Role of oxidative stress in diabetic complications: a new perspective on an old paradigm. Diabetes 48 (1999): 1-9.
- [98] Nishikawa, T., Edelstein, D., and Brownke, M. The missing link : a single unifying mechanism for diabetic complications. Kidney International 58 (2000): 26-30.
- [99] Brownlee, M. Biochemistry and molecular cell biology of diabetic complications. Nature 403 (2000): 813-20.

APPENDICES

APPENDIX A
Certificate of Project Approval

ศร 0512.14 คสว 019/ 2552



Chulalongkorn University Animal Care and Use Committee

Certificate of Project Approval	<input type="checkbox"/> Original <input type="checkbox"/> Renew
Animal Use Protocol No. 09-33-005	Approval No. 09-33-005
Protocol Title	
Effect of Eca 233, standardized extract of <i>Centella asiatica</i> on second degree burn wound healing in normal and diabetic rats	
Principal Investigator	
Mayuree Tantisira, Ph.D.	
Certification of Institutional Animal Care and Use Committee (IACUC)	
This project has been reviewed and approved by the IACUC in accordance with university regulations and policies governing the care and use of laboratory animals. The review has followed guidelines documented in Ethical Principles and Guidelines for the Use of Animals for Scientific Purposes edited by the National Research Council of Thailand.	
Date of Approval	Date of Expiration
January 30, 2009	January 30, 2010
Applicant Faculty/Institution	
Faculty of Pharmaceutical Sciences, Chulalongkorn University, Phyathai Rd., Pathumwan BKK-THAILAND. 10330	
Signature of Chairperson	Signature of Authorized Official
Name and Title	Name and Title
WITHAYA JANTHASOAT Chairman	RUNGPETCH SAKULBUMRUNGSIL, Ph.D. Associate Dean (Research and Academic Service)
<p><i>The official signing above certifies that the information provided on this form is correct. The institution assumes that investigators will take responsibility, and follow university regulations and policies for the care and use of animals.</i></p> <p><i>This approval is subjected to assurance given in the animal use protocol and may be required for future investigations and reviews.</i></p>	

APPENDIX B

Poster presentation in 31st Pharmacological and Therapeutic Society of
Thailand Meeting 18-20 March 2009 at Faculty of Medicine,
Khon Kaen University.

Original article

P24

Wound Healing Effects of a Standardized Extract of *Centella asiatica* ECa 233 on Burn Wound in RatsKoranit Wannarat^{1*}, Mayuree H. Tantisira², Boonyong Tantisira².

¹Inter-department Program of Pharmacology, Graduate School, ²Department of Pharmacology and Physiology, Faculty of Pharmaceutical Sciences, Chulalongkorn University, Bangkok 10330, Thailand.

E-mail: w_koranit@yahoo.com

Abstract

The present study aimed to investigate the effects of a standardized extract of *Centella asiatica* ECa 233 on second degree burn wound in Male Wistar rats. Gel containing 0.05% of ECa 233 as well as a gel base was topically applied, once daily, to a wound generated on the back side of the animals by a 90°C hot plate. Evaluation of wound healing including a visual observation, an estimation of rate of wound healing and measurement of cutaneous blood flow was made at day 3 and 7 post-burning. In general wound treated with ECa 233 was seemed to heal better than those of untreated or gel base-treated groups. Rate of wound healing in rats treated with 0.05% ECa 233 gel was significantly higher than those of untreated and gel base treated groups in day 7 post-burning. In agreement with the healing rate, cutaneous blood flow on day 3, both gel base and 0.05% ECa 233 groups were increased, whereas on day 7 only in 0.05% ECa 233 gel group was increased. Thus, it is likely that increases of oxygen and nutrient brought about by an increment of cutaneous blood flow may, at least, in part, be responsible for the wound healing effects of ECa 233. However, other mechanisms that are relevant to wound healing effects of ECa 233 remain unexplored. Therefore, it is suggested that studies on effects of ECa 233 on burn wound should be further carried out.

Keywords: *Centella asiatica*, second degree burn, wound healing

Introduction

Thermal burn is more commonly induced in tissues by the sudden exposure to excessive thermal energy. The local and systemic inflammatory responses to thermal burn are extremely complex, resulting in both local burn tissue damage and deleterious systemic effects on all other organ systems distant from the burn area itself. These include fluid and protein losses, local and systemic sepsis, gross metabolic, hematological and immune disturbances (1). These result in morbidity and mortality associated with burn injury (2,3). Burn wound care is needed according to the severity of burn. The concepts of optimum minor burn wound treatment focus on avoiding wound infection and treat with topical antibiotic agents or ointment, occlusive and wet dressing (3). Topical antibiotics are used routinely in the forms of antimicrobial creams e.g. silver sulfadiazine applied locally to skin injury.

Despite the existence of many advanced medical treatments, we still have to encounter the side effects and high expense. In Thailand, there are many kinds of herbs including *Centella asiatica* (Linn.) that have been advocated for their wound healing effect.

Madecassoside, one of the major constituent of *C. asiatica* has significant wound healing activity in parallel with a decrease of nitric oxide (NO) levels and malondialdehyde (MDA) content in the burn skin tissue when administered orally at higher doses (12 and 24

mg/kg) (4). Therefore, we decided to investigate the wound healing effects of ECa 233, which is a white to off-white of standardized extracted powder of *C.asiatica* containing triterpenoids not less than 80% and the ratio between madecassoside and asiaticoside was kept at 1.5 ± 0.5 , on burn wound in rats.

Materials and methods

1. Animals

Male wistar rats weighing 250-300 g were obtained from the National Laboratory Animal Center, Mahidol University, Salaya, Nakornpathom. The rats were caged in the air-conditioned room maintained temperature at $25\pm 1^\circ\text{C}$. They were provided with food and water *ad libitum* and acclimatized for 1 week before experimentation. Rats were divided into four groups as follows: no burn, burn with no treatment (untreated), burn treated with gel base, burn treated with 0.05 % ECa 233 gel.

2. Induction of second degree of burn injury

The animals were anesthetized with pentobarbital sodium 60 mg/kg intraperitoneally. Second-degree burn wound was made by placing the 90°C hot plate on the selected area of the back of the animal for 10 sec (5). The wounds were topically treated with 100 mg of gel base or gel base containing 0.05% ECa 233 once daily.

3. Evaluation of burn wound

Rate of wound healing

On day 3 and 7 post burning, photographs of the wounds were taken by digital camera. The areas of wound were measured by Image Tool v.3.0 and rate of wound healing was calculated using the following formula (4).

$$\text{wound healing rate (\%)} = \frac{[\text{wound area on day 0} - \text{wound area on day N}]}{\text{wound area on day 0}} \times 100\%$$

Cutaneous blood flow

Measurement of cutaneous blood flow was carried out by a Laser Doppler Flowmeter (Perimed AB SE-175, Periflux System 5000)(6). The needle probe was fixed perpendicularly on skin. Five different measurements (at the center and four corners) were performed and the mean was used for calculation as percent change compared to normal rats.

4. Statistical analysis

Results are presented as mean \pm S.E.M. The differences among experimental groups were compared by one-way ANOVA followed by Duncan post hoc test and were considered statistically when P was less than 0.05.

Results

General appearance of the wound

On day 3 post-burning, wound in untreated and gel base-treated groups became swelling and exudated. In comparison, the wound in 0.05% ECa 233 gel group showed a mild degree of swelling and wound surface was rather dry and smooth. On day 7 post-burning, most of wounds treated with 0.05% ECa 233 gel showed apparent wound contraction, becoming smaller in diameter when compared to the untreated and gel base-treated groups. In addition, hair formation was also noted in ECa 233 treated group.

Effect of ECa 233 on rate of wound healing

No significant effects on rate of wound healing were observed on day 3. The rate of wound healing was found to be 14.12 ± 2.48 , 16.12 ± 2.64 and 21.23 ± 1.89 % in the untreated,

gel base-treated and 0.05% ECa 233-treated groups, respectively. On day 7 post-burning, rate of wound healing in 0.05% ECa 233-treated group ($42.52 \pm 1.88\%$) was significantly higher than untreated and gel base groups (Figure 1).

Effect of ECa 233 on cutaneous blood flow

In comparison to unwounded skin, blood flow was found to be increased in all groups of animals with wound. On day 3 post-burning, cutaneous blood flow of gel base and 0.05% ECa 233 treated groups ($144.44 \pm 10.75\%$ and $166.35 \pm 12.90\%$, respectively) were significantly higher than untreated group ($109.59 \pm 8.21\%$). However, on day 7, cutaneous blood flow of only the 0.05% ECa 233-treated group (148.14 ± 8.77) but not the gel base-treated group ($134.66 \pm 9.65\%$) was significantly different from untreated group (Figure 2).

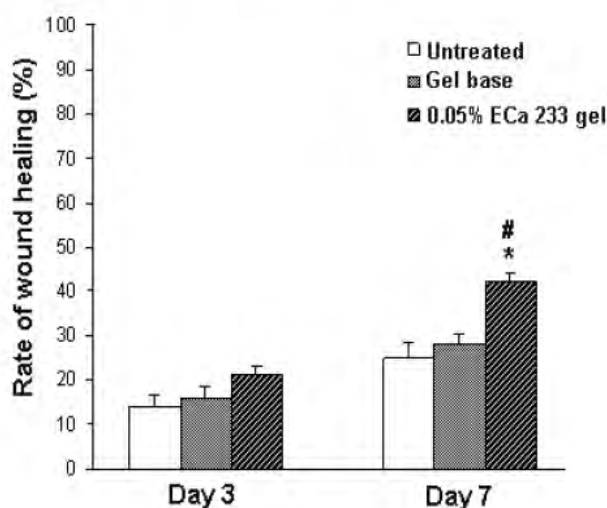


Figure 1 Rate of wound healing in different treatment groups on day 3 and 7 post burning. Values are mean \pm S.E.M. (n=6). * Significantly different from untreated group ($p < 0.05$). # Significantly different from gel base group ($p < 0.05$)

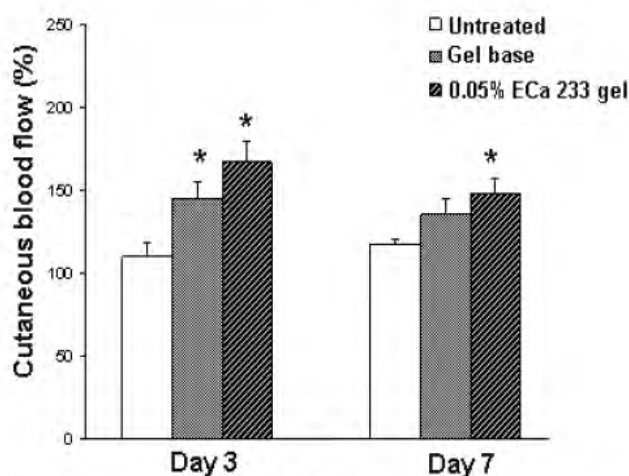


Figure 2 Relative cutaneous blood flow (percent changed from unwound skin) in treatment groups on day 3 and 7 post burning. Values are means \pm S.E.M. (n=6). * Significantly different from untreated group ($p < 0.05$)

Discussion and Conclusion

In burn wound, microcirculation is generally compromised to the worst extent at around 12-24 h post-burning resulting in a restriction or cessation of blood flow which in turn causes ischemia and subsequently a reperfusion and thus a generation of oxidative stress. Intervention that could restore blood flow or scavenging the free radicals should, in principle reduce the damage due to oxidative stress (7,8). The present study demonstrated the wound healing effect of topically applied standardized extract of *Centella asiatica* (ECa 233) on the burn wound model in rats. On day 3 post-burning, despite an increase in cutaneous blood flow in all groups, the 0.05% ECa 233 gel group was seemed to heal better than the other groups as contraction of wound edge was noted. The wound surface was rather dry and showed very mild degree of swelling, whereas exudates were apparent in untreated and gel base treated group.

On day 7, the cutaneous blood flow in untreated and gel base treated was rather similar and significant increase of blood flow was exclusively maintained in 0.05% ECa 233-treated group. In line with the observation on cutaneous blood flow, rate of wound healing in 0.05% ECa 233 treated-groups was significantly increased in comparison to gel base treated and untreated groups. Increase in cutaneous blood flow by ECa 233 should provide adequate perfusion and subsequently oxygen and nutrient essential for wound healing process resulting in a higher rate of wound healing observed. However, some other effects/mechanisms such as free radical scavenging activity of ECa 233 that might be relevant to different phases of wound healing should be further conducted.

In conclusion topical application of standardized extract of *Centella asiatica* (ECa 233) clearly facilitated burn wound healing in rats. Though increase of blood flow is a plausible mechanism underlying the wound healing observed, some other mechanism should be further investigated.

References

1. Cakir B, Berrak C. Systemic response to burn injury. Turk J Med Sci 2004;34:215-26.
2. Latha B, Babu M. The involvement of free radicals in burn injury : a review. Burns 2001; 2:309-17.
3. Papini R. Management of burn injuries of various depths. BMJ 2004;329:158-60.
4. Liu M, Dai Y, Li Y, Luo Y, Huang F, Gong Z, Meng Q. Madecassoside isolated from *Centella asiatica* herbs facilitates burn wound healing in mice. Planta Medica 2008;74: 809-15.
5. Somboonwong J, Duansak N. The therapeutic efficacy and properties of topical *aloe vera* in thermal burns. J Med Assoc Thai 2000;83:417-25.
6. Lindbloma L, Cassusto J, Yregarda L, Tarnowb P, Rantforsa J, Hendena PL. Importance of vasoactive intestinal polypeptide in the regulation of burn perfusion. Burns 2000;26: 435-47.
7. Arturson G. Pathophysiology of the burn wound and pharmacological treatment. The Rudi Hermans Lecture. Burns 1996;22:255-74.
8. Parihar A, Parihar MS, Milner S, Bhat S. Oxidative stress and anti-oxidative mobilization in burn injury. Burns 2008;34:6-17.



Best Presentation Award

Miss Koranit Wannarat

Faculty of Pharmaceutical Sciences, Chulalongkorn University

***has been recognized with the Best Presentation Award at
the 31st Pharmacological and Therapeutic Society of Thailand
Meeting at Khon Kaen University, Khon Kaen***

Given this date, March 19, 2009

Jintana Sattayasai
Jintana Sattayasai, Ph.D.
President of the Pharmacological &
Therapeutic Society of Thailand

Veerapol Kukongviriyapan
Veerapol Kukongviriyapan, Ph.D.
Chairman, the Organizing Committee of 31st Meeting



BIOGRAPHY

Miss Koranit Wannarat was born on July 28, 1983 in Lampang, Thailand. She received Bachelor degree of Nursing Science in 2005 from Faculty of Nursing, Mahidol University. She worked as a nurse at Siriraj hospital since 2005-2007.

Poster presentation entitled "Wound healing Effects of a Standardized Extract of *Centella asiatica* ECa 233 on Burn wound in Rats" of Miss Koranit Wannarat was presented in Thai Journal of Pharmacology vol.31, No1, 2009, Proceedings of 31st Pharmacological and Therapeutic Society of Thailand Meeting 18-20 March 2009 at Faculty of Medicine, Khon Kaen University.