



จุฬาลงกรณ์มหาวิทยาลัย
ทุนวิจัย
กองทุนรัชดาภิเษกสมโภช

รายงานวิจัย

การศึกษาการแสดงออกของยีนฟีแลกกรินอินไวลูคริน
และสปิงค์ห้า ซึ่งมีผลต่อการสร้างผิวหนังชั้นนอกในโรค
ผิวหนังอะโทปีในสุนัข

โดย

กรรณาภรณ์ สุริยผล

มีนาคม 2555



จุฬาลงกรณ์มหาวิทยาลัย

ทุนวิจัย

กองทุนรัชดาภิเษกสมโภช

รายงานวิจัย

การศึกษาการแสดงออกของยีนฟีแลกกรินอินไวลูคริน
และสปิงค์ห้า ซึ่งมีผลต่อการสร้างผิวหนังชั้นนอกในโรค
ผิวหนังอะโทปีในสุนัข

โดย

กรรณาภรณ์ สุริยผล

มีนาคม 2555

Acknowledgement

We would like to express our grateful thanks to Drs.Tossaporn Nakbed and Jakkaphan Wannawong for sample collections. Special thanks to Assoc. Prof. Tumtip Sangruchi, Department of Pathology, Faculty of Medicine, Siriraj Hospital, Mahidol Univeristy for the rotary microtome and to Assist. Prof. Sayamon Srisuwatanasagul, Department of Veterinary Anatomy, Faculty of Veterinary Science, Chulalongkorn University for her kind help in image analysis.

โครงการวิจัย การศึกษาการแสดงออกของยีนฟีแลกกริน, อินโวลูครินและสปิงค์ห้าซึ่งมีผลต่อการ
สร้างผิวหนังชั้นนอกในโรคผิวหนังชนิดอะโทปีในสุนัข

ผู้วิจัย อาจารย์สัตวแพทย์หญิง ดร.กรรณาภรณ์ สุริยผล

ปีที่ทำวิจัยเสร็จ มิถุนายน 2554

บทคัดย่อ

การศึกษาวิจัยครั้งนี้มีวัตถุประสงค์เพื่อศึกษากลไกที่ทำให้เกิดพยาธิสภาพของเซลล์คีราติโนไซต์ในสุนัขที่เป็นโรคผิวหนังภูมิแพ้ผิวหนัง จากการเก็บตัวอย่างผิวหนังบริเวณที่มีรอยโรคในสุนัขพันธุ์เล็กที่เป็นโรคดังกล่าวพบลักษณะออร์โรทีราโตคิกไฮเปอร์ทีราโตซิส (การหนาตัวของผิวหนังชั้นสตราตัมคอร์เนียมโดยพบเซลล์ที่ไม่มีนิวเคลียสอยู่ภายใน) จากการทำอิมมูโนฮิสโตเคมีโดยใช้แอนติบอดีของเคไอ 67 สะท้อนให้เห็นอัตราการเพิ่มจำนวนเซลล์คีราติโนไซต์ในสุนัขป่วยสูงกว่ากลุ่มควบคุม และการเพิ่มจำนวนดังกล่าวมีความสัมพันธ์เชิงบวกกับดัชนีแสดงความรุนแรงของโรค (CADESI-03) จากการศึกษาการแสดงออกของโปรตีนที่มีผลต่อการเจริญของเซลล์คีราติโนไซต์ อาทิ เค-ราติน 5 เคราติน 10 อินโวลูคริน ฟีแลกกรินและ เลคตินซึ่งถอดรหัสจากยีนสปิงค์ 5 ในผิวหนังสัตว์ป่วยทั้งส่วนที่เป็นรอยโรค ส่วนที่ไม่เป็นรอยโรค และผิวหนังสัตว์ปกติโดยวิธีอิมมูโนฮิสโตเคมีพบว่าการเพิ่มจำนวนของเคราติน 5 ไปสู่ชั้นสตราตัมสไปโนซัมและการแสดงออกของเคราติน 10 อินโวลูครินและฟีแลกกรินในผิวหนังสัตว์ป่วยทั้งส่วนที่เป็นรอยโรคและส่วนที่ไม่เป็นรอยโรคลดลงเมื่อเทียบกับกลุ่มควบคุม ในทางตรงกันข้ามเลคตินในผิวหนังสัตว์ป่วยส่วนที่เป็นรอยโรคมีการแสดงออกที่เพิ่มขึ้นเมื่อเทียบกับกลุ่มควบคุม สำหรับความสัมพันธ์กับดัชนีแสดงความรุนแรงของโรค พบความสัมพันธ์เชิงบวกระหว่าง CADESI-03 และเลคติน และพบความสัมพันธ์เชิงลบระหว่าง CADESI-03 และอินโวลูครินซึ่งสอดคล้องกับผลคะแนนการคิดสี่จากการทำอิมมูโนฮิสโตเคมี การแสดงออกของยีนเคราติน 5 อินโวลูครินและฟีแลกกรินในผิวหนังสัตว์ป่วยส่วนที่เป็นรอยโรคมีค่าเพิ่มขึ้นเมื่อเทียบกับตัวอย่างกลุ่มควบคุมซึ่งตรงกันข้ามกับการแสดงออกของโปรตีน รายงานครั้งนี้แสดงให้เห็นว่าการแสดงออกของโปรตีนและเอ็มอาร์เอ็นเออาจไม่สัมพันธ์กันเสมอไป และยังสามารถแสดงเป็นครั้งแรกถึงความสัมพันธ์ของเคราตินและโรคผิวหนังภูมิแพ้ผิวหนังในสุนัข และการแสดงออกของอินโวลูครินซึ่งลดลงในโรคดังกล่าว โดยสรุปการศึกษาครั้งนี้แสดงให้เห็นว่าการหนาตัวของเซลล์ผิวหนังชั้นนอกใน

สุนัขที่เป็น โรคผิวหนังแพ้ผิวหนังเป็นผลเนื่องจากการรบกวน โปรแกรมการเจริญและการเพิ่มจำนวน
อย่างผิดปกติของเซลล์ผิวหนัง

Project Title Study the filaggrin, involucrin and SPINK5 gene expression in canine atopic dermatitis
Name Dr. Gunnaporn Suriyaphol
Year May 2010

Abstract

The pathogenic alterations in skin keratinocyte proliferation and differentiation in canine atopic dermatitis (CAD) were investigated. Biopsy of lesional skin of small breed dogs with AD showed orthokeratotic hyperkeratosis. Ki-67 immunohistochemistry (IHC) reflected the higher proliferation rate in the atopic dogs ($P < 0.001$) which positively correlated to Canine Atopic Dermatitis Extent and Severity Index, CADESI-03 ($P < 0.001$). The coordinated expression of proteins, involved in keratinocyte differentiation, keratin 5 (K5), K10, involucrin (IVL), filaggrin (FLG) and lympho-epithelial Kazal-type inhibitor (LEKTI), encoded by *SPINK5* gene, were investigated in lesional, non-lesional, and normal skins. IHC labeling indicated an expansion of K5 to S. spinosum with reduced expressions of K10, IVL and FLG in lesional and non-lesional skins ($P < 0.05$). In contrast, LEKTI expression was increased in lesional skin compared to the normal controls. The positive and negative correlations between CADESI-03 and LEKTI and between CADESI-03 and IVL staining scores of lesional skins, respectively, corresponded to the IHC results. However, gene expression of *K5*, *IVL* and *FLG* was upregulated ($P < 0.05$) in lesional skin compared to the control samples. The findings implied variable success of correlation between protein and mRNA expressions. However, this paper reported, for the first time, the association of keratins to CAD and the decreased protein expression of IVL in CAD. In conclusion, the present study

demonstrated that epidermal hyperplasia in CAD was a result of both disturbed programs of epidermal differentiation and proliferation.

Table of Contents

Acknowledgement.....	ii
บทกัศดข้ยอ.....	iii
Abstract.....	v
List of Tables.....	viii
List of Figures.....	ix
1. Introduction.....	1
2. Survey of Related Literature.....	2
3. Procedures.....	5
4. Results.....	13
5. Discussion.....	23
6. Conclusion.....	30
7. Suggestion for Further Work.....	30
8. References.....	32

List of Tables

1. Breeds and health status of dogs included in the study.....	7
2. Primers used for reverse transcriptase quantitative PCR.....	12
3. Thickness of epidermis and ratio of S. corneum and nucleated epidermis of non-lesional and lesional skin of dogs with AD.....	15
4. IHC staining scores of K5, K10, IVL, FLG expression by semi-quantitative manual scoring for normal, non-lesional and lesional skin of CAD.....	18
5. Fold change in gene-specific mRNA expression in CAD lesional, CAD non-lesional and control dog skin.....	24

List of Figures

1. Histopathology of normal clinical, CAD lesional and non-lesional skins 15
2. Immunohistochemical staining for Ki-67, K5, K10, IVL and FLG..... 16
3. Correlation between CADESI-03 and Ki-67 staining nuclei in lesional and non-lesional skin of dogs with AD.21
5. Correlation between CADESI-03 K5 and IVL staining scores in lesional and non-lesional skin of dogs with AD.....21

1. Introduction

Canine atopic dermatitis (CAD) is the second most common allergic skin disease in dogs (Hillier and Griffin 2001). Particular breeds are known to be more likely to develop atopic dermatitis, including the Labrador/Golden retriever, English setter, West highland white terrier and English/Staffordshire bull terrier (Fraser et al 2008). In Thailand, the breeds that are commonly found to develop CAD, including Miniature poodle, Shih tzu, Pug, Bulldog, Great dane, Labrador/Golden retriever (Dr.Meena Sarikaputi - Personal communication). Although the disease is frequently found, the pathogenesis of the disease is still obscured. Recently several publications have revealed the importance of skin barrier, composed of several proteins including filaggrin , involucrin and LEKTI, encoded by *SPINK5* gene, in preventing in transepidermal water loss (TEWL) and the entry of infectious, toxic substances, and allergens (Descargues et al 2005; Proksch et al 2006). The disruption of skin barrier permits allergens to reach antigen presenting cells in subepithelial tissues, triggering hypersensitivity and allergic reaction. The aim of this study was to quantify the expression of K5, K10, IVL, FLG and LEKTI in lesional atopic, non-lesional atopic and healthy canine skin either at the protein and mRNA levels by immunohistochemistry and quantitative real-time polymerase chain reaction, respectively. The keratinocyte proliferation was also studied by Ki-67 expression. The association of the gene and protein expressions in atopic skin with the Canine Atopic Dermatitis and Severity Index (CADESI-03), which is similar to the human SCORAD index were investigated. Determining the expression pattern of these proteins would help, at least in part, unveil the pathogenesis of CAD.

2. Survey of Related Literature

Atopic dermatitis (AD) is a common allergic skin disease recognized in dogs (Hillier and Griffin 2001) and humans (Rothe and Grant-Kels 1996). Canine atopic dermatitis (CAD) is defined as 'genetically predisposed inflammatory and pruritic allergic skin disease with characteristic clinical features associated with IgE antibodies most commonly directed against environmental allergens' (Halliwell 2006). CAD prevalence seemed to be increasingly in the past decade to approximately 15% of the dog population (Hillier and Griffin 2001). Diagnosis of CAD is based primarily on history, clinical signs, the exclusion of other pruritic dermatose (Olivry 2010) and the diagnostic criteria proposed by Favrot et al. (2010). Intradermal skin test and laboratory evaluation, including allergy tests and histopathology of skin biopsy specimens, also support the diagnosis (DeBoer and Hillier 2001; Hillier and DeBoer 2001; Olivry et al 2010). CAD is considered to be a spontaneous model of human atopic dermatitis (HAD) since both have similar clinical features and immunological profiles, including familial occurrence, early age of onset, recurrent pruritus, skin lesions typically located at flexor and extensor sites of extremities, skin xerosis and the presence of Th2-dominated immune response against environmental allergens. Moreover, the similarity in impaired skin barrier function, reflecting in increased transepidermal water loss (TEWL) and in histological lesion with spongiotic dermatitis and eosinophil and IgE+CD1c+ infiltrates, supported the role of dogs as an appropriate model to study pathogenesis of human disease (Willemse 1988; Olivry et al 1997; Lian and Halliwell 1998; Griffin and DeBoer 2001; Hill et al 2001;

Olivry and Hill 2001; Olivry et al 2001; Marsella and Olivry 2003; Vickery 2007; Marsella and Girolomoni 2009).

Epidermal barrier is important to prevent allergen from penetrating into the skin. Epidermal keratinocytes (KCs) move from the basal layer to the spinous layer, granular layer and eventually corneum layer which is the outermost layer of the epidermis. The stratum corneum plays a crucial role in the permeability barrier of the skin since the cornified envelop (CE) proteins, which are transglutaminase cross-linked proteins deposited under the plasma membrane of keratinocytes, are formed in this layer. The CE functions to keep skin moisture. The proliferation and differentiation of KCs are important for cornified envelope associated protein formation in the S. corneum (Ekanayake-Mudiyanselage et al 1998; Marekov and Steinert 1998). A number of CE proteins are coordinately expressed, including IVL, FLG, S100 proteins, etc. Most of them are transglutaminase substrates, used to assemble a cross-linked scaffold beneath the keratinocyte plasma membrane (Hitomi 2005).

Ki-67, a nuclear protein expressed in cycling cells, is widely used in routine pathology as a cell proliferation marker not only in human but also in canine. The Ki-67 antigen is detected within the cell nucleus during interphase but in mitosis it is relocated to the surface of the chromosomes. Ki-67 protein is found during active phases of the cell cycle (G_1 , S, G_2 , and mitosis), but is absent from postmitotic cells (G_0) (Kawahira 1999; Schlozen and Gerdes 2000; Sapuntsova et al 2002; Jensen et al 2004; Bovenschen et al 2005). In the epidermis, basal cells undergo differentiation and maturation, moving into the suprabasal compartment. During this differentiation process, cytokeratins, a major

component of the intracellular cytoskeleton of epidermal cells, are synthesized. Several keratins and CE proteins are associated with the keratinocyte proliferation and differentiation programs, in particular keratin 5 (K5) and K14 which are the main keratins in the basal layer, K1, K2 and K10 in the suprabasal layer, involucrin, loricrin and filaggrin which are CE proteins and terminal differentiation markers (Fuchs and Green 1980; Cline and Rice 1983; Watt 1983; Moll et al 1984; Wertz et al 1989; Mehrel et al 1990; Hohl 1993; Ekanayake-Mudiyanselage et al 1998; Candi et al 2005; Proksch et al 2008; Proksch et al 2009). Disturbed differentiation and epidermal hyperproliferation lead to a defect of skin barrier permeability that enhanced the penetration of environmental allergens (Hudson 2006; Proksch et al 2009). Humans with AD have decreased expression of filaggrin and involucrin in skin (Cline and Rice 1983; Watt 1983; Seguchi 1996; Ekanayake-Mudiyanselage et al 1998). CAD was associated with impaired epidermal barrier, evaluating from increased transepidermal water loss (TEWL) and defect of lipid lamellae in atopic dogs compared with normal controls, (Hightower et al 2008; Inman et al 2001; Shimada et al 2009). The expression of FLG and IVL proteins in CAD were studied but the association to CAD was still unclear (Marsella et al 2009; Chervet et al 2010).

The lymphoepithelial Kazal-type-related inhibitor (LEKTI), encoded by the serine protease inhibitor Kazal-type 5 (SPINK5) gene (Mägert et al 1999), is involved in regulation of proteolysis in epithelia formation and keratinocyte terminal differentiation (Chavanas et al 2000). SPINK5 polymorphism has been reported to be associated with HAD (Walley et al 2001; Kato et al 2003; Namkung et al 2010). LEKTI protein inhibited

proteases matriptase which plays an important role in proteolytically cleavage of profilaggrin to release multiple functional FLG repeat peptide units (List et al 2003; O'Regan et al 2008). LEKTI protein will keep balance of FLG amount. As far as we know, the association of LEKTI and FLG in CAD has not been demonstrated.

The Canine Atopic Dermatitis Extent and Severity Index (CADESI), adapted from the human SCORing Atopic Dermatitis (SCORAD), is recommended by the International Task Force on Canine Atopic Dermatitis for the evaluation of the extent and severity of skin lesions in CAD. The third version of CADESI (CADESI-03) scale consists of the evaluation of 4 different lesions (erythema, excoriations, lichenification, and self induced alopecia) at 62 body sites with a severity scale varied from 0 to 5 as follows: none [0], mild [1], moderate [2,3], and severe [4,5]. Hence, the maximal achievable score was $62 \times 4 \times 5 = 1240$ (Olivry et al 2007).

The aim of this study was to quantify the expression of K5, K10, FLG and IVL in lesional atopic, non-lesional atopic and healthy canine skin either at the protein and gene levels. The keratinocyte proliferation was also studied by Ki-67 expression. The association of the gene and protein expressions in atopic skin with the CADESI-03 score were investigated. Determining the expression pattern of these proteins would help, at least in part, unveil the pathogenesis of CAD.

3. Procedures

Animals

Thirty one dogs were recruited from the private small animal clinics. Table 1 summarized breeds and their health status. The diagnosis of CAD was based on compatible history and clinical signs, exclusion of other causes of pruritus and 5 signs or more under Favrot's 2010 criteria (Favrot et al 2010; Olivry 2010). Bacterial and yeast infections and ectoparasite infestation were controlled prior to inclusion. No anti-inflammatory medication was given for at least 3 weeks prior to examination. Clinical lesions of CAD were scored by using CADESI-03 (Olivry et al 2007). The total score from all clinical signs and body sites was statistically analyzed. Healthy control samples were taken from clinically normal skin and appearances with no history and clinical sign of skin diseases. All animal were obtained under the consents of the dog owners that followed ethical guidelines as required under Chulalongkorn University Animal Care and Use Committee (CU-ACUC), Thailand.

Skin biopsies and tissue samples

A 6-mm skin biopsy specimen of 5-mm depth was taken from the ventral area of each dog to minimize variations due to body location. Lesion samples (n = 10) were selected from the affected areas of erythematous, macular-papular dermatitis and lichenification. Non-lesional samples (n = 10) were taken from clinically unaffected skin of the other atopic dog group whereas control samples (n = 11) were from clinically normal dogs. Biopsy was taken from each dog after local anaesthesia with 2% lidocaine and sutured routinely. Subcutaneous fat was stripped off before each biopsy was bisected. One half was immersion fixed in 10% neutral buffered formalin for 24 h, followed by standard

Table 1 Breeds and health status of dogs included in the study

Breeds	Health Status	Average Age (range, yr)	Numbers
Poodle	CAD	7.8 (3-11)	12
	Healthy control	7.7 (1-10)	7
Shih tzu	CAD	5.8(2-9)	6
	Healthy control	7.3(4-10)	3
Pug	CAD	5.5(5-6)	2
	Healthy control	1	1

tissue processing and paraffin embedding for a routine histopathological and immunohistochemical study. The other half was kept in RNALater solution overnight at 4°C and stored at -20°C until processing for quantitative reverse transcriptase polymerase chain reaction (qRT-PCR).

Histology and Immunohistochemistry:

Formalin fixed paraffin embedded (FFPE) sections of 3 microns were placed on glass slides for routine staining with hematoxylin and eosin (HE) or on positively charged slides for IHC. FFPE tissue was deparaffinized with xylene and rehydrated with a series of graded ethanols. After HE staining, the slides were examined microscopically. Ten fields were randomly selected at x200 magnification and the epidermal thickness was

assessed by measurement of total thickness, nucleated epidermis and S. corneum, using Image-Pro[®] PLUS 6.0 Programming software (Media Cybernetics, Bethesda, MD).

Immunohistochemistry was performed on replicate sections. For Ki-67 and LEKTI antigen retrieval, the slides were incubated in citrate buffer (0.01 M, pH 6.0) at 95°C for 40 min and for the other 4 antigens, the slides were trypsinized by 1.0% trypsin (Merck, Rockland, MA) at 37°C for 15 min. Endogenous peroxidase was quenched by incubating the slides in 3% hydrogen peroxide in dH₂O for 5 min. Nonspecific immunoglobulin binding was blocked with 2% bovine serum albumin at room temperature for 20 min (Merck, Rockland, MA). A mouse monoclonal anti-human Ki-67 antibody (MIB-1) (Dako, Glostrup, Denmark) at dilution 1:200 was used for investigation of the epidermal proliferation. To assess the localization of the CE proteins and epidermal differentiation, a panel of monoclonal and polyclonal antibodies was used as follows: a rabbit polyclonal against human filaggrin, mouse monoclonal against canine involucrin (SY5), mouse monoclonal against canine cytokeratin 10 (DE-K10) antibodies at dilutions of 1:2000, 1:1000 and 1:600, respectively (Abcam, Cambridge, UK), and a mouse monoclonal anti-human cytokeratin 5 clone XM26 antibody (prediluted, Diagnostic Biosystems, Pleasanton, CA) and a rabbit polyclonal anti-human LEKTI antibody (Santa Cruz Biotechnology, Santa Cruz, CA) at a dilution of 1:3000. All antibodies were incubated at 4°C overnight. A Polymer-based nonavidin–biotin system EnVision (Dako, Glostrup, Denmark) was used for immunolabeling at room temperature for 30 minutes followed by a 3, 3'-diaminobenzidine tetrahydrochloride (DAB) solution (ZYMED Laboratories, San Francisco, CA). Slides were counterstained with Mayer's hematoxylin. A positive control

was a human skin section and a negative control slide was healthy dog skin section prepared without the primary antibody.

Quantitative Image Analysis:

Epidermal proliferation in each section was determined by counting the number of keratinocytes staining positive for Ki-67 on the epidermis of each biopsy. The average numbers of positive cells were calculated for the epidermis in the unit 'Positive cells per linear mm of total epidermal surface length'.

For quantitative assessment of filaggrin, involucrin, keratin10 and keratin 5 immunostaining, the staining results were evaluated by a semi-quantitative manual scoring method and by image analysis software. For semi-quantitative manual scoring, the manual scoring of 5 antibodies of positive areas was done by classification into 4 different levels of intensity: 0 (negative), + (mild), ++ (moderate), +++ (strong). Since a number of cells were not positively stained in some compartments of skin, the proportion of positively stained area of the epidermis to negative cells of epidermis was included in this study. The proportion was estimated into four different levels (marked A–D): low proportion (<25% of positive epidermis, A); moderate proportion (25-50% of positive epidermis, B); high proportion (50-75% of positive epidermis, C) and almost all positive areas (more than 75% positive epidermis, D) (Sukjumlong et al 2005). For the image analysis, each sample was performed on 10 randomly selected fields. By using the Image-Pro PLUS 6.0 software (Media Cybernetics, Bethesda, MD), the cytoplasmic staining intensity was divided into four different levels: 0 (negative), 1 (weak), 2

(moderate), and 3 (strong). Percentage of positive area was evaluated from dividing of positive cytoplasmic staining (μm^2) per total area of epidermis (μm^2). The ratio of positive area in combination with intensity score was calculated as 'staining score'. The staining scores were calculated from the summation of (intensity score x percentage of area stained in each level) divided by 100 and the mean of the total scores was calculated and used for analysis.

RNA Extraction

The skin tissues in RNALater solution were disrupted in liquid nitrogen to maintain a low temperature. Total RNA was extracted from skin tissues by homogenization with Trizol reagent (Life Technologies, Carlsbad, CA) and was performed using a phenol/chloroform/isopropyl alcohol technique. Subsequently, genomic DNA traces were removed from RNA with Turbo DNase (Ambion, Austin, TX) to purify total RNA according to the instructions. DNase-treated RNA quality and concentration were analyzed using a NanoDrop ND-1000 Spectrophotometer V3.7 (Thermo Fisher Scientific, Waltham, MA).

Quantitative reverse transcriptase PCR

cDNA synthesis was performed using SuperScript III First-strand synthesis system for RT-PCR (Life Technologies, Carlsbad, CA) according to the manufacturer's instructions. Briefly, one microgram of RNA was reverse transcribed in a 20 μL reaction containing 50 ng random primers, 40U RNase inhibitor and 200U Superscript III enzyme. Real-time

PCR was performed and analyzed on the Rotor Gene 3000 Thermal Cycler (Qiagen, Hilden, Germany). Primers were developed using software from Primer 3 version 0.4.0 (<http://frodo.wi.mit.edu/>). Primer pairs were investigated for specificity and uniqueness in the dog genome (CanFam2.0, May 2005 assembly) in silico, using In-Silico PCR at the UCSC Genome Bioinformatics Site (<http://genome.ucsc.edu/>). The primers sequences, melting temperatures and amplicons were depicted in Table 2. PCR reactions were performed in a 10 μ L volume containing 1x KAPA SYBR Fast qPCR Master Mix. Universal (KAPA Biosystems, Cambridge, MA), 200 nM of each primer and the cDNA template. Thermal cycling conditions were as follows: 95 °C for 2 min for one cycle followed by 40 cycles at 95 °C for 3 s, 60 °C for 20 s and 72 °C for 1 s. Each reaction was performed in duplicate in 3 independent runs. Data from FAM/SYBR channel operating at excitation maximum 495 nm and emission maximum 520 nm was evaluated to ensure that PCR amplification took place. A melting curve analysis was used to determine purity of the amplified products. Prior to this study, potentially suitable reference gene was assessed and *RPS19* was demonstrated to be the most stably expressed among different conditions and therefore the most suitable reference genes to normalize the rest of the samples. Primer sequences and cycling details for quantitative determination of the housekeeping gene *RPS19* has been described before (Brinkhof et al 2006; Wood et al 2008). Relative expression levels were calculated by the REST-384 (Relative Expression Software Tool) software with a detection threshold at 0.1 (Pfaffl et al 2002). Standard curves were generated for each assay using the fluorescent data from 10-fold serial dilutions of total RNA of the same normal dog and the PCR efficiency was calculated

Table 2 Primers used for reverse transcriptase quantitative PCR. Indicated are sequences, annealing temperatures in PCR reactions and expected product sizes.

Genes	Primers (5' to 3')	Annealing temp (°C)	Amplicon (bp)
Involucrin (IVL)	Fwd 5'-AAA GAA GAG CAG GTG CTG GA-3' Rev 5'-TGC TCA CTG GTG TTC TGG AG-3'	60	203
Filaggrin (FLG)	Fwd 5'-GAT GAC CCA GAC ACT GCT GA-3' Rev 5'-TGG TTT TGC TCT GAT GCT TG-3'	60	158
Keratin 5 (K5)	Fwd 5'-TCA ACC AGA GCC TCC TGA CT -3' Rev 5'-CTT GGT GTC CAG GAC CTT GT -3'	60	164
Keratin 10 (K10)	Fwd 5'-TTG AGA CGC ACT GTT CAA GG-3' Rev 5'-AGC TCG GAT CTG TTG CAG TT-3'	60	168
SPINK 5	Fwd 5'-TGA ATT GCG ATG ATT TCA GG-3' Rev 5'-TTG GTC TCA CAT TCC CCT TC-3'	60	178
Ribosomal protein S19 (RPS19)	Fwd 5'-CCT TCC TCA AAA A/GTC TGG G-3' Rev 5'-GTT CTC ATC GTA GGG AGC AAG-3'	60	95

from standard curve slope by a modified delta delta threshold cycle (C_T) method (Pfaffl 2001) and expressed as Target Gene normalized to RPS19. Linearity of the obtained

standard curves was verified by the R^2 coefficient. The efficiency of the assay was between 92% and 131% and the R^2 value was >0.97 .

Statistical analysis

Statistical analysis of the thickness of epidermis, the immunohistochemical staining data, and the correlation of determination (R^2) was conducted using a GraphPad Prism software, version 5.0 (San Diego, California). R^2 shows the regression of CADESI scores (the dependent variable) against ratios of Ki-67/mm skin thickness (the independent variable). For protein staining scores, statistical differences were performed by non-parametric Kruskal-Wallis test and Dunn's multiple comparison post test. For thickness of epidermis and of S. corneum, and ratios of Ki67 positive cells per thickness of epidermis (mm), statistical differences were determined using one-way analysis of variance (ANOVA), and significant differences were determined by a Tukey-Kramer test. For the real-time PCR results, the data were analyzed in REST 384 software, using a pair wise fixed reallocation randomization test to test for significance between groups. The results with P value <0.05 were considered relevant significance.

4. Results

Histopathology

The main histopathological feature was epidermal hyperplasia with predominantly orthokeratotic hyperkeratosis. Compared with normal skins which composed of at least 2-3 well-defined nucleated epidermal layers, the total thickness of lesional and non-lesional

epidermis was significantly higher as shown in Table 3. The histopathological finding was shown in Fig 1. Lesional skins demonstrated epidermal hyperplasia with increased desmosomal junction areas and marked accumulation of cells in S. spinosum. Folds penetrating into dermis were developed. Focal parakeratosis, hypergranulosis, spongiosis and epidermal edema were irregularly appeared in lesional skins together with the aggregation of multifocal microabscesses in superficial epidermis. The dermal change presented edema between collagen bundles and a low-to-mild dermal perivascular inflammatory infiltrate was seen in the lesional skin. The infiltrate was composed by mononuclear cells and a mix of neutrophils, mast cells and eosinophils.

Immunohistochemistry expression of Ki-67, K5, K10, IVL, FLG and LEKTI in CAD lesional, CAD non-lesional, and normal dog skin

IHC for Ki-67 antigen was confined to nuclei of nucleated epidermal cells, indicating increased germinative cells in the basal epidermis. The hyperplastic proliferation rate in epidermis of skin was found to be enhanced in non-lesional and more pronounced in lesional skin as shown by hyperproliferation and hyperplasia indexes as well as the increased staining scores of Ki-67 proliferative activity (Fig 2A-C, Table 4). The result correlated with the lesional appearance of the skin.

Whereas in normal dog skin, K5 is exclusively synthesized by basal cells, in lesional and non-lesional skins, the staining of K5 extended to suprabasal compartment with reduced staining intensity. In non-lesional skins, the staining was mainly concentrated in

Table 3 Thickness of epidermis and ratio of S. corneum and nucleated epidermis of non-lesional and lesional skin of dogs with AD

	Normal	CAD non-lesion	CAD lesion
Thickness of S. corneum (μm)	7.746 ± 2.535^a	11.879 ± 3.242^b	34.857 ± 9.106^c
Thickness of nucleated epidermis (μm)	14.818 ± 2.271^a	24.250 ± 5.940^b	137.214 ± 40.210^c
Ratio of S. corneum and nucleated epidermis	0.493 ± 0.132^a	0.568 ± 0.255^a	0.273 ± 0.080^b

The superscript letters are significant different (one way ANOVA at $P < 0.05$).

Fig. 1 Histopathology of normal clinical (A), CAD lesional (B) and non-lesional skins (C) (scale bar in A = $20\mu\text{m}$; scale bars in B and C = $50\mu\text{m}$)

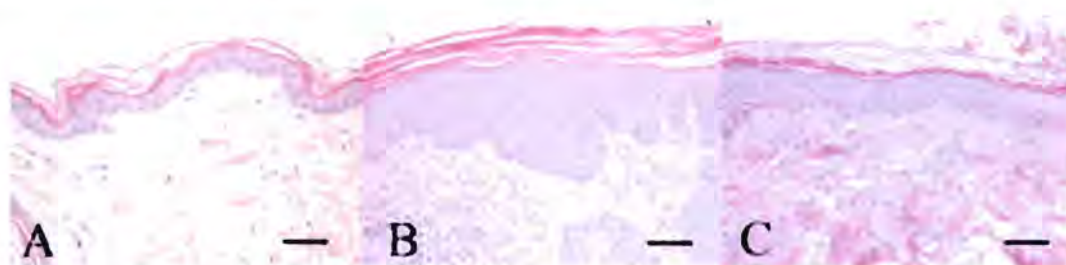


Fig. 2 Immunohistochemical staining for Ki-67, K5, K10, IVL, FLG and LEKTI. (a) Ki-67-positive cells and K5, K10, IVL, FLG and LEKTI staining scores in normal, lesional and non-lesional skins. Bars indicate mean \pm SD data with significant *P*-values $*P < 0.05$. (b) Protein expression of Ki-67, K5, K10, IVL, FLG and LEKTI in normal (at $\times 100$ magnification, scale bars = 20 μm) (A, D, G, J, M, P), lesional (at $\times 200$ magnification, scale bars = 50 μm) (B, E, H, K, N, Q) and non-lesional skins (at $\times 200$ magnification, scale bars = 50 μm) (C, F, I, L, O, R).

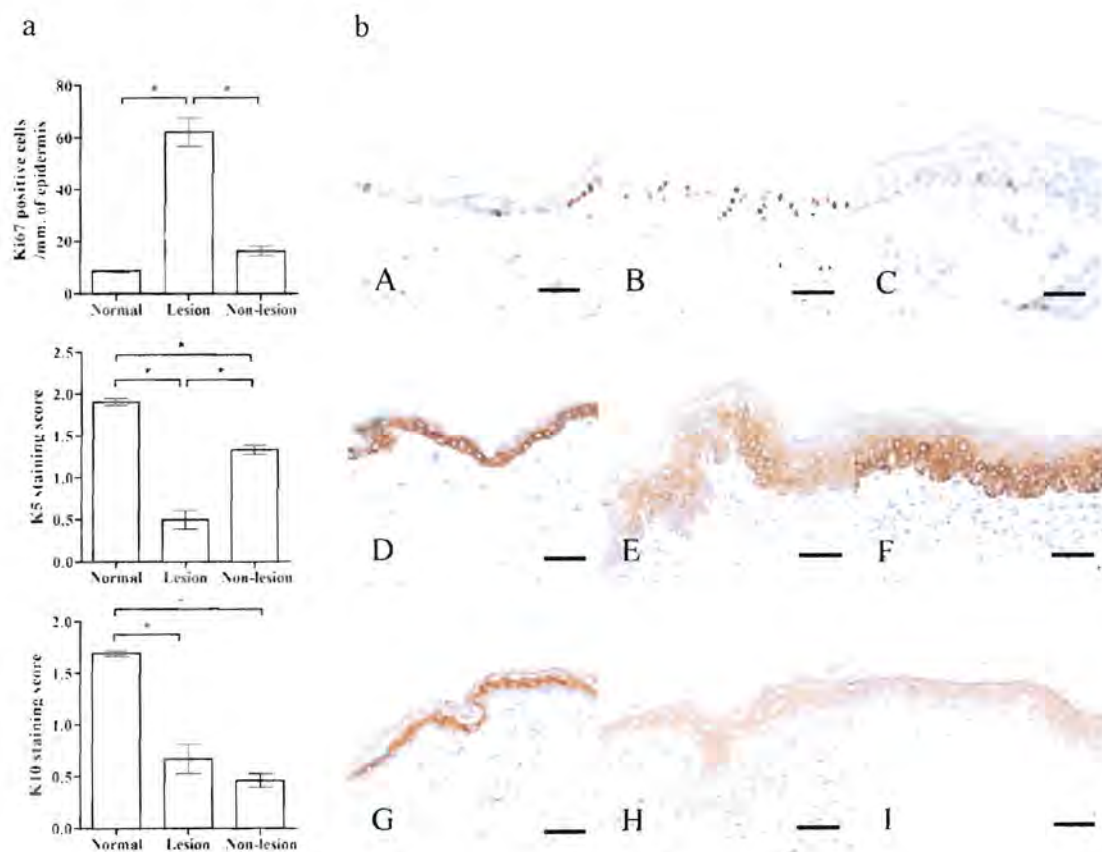


Fig. 2 Continued

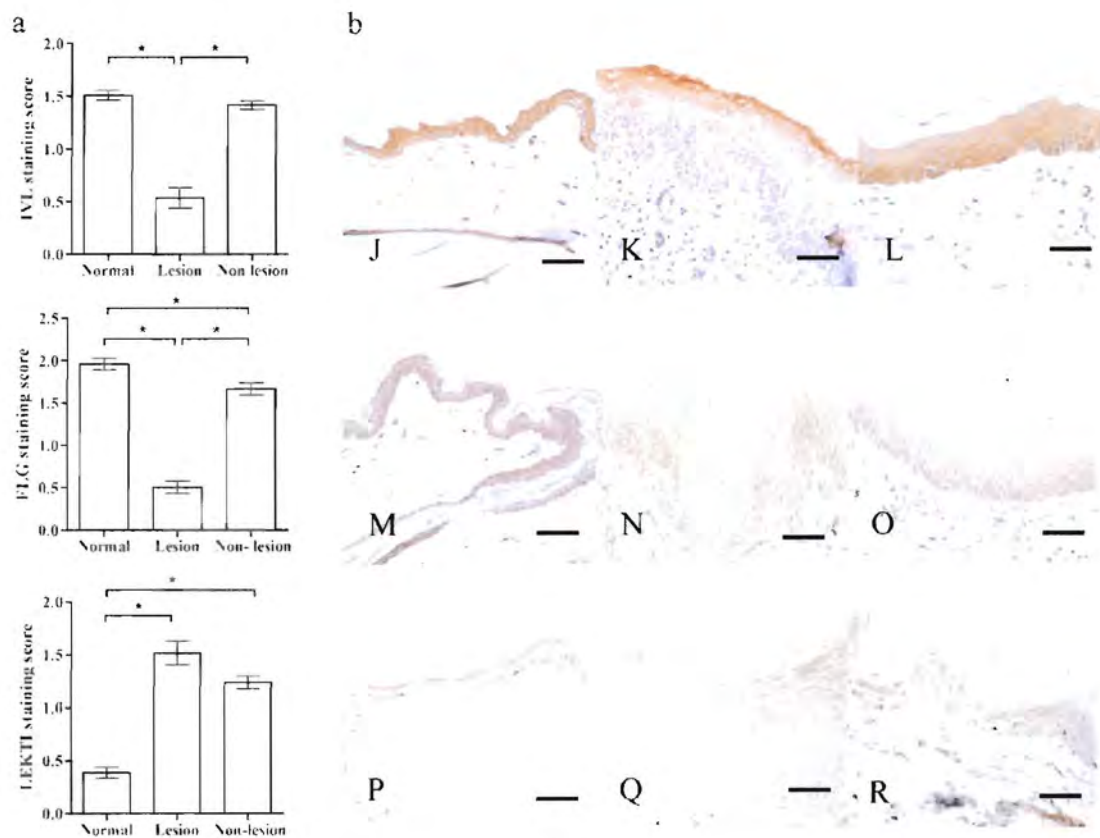


Table 4 IHC staining scores of K5, K10, IVL, FLG expression by semi-quantitative manual scoring for normal, non-lesional and lesional skin of CAD

	Normal	CAD non-lesional skin	CAD lesional skin
	Manual score	Manual score	Manual score
K5	+++ C	++/+++ C-D	+/+++ C-D
K10	+++ B	++/+++ C-D	+/+++ B-D
IVL	++/+++ D	+/+++ C-D	0/++ A-B
FLG	++/+++ D	+/+++ C-D	0/+++ A-B
LEKTI	++/+++ A	++/+++ B-C	++/++ B-C

Semi-quantitative manual scoring; staining intensity 0, negative; +, mild; ++, moderate; +++, strong. A, low proportion (< 25%); B, moderate proportion (25-50%); C, high proportion (50-75%); D, almost entire proportion (more than 75%) are positive of epidermis.

basal layers but the extension to suprabasal epidermis with mild to moderated expression occurred. In lesional skins, expression was in S. basale and S. spinosum with a significantly reduced intensity compared with normal skins. K5 expression was observed in the areas that corresponding to low K10 staining. The IHC staining scores for CAD were decreased in non-lesional and much less in lesional skins compared to the controls (Fig 2D-F, Table 4).

The differentiation-associated K10 was expressed throughout the suprabasal compartment in normal skins whilst in non-lesional and lesional skin, K10, although less intensive, was found primarily within the uppermost suprabasal cell layers, in S. corneum and the upper part of S. granulosum. The IHC staining scores for CAD were decreased in lesional and non-lesional skins compared to the controls. However, there was no significant difference between non-lesional and lesional skins by image analysis ($P > 0.05$) (Fig 2G-I, Table 4).

The expression of IVL and FLG, marker proteins of early and late epidermal differentiation, respectively (Fuchs 1990), was analyzed. IVL was observed with a brown to deep brown, granular like appearance in the entire nucleated epidermal layers to the lower part of S. corneum in normal skins. The intensity was significantly decreased in lesional skin. Irregular and discontinuous expression pattern with variable epidermal cell layers of S. granulosum and S. spinosum was observed. Decreased to absent intensity was revealed in the lower part of S. spinosum and basal layers whereas in granulosum markedly with inflammatory cell infiltration and spongiotic areas, the staining was almost disappeared (Fig 2J-L, Table 4). FLG immunohistochemical staining appeared in the entire nucleated epidermis. FLG expression was significantly reduced in lesional skin similar to IVL ($P < 0.05$). The lesion showed very weak intensity in the lower part of S. granulosum, S. spinosum and S. basale, whereas discontinuous staining was revealed in the upper part of S. granulosum and S. corneum (Fig 2M-O, Table 4).

LEKTI was obviously expressed as a band in S. corneum of normal skin with moderate to strong intensity. In contrast, owing to epidermal hyperplasia in lesional skins, LEKTI

was expressed with variable degrees in lower part of S. corneum to the upper part of S. spinosum. In spongiotic and parakeratotic areas, the staining intensity was very strong. The staining in non-lesional skins was predominantly at the S. corneum and S. granulosum without spongiosis and parakeratosis. The IHC staining scores for CAD were significantly increased in non-lesional and more pronounced in lesional skins compared to the controls ($P < 0.05$).

The protein expression in both lesional and non-lesional samples was compared with clinical severity scores CADESI-03. Ki-67 staining nuclei of both lesional and non-lesional skins was shown to be significantly positively correlated with clinical severity scores ($P < 0.01$, $R^2 = 0.70$; $P < 0.01$, $R^2 = 0.64$, respectively) (Fig 3A-B) similar to those of K5 ($P < 0.01$, $R^2 = 0.70$; $P < 0.05$, $R^2 = 0.54$, respectively) (Fig 4A-B), whereas IVL staining scores were shown to be significantly negatively correlated with the severity scales ($P < 0.001$, $R^2 = 0.62$; $P < 0.05$, $R^2 = 0.51$, respectively) (Fig 4C-D). Furthermore, LEKTI staining scores of lesional skins were shown to be significantly positively correlated with clinical severity scores ($P < 0.05$, $R^2 = 0.58$) (Fig 4E).

Gene expression in CAD lesional, CAD non-lesional and healthy dog skin

K5, *IVL* and *FLG* showed distinct increases in mRNA in lesional skin and between non-lesional and lesional skin. Merely *K5* showed a statistically significant difference in expression between non-lesional and control skin but with a lesser expression than in lesional skin. *K10* expression tended to be upregulated in lesional skin compared to the

Fig. 3 Correlation between CADESI-03 and Ki-67 staining nuclei in lesional and non-lesional skin of dogs with AD. Association of CADESI-03 and Ki-67 staining nuclei in lesional and non-lesional skins is presented (Fig. 3A-B, respectively).

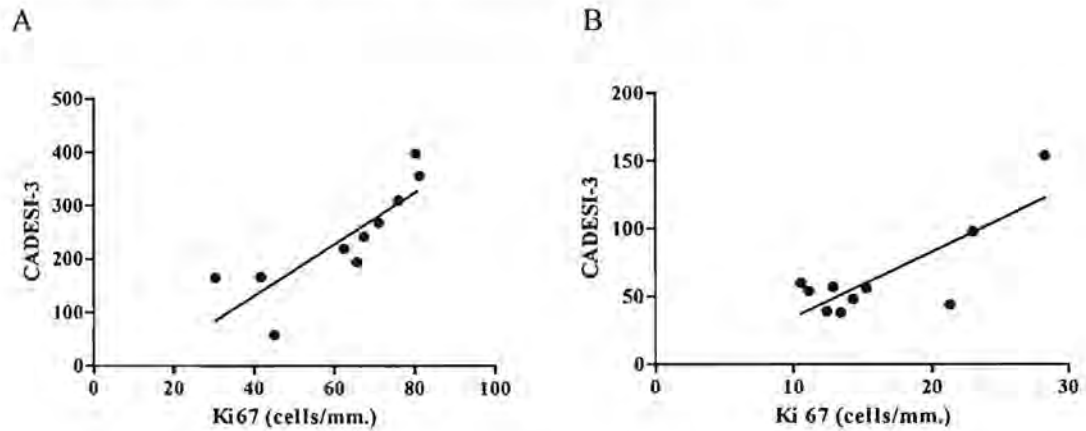


Fig. 4 Correlation between CADESI-03 K5 and IVL staining scores in lesional and non-lesional skin of dogs with AD. Association of CADESI-03 and K5 staining scores in lesional and non-lesional skins (Fig. 4A-B, respectively); Association of CADESI-03 and IVL staining scores in lesional and non-lesional skins (Fig. 4C-D, respectively); Association of CADESI-03 and LEKTI staining scores in lesional skin (Fig. 4E).

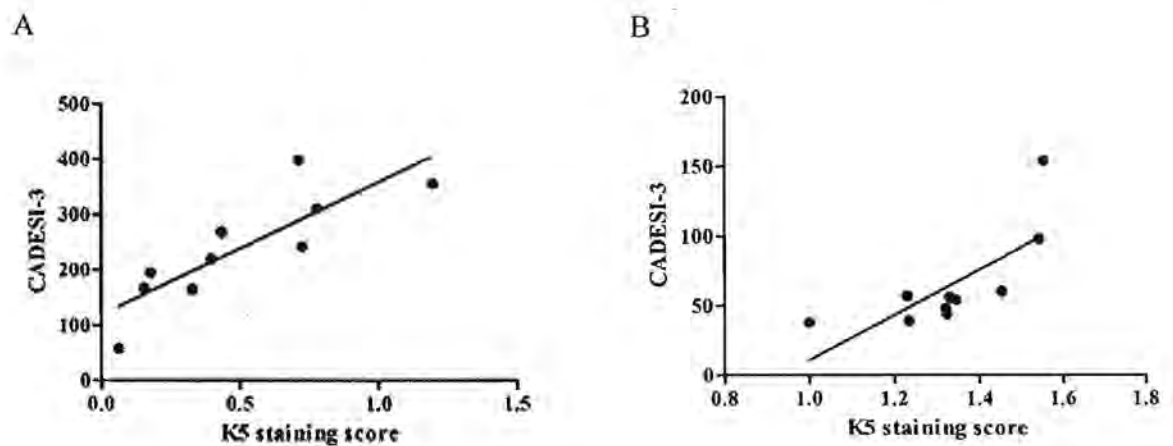
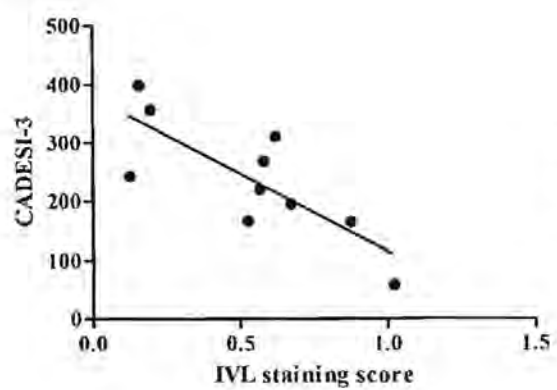
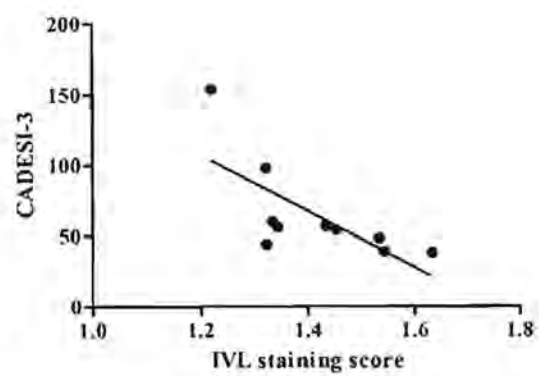


Fig. 4 (Continued)

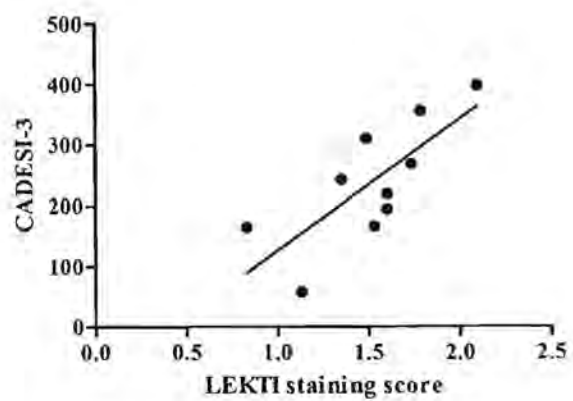
C



D



E



controls although this was not statistically significant due to the large variation between individual cases (Table 5).

5. Discussion

The present study demonstrated the role of keratins 5 and 10, IVL and FLG in keratinocyte activation and differentiation in CAD. Predominant accumulation of anuclear keratin in S. corneum layer of CAD reflected orthokeratotic hyperkeratosis. Together with other histopathological findings, the microscopic change of CAD lesional skin in the present study were resemble to the previous reports, showing epidermal hyperplasia, hyperkeratosis, hypergranulosis and spongiosis (Yager and Wilcock 1994; Olivry et al 1997; de Mora et al 2007). The CAD histology was similar to that of human chronic AD (Leung 1999). In addition, similar skin-infiltrating cells contributed of mononuclear cells, neutrophils, mast cells and eosinophils were observed in our study and others (Yager and Wilcock 1994; Olivry et al 1997; Scott et al 2001; de Mora et al 2007).

From the significantly increased expression of Ki-67 in atopic skins, it can be implied that epidermal hyperplasia in lesional CAD skins were also associated with an accumulation of cell number. This hyperproliferation-associated hyperplasia is in agreement with earlier studies in HAD (Kawahira 1999; Sapuntsova et al 2002; Jensen et al 2004; Bovenschen et al 2005). Skin of human AD was shown to be highly proliferated, reflected by *in vitro* incorporation of tritiated thymidine (Van Neste et al 1979). Hyperproliferation was probably to reconstitute normal barrier function and to remove

Table 5 Fold change in gene-specific mRNA expression in CAD lesional, CAD non-lesional and control dog skin

Gene	lesion vs. normal		non-lesion vs. normal		lesion vs. non-lesion	
	Fold change	<i>P</i> value*	Fold change	<i>P</i> value*	Fold change	<i>P</i> value*
<i>K5</i>	<i>4.947</i>	0.009	<i>3.884</i>	0.011	<i>1.274</i>	0.597
<i>K10</i>	1.271	0.467	0.773	0.520	1.643	0.238
<i>IVL</i>	<i>4.793</i>	0.003	1.651	0.289	<i>2.903</i>	0.014
<i>FLG</i>	<i>4.040</i>	0.001	1.252	0.576	<i>3.226</i>	0.009
<i>SPINK5</i>	1.086	0.774	0.986	0.960	1.101	0.705

*Pair wise fixed reallocation randomization test normalizes by reference gene. Results in italics indicate a significant difference ($P < 0.05$).

invaded antigens (Jensen et al 2004). In dog, generally after skin irritation or superficial trauma of epidermis, the mitotic activity of basal epidermal cells are induced to generate new cell population which result in epidermal hyperplasia within 36-48 hr (Yager and Wilcock 1994). The correlations of Ki-67 staining scores with CADESI in the present study suggest an association between hyperproliferation-associated hyperplasia and disease severity.

Hyperproliferation is usually accompanied by disturbed differentiation, probably due to insufficient time for cells to be differentiated, a critical period for the permeability barrier formation (Ekanayake-Mudiyanselage et al 1998; Jensen et al 2004). In the

present study, the reduced and irregular immunostaining of IVL, FLG and K10, marker proteins of keratinocyte differentiation, in lesional and non-lesional CAD samples indicates that hyperkeratosis of CAD epidermis probably resulted from a decelerated desquamation of cornified cells rather than an accelerated cornification (Neufang et al 2001). In addition, since Ki-67 expression showed the hyperproliferation of lesional skin, hence, it could be implied that in CAD, an accumulation of proliferative keratinocytes occurred by obstructing the further postmitotic state which was associated with the reduced expression of the mentioned differentiation-associated proteins.

In our study, K5 immunostaining was found merely in the S. basale in normal controls whereas the staining was extended to suprabasal layers, S. spinosum in lesional or non-lesional skins similar to the HAD study of Jensen et al (2004). Extended K5 immunostaining in suprabasal cells of atopic skins may reflect epitope unmasking in suprabasal cells because K5 protein was reported to be in a masked form in suprabasal normal keratinocytes (Lloyd et al 1995). On the other hand, together with high skin proliferation rate in CAD from Ki-67 immunostaining data and the less K10 staining in the area with high K5 staining in the suprabasal layers, it was suggested that some immature cells could not change to be the mature suprabasal ones. Since the positive correlation between K5 and CADESI was found, K5 protein expression was expected to be increased. However, the aberrantly reduced K5 expression was found. Association of CAD with other proliferation-associated keratins such as K6 and K16, which are highly expressed in the suprabasal levels in lesional AD (Jensen et al 2004), should be further investigated.

In normal control, K10 was expressed in the entire suprabasal compartment similar to the report of Jensen et al (2004). In both lesional and non-lesional CAD skin, K10 was concentrated in S. corneum and the upper part of S. granulosum, higher layers than the granular and upper spinous layers in human AD. In addition, unlike human K10 staining in HAD (Jensen et al 2004), we found that K10 was a sensitive marker for keratinocyte differentiation, as staining in both lesional and non-lesional skin was observed compared with the normal ones. We found the reduction of K10 in lesional skin which is corresponding to K10 expression in HAD (Jensen et al 2004). Reduced K10 was found in dry skin (Engelke et al 1997) and after acute experimental barrier disruption (Ekanayake-Mudiyanselage et al 1998). An impaired permeability barrier was also demonstrated in K10 deficient mice (Jensen et al 2000). Hence, reduced K10 expression may be related to dry skin conditions and to disturbed barrier function.

IVL, regarded as a marker of keratinocyte differentiation, is a major component of the cornified cell envelope (CE) (Steinert and Marekov 1997; Candi et al 2005; Proksch et al 2008). IVL binds with ester linkages to ceramide, one of the component lipids that make up sphingomyelin in lipid bilayer of cell membrane. (Wertz and Downing 1986; Marekov and Steinert 1998). In our study, IVL staining was observed in the entire nucleated epidermal layers to lower horny layer in normal dog skins. Human IVL was described to be normally expressed in upper spinous layers and the S. granulosum. We found that it was difficult to differentiate immunostained cell layers in normal dog skins because dog's skin (10-30 μm) is thinner than that of human (50-100 μm) (Lloyd and Garthwaite 1982; Kanistakis 2002). Hence, dog's skin is more sensitive. However, similar to HAD,

IVL protein expression was significantly decreased in CAD skins ($P < 0.001$) although the immunostaining band of atopic skins was broadened. Reduced IVL staining in HAD due to less *S. spinosum* formation in AD caused the reduced number of ceramides (Seguchi et al 1996; Jensen et al 2004; Jarzab et al 2010). The band was expanded to the lower spinous layer in non-lesional and lesional skin (Jensen et al 2004). An inverse correlation between IVL staining scores and disease severity scores CADESI-03 strongly supported the role of IVL in CAD. However, the aberrant increased IVL expression in CAD was demonstrated (Chervet et al 2010).

During epidermal differentiation, FLG and IVL play a crucial role in the formation of the CE, an insoluble protein structure underneath the plasma membrane (Sandilands et al 2007; Sandilands et al 2009) and establishment of epidermal barrier function. In dogs, several studies of FLG immunostaining were demonstrated. Bardagi et al (2007) showed the expression of filaggrin in cytoplasmic and keratohyalin granules in the epidermal granular layer in normal dog skin. In our study, FLG staining in normal skins was found in all epidermal layers, owing to very thin layers of dog skin as above-mentioned. We also showed that the FLG staining in atopic dogs was significantly reduced compared to the controls. This result is corresponding to reduced FLG expression in 39% (7 of 18) of dogs with AD compared with that of controls when using the N- and C-terminal FLG antibodies (Chervet et al 2010). Immunostaining observed in most epidermal layers probably indicated the cross-reactivity with other epidermal proteins as suggested by Marsella et al (2009). However, the significant reduction of the FLG protein expression in both lesional and non-lesional skins of CAD supported its role as a CE protein in skin

maintenance. In addition, decreased FLG immunostaining was remarkably found in both lesional and non-lesional skins of HAD (Seguchi et al 1996; Jensen et al 2004).

Increased IVL and FLG expression together with the decreased keratinocyte proliferation were used as protein makers, showing recovery of treated keratinocyte as well as improvement of skin barrier permeability e.g. after AD therapy with suberythemal UV B (Hong et al 2008a), after treatment of primary keratinocyte with rose absolute oil (Kim et al 2010), after treatment of mite antigen-stimulated human skin keratinocyte, HaCat cells, with a phytosphingosine-like substance from starfish (Choi et al 2010), after treatment of HaCat cells with K6PC-5, a direct activator of sphingosine kinase 1 (Hong et al 2008b), and after treatment of primary keratinocyte with silica and mud from Blue Lagoon (Grether-Beck et al 2008).

A serine protease inhibitor LEKTI protein expression was found in the present study to be significantly increased in CAD lesional samples. This is consistent with the lower expression of FLG since LEKTI protein has been demonstrated to inhibit proteases matriptase which has an important function in proteolytically cleavage of profilaggrin, leading to the loss of proteolytically processed filaggrin (List et al 2003; O'Regan et al 2009). LEKTI staining scores was also significantly correlated with the clinical severity scores. This is corresponding to the trend of inversed correlation of FLG staining scores and the clinical severity scores although not reaching statistical significance (data not shown).

To understand biological events or pathogenesis of CAD at the mRNA level, diagnostic techniques such as quantitative RT-PCR were performed. The up-regulation of

IVL, *FLG* and *K5* mRNA expression in lesional skin compared to the control was observed. This was not associated with a decrease in their protein expression. A significant upregulation of *IVL* RNA has been described in lesional HAD skin (Jarzab et al 2010), on a contrary, a reduced *IVL* protein expression was demonstrated (Seguchi et al 1996; Jensen et al 2004). For *FLG*, a non-associated mRNA-protein expression of *FLG* was shown. Whereas *FLG* mRNA did not significantly change, the protein was decreased in HAD compared to the normal ones (Jarzab et al 2010).

In accordance with molecular central dogma, mRNAs is referred to as the transcriptome, then serves as the template for protein synthesis (Crick 1970); however, it is yet unclear how strongly specific mRNA levels correlate with the abundance of corresponding protein since several researches demonstrated different results between mRNA and protein expressions (Chen et al 2002; Strömberg et al 2007; Fournier et al 2010). The absent correlation between mRNA and protein levels may be due to i.) variable and complicated post-transcriptional steps, which are not well defined, including protein translation, post-translational modification, the number of isoforms for each gene (Szallasi 1999; Baldi and Long 2001; Chen et al 2002; Strömberg et al 2007), ii.) different protein turnover rate or different *in vivo* half lives due to varied protein synthesis and degradation (Glickman and Ciechanover 2002; Pratt et al 2002) and iii.) the noise and error in mRNA and protein expression experiments including the specificity of the antibody used (Qian et al 2003; Strömberg et al 2007). Moreover, the mutation of the gene may lead to reduced protein expression without any effect on the transcription level (e.g. *FLG* gene). Lack of C-terminal *FLG* was observed in some AD dogs suggesting the

mutation of the *FLG* gene (Chervet et al 2010) which is corresponding to the loss-of-function *FLG* mutation in HAD (Palmer et al 2006). The mutations of *FLG* gene in HAD may not be related to the decrease in mRNA expression because the mutated full-length mRNA transcript was found (Marenholz et al 2006; Palmer et al 2006; Sandilands et al 2007). However, a recent study in West Highland White Terriers demonstrated that atopic and normal dogs did not display significantly difference of *FLG* haplotype frequencies (Barros Roque et al 2009). Thus, the association of AD with the gene expression and/or mutation was needed to be further investigated.

6. Conclusion

In conclusion, this study reveals, at least in part, the pathogenesis of CAD. Dogs with AD are predisposed to develop hyperproliferation and alterations in differentiation of their skin keratinocytes, leading to epidermal hyperplasia. This was supported by histopathologically increased Ki-67 positive basal cells and reduced cytokeratins and CE protein expression although the dissociation between gene and protein expression was observed. Since IVL and Ki-67 protein expression was shown to be associated with the AD clinical severity scores in the present study and some topical drugs demonstrated keratinocyte antiproliferation and enhanced IVL expression (Hong et al 2008b; Kim et al 2010), IVL and Ki-67 could probably be used as protein markers in AD therapy.

7. Suggestion for Future Work

For the future work, the correlation of epidermal proliferation and differentiation to dry skin should be further investigated in CAD since skin dehydration were shown to be increased together with epidermal proliferation in human AD skin (Jensen et al 2004) and increased transepidermal water loss (TEWL) and decreased skin hydration and ceramides, lipid contents of the skin, was found in lesional CAD skin compared to the normal controls (Shimada et al 2009).

8. References

- Baldi P, Long AD (2001) A Bayesian framework for the analysis of microarray expression data: regularized t-test and statistical inferences of gene changes. *Bioinformatics* 17:509-519.
- Bardagi M, Vala H, Fondevila D, Ferrer L (2007) Immunohistochemical detection of filaggrin in the skin of different species. *Vet Dermatol* 18:388.
- Barros Roque J, O'Leary CA, Kyaw-Tanner M, et al (2009) Haplotype sharing excludes canine orthologous Filaggrin locus in atopy in West Highland White Terriers. *Anim Genet* 40:793-794.
- Bovenschen HJ, Seyger MM, Van de Kerkhof PC (2005) Plaque psoriasis vs. atopic dermatitis and lichen planus: a comparison for lesional T-cell subsets, epidermal proliferation and differentiation. *Br J Dermatol* 153:72-78.
- Brinkhof B, Spee B, Rothuizen J, Penning LC (2006) Development and evaluation of canine reference genes for accurate quantification of gene expression. *Anal Biochem* 356:36-43.
- Candi E, Schmidt R, Melino G (2005) The cornified envelope: a model of cell death in the skin. *Nat Rev Mol Cell Biol* 6:328-340.
- Chavanas S, Bodemer C, Rochat A, et al (2000) Mutations in SPINK5, encoding a serine protease inhibitor, cause Netherton syndrome. *Nat Genet* 25:141-142.

- Chervet L, Galichet A, McLean WH, et al (2010) Missing C-terminal filaggrin expression, NFkappaB activation and hyperproliferation identify the dog as a putative model to study epidermal dysfunction in atopic dermatitis. *Exp Dermatol* 19:e343-e346.
- Choi GH, Wahid F, Kim YY (2010) The effect of a phytosphingosine-like substance isolated from *Asterina pectinifera* on involucrin expression in mite antigen-stimulated HaCaT cells. *Nat Prod Commun* 5:1081-1084.
- Cline PR, Rice RH (1983) Modulation of involucrin and envelope competence in human keratinocytes by hydrocortisone, retinyl acetate, and growth arrest. *Cancer Res* 43:3203-3207.
- Crick F HC (1970) Central dogma of molecular biology. *Nature* 227: 561-563.
- de Mora F, de la Fuente C, Jasmin P, et al (2007) Evaluation of the expression of P-selectin, ICAM-1, and TNF-alpha in bacteria-free lesional skin of atopic dogs with low-to-mild inflammation. *Vet Immunol Immunopathol*. 115:223-229.
- DeBoer DJ, Hillier A (2001) The ACVD task force on canine atopic dermatitis (XVI): laboratory evaluation of dogs with atopic dermatitis with serum-based "allergy" tests. *Vet Immunol Immunopathol* 81:277-287.
- Descargues P, Deraison C, Bonnart C, et al (2005) Spink5-deficient mice mimic Netherton syndrome through degradation of desmoglein 1 by epidermal protease hyperactivity. *Nat Genet* 37:56-65.

- Ekanayake-Mudiyanselage S, Aschauer H, Schmook FP, et al (1998) Expression of epidermal keratins and the cornified envelope protein involucrin is influenced by permeability barrier disruption. *J Invest Dermatol* 111:517–523.
- Engelke M, Jensen JM, Ekanayake-Mudiyanselage S, Proksch E (1997) Effects of xerosis and ageing on epidermal proliferation and differentiation. *Br J Dermatol* 137:219–225.
- Favrot C, Steffan J, Seewald W, Picco F (2010) A prospective study on the clinical features of chronic canine atopic dermatitis and its diagnosis. *Vet Dermatol* 21:23–31.
- Fournier ML, Paulson A, Pavelka N, Mosley AL, Gaudenz K, Bradford WD, Glynn E, Li H, Sardu ME, Fleharty B, Seidel C, Florens L, Washburn MP (2010) Delayed correlation of mRNA and protein expression in rapamycin-treated cells and a role for Ggcl in cellular sensitivity to rapamycin. *Mol Cell Proteomics* 9:271–284.
- Fraser MA, McNeil PE, Girling SJ (2008) Prediction of future development of canine atopic dermatitis based on examination of clinical history. *J Small Anim Pract* 49:128–132.
- Fuchs E, Green H (1980) Changes in keratin gene expression during terminal differentiation of the keratinocyte. *Cell* 19:1033–1042.
- Fuchs E (1990) Epidermal differentiation: the bare essentials. *J Cell Biol.* 111:2807–2814.
- Glickman MH, Ciechanover A (2002) The ubiquitin-proteasome proteolytic pathway: destruction for the sake of construction. *Physiol Rev* 82:373–428.
- Grether-Beck S, Mühlberg K, Brenden H, et al (2008) Bioactive molecules from the Blue Lagoon: in vitro and in vivo assessment of silica mud and microalgae extracts for

- their effects on skin barrier function and prevention of skin ageing. *Exp Dermatol* 17:771-779.
- Griffin CE, DeBoer DJ (2001) The ACVD task force on canine atopic dermatitis (XIV): clinical manifestations of canine atopic dermatitis. *Vet Immunol Immunopathol* 81:255–269.
- Halliwell R (2006) Revised nomenclature for veterinary allergy. *Vet Immunol Immunopathol* 114:2007–2008.
- Hightower K, Marsella R, Creary E, Dutcher P (2008) Evaluation of transepidermal water loss in canine atopic dermatitis: a pilot study in Beagle dogs sensitized to house dust mites. *The 23rd Proceedings of the North American Veterinary Dermatology Forum*, 183.
- Hill PB, Hillier A, Olivry T (2001) The ACVD task force on canine atopic dermatitis (VI): IgE-induced immediate and late-phase reactions, two inflammatory sequences at sites of intradermal allergen injections. *Vet Immunol Immunopathol* 81:199–204.
- Hillier A, DeBoer DJ (2001). The ACVD task force on canine atopic dermatitis (XVII): intradermal testing. *Vet Immunol Immunopathol* 81:289–304.
- Hillier A, Griffin CE (2001) The ACVD task force on canine atopic dermatitis (I): incidence and prevalence. *Vet Immunol Immunopathol* 81:147-151.
- Hitomi K (2005) Transglutaminases in skin epidermis. *Eur J Dermatol* 15:313–319.
- Hohl D (1993) Expression patterns of loricrin in dermatological disorders. *Am J Dermatopathol* 15:20–27.

- Hong SP, Kim MJ, Jung MY, Jeon H, et al (2008a) Biopositive effects of low-dose UVB on epidermis: coordinate upregulation of antimicrobial peptides and permeability barrier reinforcement. *J Invest Dermatol* 128:2880-2887.
- Hong JH, Youm JK, Kwon MJ, et al (2008b) K6PC-5, a direct activator of sphingosine kinase 1, promotes epidermal differentiation through intracellular Ca²⁺ signaling. *J Invest Dermatol* 128:2166-2178.
- Hudson TJ (2006) Skin barrier function and allergic risk. *Nature Genetics* 38: 399–400.
- Inman AO, Olivry T, Dunston SM, Monteiro-Riviere NA, Gatto H (2001) Electron microscopic observations of stratum corneum intercellular lipids in normal and atopic dogs. *Vet Pathol* 38:720–723.
- Jarzab J, Filipowska B, Zebracka J, et al (2010) Locus Iq21 gene expression changes in atopic dermatitis skin lesions: deregulation of small proline-rich region 1A. *Int Arch Allergy Immunol* 151:28-37.
- Jensen JM, Folster-Holst R, Baranowsky A, et al (2004) Impaired sphingomyelinase activity and epidermal differentiation in atopic dermatitis. *J Invest Dermatol* 122:1423–1431.
- Jensen JM, Schütze S, Neumann C, Proksch E (2000) Impaired cutaneous permeability barrier function, skin hydration, and sphingomyelinase activity in keratin 10 deficient mice. *J Invest Dermatol* 115:708-713.
- Kanitakis J (2002) Anatomy, histology and immunohistochemistry of normal human skin. *Eur J Dermatol* 12:390-401.

- Kato A, Fukai K, Oiso N, et al (2003) Association of SPINK5 gene polymorphisms with atopic dermatitis in the Japanese population. *Br J Dermatol* 148:665-669.
- Kawahira K (1999) Immunohistochemical staining of proliferating cell nuclear antigen (PCNA) in malignant and nonmalignant skin diseases. *Arch Dermatol Res* 291:413-418.
- Kim JH, Choi DK, Lee SS, et al (2010) Enhancement of keratinocyte differentiation by rose absolute oil. *Ann Dermatol* 22:255-261.
- Leung DY (1999) Pathogenesis of atopic dermatitis. *J Allergy Clin Immunol* 104:S99-S108.
- Lian TM, Halliwell RE (1998) Allergen-specific IgE and IgG antibodies in atopic and normal dogs. *Vet Immunol Immunopathol* 66:203-223.
- List K, Szabo R, Wertz PW, et al (2003) Loss of proteolytically processed filaggrin caused by epidermal deletion of Matriptase/MT-SPI. *J Cell Biol* 163:901-910.
- Lloyd C, Yu Q, Cheng J, et al (1995) The basal keratin network of stratified squamous epithelia: defining K15 function in the absence of K14. *J Cell Biol* 129:1329-1344.
- Lloyd DH, Garthwaite G (1982) Epidermal structure and surface topography of canine skin. *Res Vet Sci* 33:99-104.
- Mägert HJ, Ständker L, Kreutzmann P, et al (1999) LEKTI, a novel 15-domain type of human serine proteinase inhibitor. *J Biol Chem* 274:21499-21502.
- Marekov LN, Steinert PM (1998) Ceramides are bound to structural proteins of the human foreskin epidermal cornified cell envelope. *J Biol Chem* 273:17763-17770.

- Marenholz I, Nickel R, Ruschendorf F, et al (2006) Filaggrin loss-of-function mutations predispose to phenotypes involved in the atopic march. *J Allergy Clin Immunol* 118: 866–871.
- Marsella R, Girolomoni G (2009) Canine models of atopic dermatitis: a useful tool with untapped potential. *J Invest Dermatol* 129: 2351–2357.
- Marsella R, Olivry T (2003) Animal models of atopic dermatitis. *Clin Dermatol* 21:122–133.
- Marsella R, Samuelson D, Harrington L (2009) Immunohistochemical evaluation of filaggrin polyclonal antibody in atopic and normal beagles. *Vet Dermatol* 20:547-554.
- Mehrel T, Hohl D, Rothnagel JA, et al (1990) Identification of a major keratinocyte cell envelope protein, loricrin. *Cell* 61:1103–1112.
- Moll R, Moll I, Franke WW (1984) Differences of expression of cytokeratin polypeptides in various epithelial skin tumors. *Arch Dermatol Res* 276:349–363.
- Namkung JH, Lee JE, Kim E, et al (2010) Hint for association of single nucleotide polymorphisms and haplotype in SPINK5 gene with atopic dermatitis in Koreans. *Exp Dermatol* 19:1048-1053.
- Neufang G, Furstenberger G, Heidt M, Marks F, Müller-Decker K (2001) Abnormal differentiation of epidermis in transgenic mice constitutively expressing cyclooxygenase-2 in skin. *Proc Natl Acad Sci U S A* 98:7629-7634.
- Olivry T, DeBoer DJ, Favrot C, et al (2010) Treatment of canine atopic dermatitis: 2010 clinical practice guidelines from the International Task Force on Canine Atopic Dermatitis. *Vet Dermatol* 21:233-248.

- Olivry T, DeBoer DJ, Griffin CE (2001) The ACVD task force on canine atopic dermatitis: forewords and lexicon. *Vet Immunol Immunopathol* 81:143–146.
- Olivry T, Hill PB (2001) The ACVD task force on canine atopic dermatitis (XVIII): histopathology of skin lesions. *Vet Immunol Immunopathol* 81:305–309.
- Olivry T, Marsella R, Iwasaki T, Mueller R (2007) Validation of CADESI-03, a severity scale for clinical trials enrolling dogs with atopic dermatitis. *Vet Dermatol* 18:78–86.
- Olivry T, Naydan DK, Moore PF (1997) Characterization of the cutaneous inflammatory infiltrate in canine atopic dermatitis. *Am J Dermatopathol* 19:477–486.
- Olivry T (2010) New diagnostic criteria for canine atopic dermatitis. *Vet Dermatol* 21:123–126.
- O'Regan GM, Sandilands A, McLean WH, Irvine AD (2009) Filaggrin in atopic dermatitis. *J Allergy Clin Immunol* 124:R2–R6.
- Palmer CN, Irvine AD, Terron-Kwiatkowski A, et al (2006) Common loss-of-function variants of the epidermal barrier protein filaggrin are a major predisposing factor for atopic dermatitis. *Nat Genet* 38:441–446.
- Pfaffl MW (2001) A new mathematical model for relative quantification in real-time RT-PCR. *Nucleic Acids Res* 29:e45.
- Pfaffl MW, Horgan GW, Dempfle L (2002) Relative expression software tool (REST) for group-wise comparison and statistical analysis of relative expression results in real-time PCR. *Nucleic Acids Res* 30:e36.

- Pratt JM, Petty J, Riba-Garcia I, Robertson DH, Gaskell SJ, Oliver SG, Beynon RJ (2002) Dynamics of protein turnover, a missing dimension in proteomics. *Mol Cell Proteomics* 1:579-591.
- Proksch E, Brandner JM, Jensen JM (2008) The skin: an indispensable barrier. *Exp Dermatol* 17:1063-1072.
- Proksch E, Fölster-Holst R, Bräutigam M, Sepehrmanesh M, Pfeiffer S, Jensen JM (2009) Role of the epidermal barrier in atopic dermatitis. *J Dtsch Dermatol Ges* 7:899-910.
- Proksch E, Fölster-Holst R, Jensen JM (2006) Skin barrier function, epidermal proliferation and differentiation in eczema. *J Dermatol Sci* 43:159-169.
- Qian J, Kluger Y, Yu H, Gerstein M (2003) Identification and correction of spurious spatial correlations in microarray data. *Biotechniques* 35:42-44.
- Rothe MJ, Grant-Kels JM (1996) Atopic dermatitis: an update. *J Am Acad Dermatol* 35:1-13.
- Sandilands A, Sutherland C, Irvine AD, McLean WH (2009) Filaggrin in the frontline: role in skin barrier function and disease. *J Cell Sci* 122:1285–1294.
- Sandilands A, Terron-Kwiatkowski A, Hull PR, et al (2007) Comprehensive analysis of the gene encoding filaggrin uncovers prevalent and rare mutations in ichthyosis vulgaris and atopic eczema. *Nat Genet* 39:650–654.
- Sapuntsova SG, Mel'nikova NP, Deigin VI, Kozulin EA, Timoshin SS (2002) Proliferative processes in the epidermis of patients with atopic dermatitis treated with thymodepressin. *Bull Exp Biol Med* 133:488-490.

- Scholzen T, Gerdes J (2000) The Ki-67 protein: from the known and the unknown. *J Cell Physiol* 182:311–322.
- Scott DW, Miller WH, Griffin CE (2001) Skin immune system and allergic skin diseases. In: Muller & Kirk's small animal dermatology. 6th Ed. GH Muller, RW Kirk, DW Scott, CE Griffin (ed.). Philadelphia: Saunders. 543-666.
- Seguchi T, Cui CY, Kusuda S, et al (1996) Decreased expression of filaggrin in atopic skin. *Arch Dermatol Res* 288:442–446.
- Shimada K, Yoon JS, Yoshihara T, Iwasaki T, Nishifuji K (2009) Increased transepidermal water loss and decreased ceramide content in lesional and non-lesional skin of dogs with atopic dermatitis. *Vet Dermatol* 20:541-546.
- Steinert PM, Marekov LN (1997) Direct evidence that involucrin is a major early isopeptide cross-linked component of the keratinocyte cornified cell envelope. *J Biol Chem* 272:2021-2030.
- Strömberg S, Björklund MG, Asplund C, Sköllermo A, Persson A, Wester K, Kampf C, Nilsson P, Andersson A-C, Uhlen M, Kononen J, Ponten F, Asplund A (2007) A high-throughput strategy for protein profiling in cell microarrays using automated image analysis. *Proteomics* 7:2142–2150.
- Sukjumlong S, Dalin AM, Sahlin L, Persson E. (2005) Immunohistochemical studies on the progesterone receptor (PR) in the sow uterus during the oestrous cycle and in inseminated sows at oestrus and early pregnancy. *Reproduction*. 129:349-359.
- Szallasi Z (1999) Genetic network analysis in light of massively parallel biological data acquisition. *Pac Symp Biocomput* 5-16.

- Van Neste D, Lachapelle JM, Desmons F (1979) Atopic dermatitis: A histologic and radioautographic study (after 3H-Thymidine Labelling) of epidermal and dermal lesions. *Ann Dermatol Venereol* 106:327–335.
- Vickery BP (2007) Skin barrier function in atopic dermatitis. *Curr Opin Pediatr* 19:89–93.
- Walley AJ, Chavanas S, Moffatt MF, et al (2001) Gene polymorphism in Netherton and common atopic disease. *Nat Genet* 29:175–178.
- Watt FM (1983) Involucrin and other markers of keratinocyte terminal differentiation. *J Invest Dermatol* 81:100S–103S.
- Wertz PW, Downing DT (1986) Covalent attachment of omega-hydroxyacid derivatives to epidermal macromolecules: A preliminary characterization. *Biochem Biophys Res Commun* 137:992–997.
- Wertz PW, Swartzendruber DC, Kitko DJ, Madison KC, Downing DT (1989) The role of the corneocyte lipid envelopes in cohesion of the stratum corneum. *J Invest Dermatol* 93:169–172.
- Willemsse T (1988) Comparative aspects of canine and human atopic dermatitis. *Semin Vet Med Surg (Small Anim)* 3:255.
- Wood SH, Clements DN, McEwan NA, Nuttall T, Carter SD (2008) Reference genes for canine skin when using quantitative real-time PCR. *Vet Immunol Immunopathol* 126:392–395.

Yager YA, Wilcock, BP (1994) Part II Inflammatory and degenerative lesion of the skin classified by pattern. In: Color Atlas and Text of Surgical Pathology of the Dog and Cat: Dermatopathology and Skin Tumors. St. Louis: Mosby-Year book.51-139.