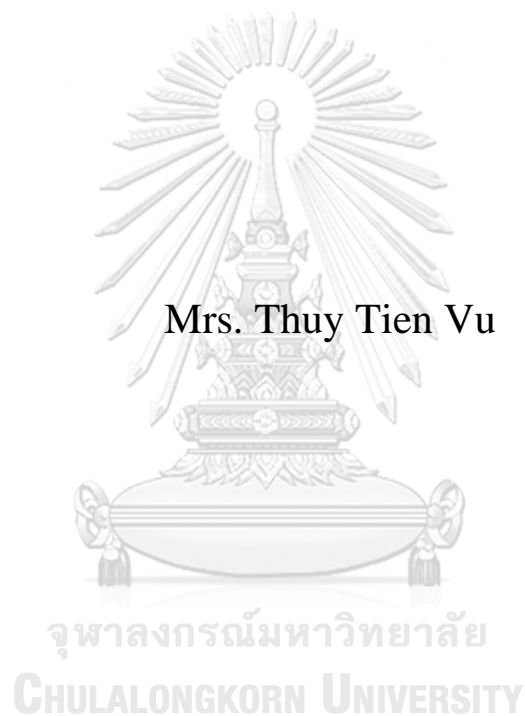


COMPARATIVE EVALUATION OF MINERAL TRIOXIDE
AGGREGATE AND ACEMANNAM FOR PARTIAL PULPO
TOMY IN PERMANENT TEETH WITH INCOMPLETE ROO
T FORMATION



A Dissertation Submitted in Partial Fulfillment of the Requirements
for the Degree of Doctor of Philosophy in Dental Biomaterials Science
Inter-Department of Dental Biomaterials Science
GRADUATE SCHOOL
Chulalongkorn University
Academic Year 2020
Copyright of Chulalongkorn University

การประเมินเปรียบเทียบผลของสารมิเนอร์ลัทรอกไกไซด์และอะซี
แมนแนนในพื้้นแท้ที่ตัดเนื้อเยื่อโพรงประสาทฟันบางส่วน



วิทยานิพนธ์นี้เป็นส่วนหนึ่งของการศึกษาตามหลักสูตรปริญญาวิทยาศาสตรดุษฎีบัณฑิต
สาขาวิชาทันตชีววัสดุศาสตร์ สหสาขาวิชาทันตชีววัสดุศาสตร์
บัณฑิตวิทยาลัย จุฬาลงกรณ์มหาวิทยาลัย
ปีการศึกษา 2563
ลิขสิทธิ์ของจุฬาลงกรณ์มหาวิทยาลัย

ทรี เทียน วู :

การประเมินเปรียบเทียบผลของสารมิเนอรัลไตรออกไซด์และอะซีแมนแนนในฟันแท้ที่ตัดเนื้อเยื่อโพรงประสาทฟันบางส่วน. (

COMPARATIVE EVALUATION OF MINERAL TRIOXIDE AGGREGATE AND ACEMANNAM FOR PARTIAL PULPOTOMY IN PERMANENT TEETH WITH INCOMPLETE ROOT FORMATION)

อ.ที่ปรึกษาหลัก : พสุธา รัญญะกิจไพศาล

-มิเนอรัลไตรออกไซด์ (เอ็มทีเอ) เป็นวัสดุทันตกรรมที่แนะนำให้ใช้ปิดรอยทะเลโพรงประสาทฟัน แต่วัสดุมีข้อด้อยคือระยะเวลาการแข็งตัวที่นานและราคาสูง อะซีแมนแนนคือสารสกัดพอลิแซคคาไรด์จากวานหางจรเข้ที่มีประสิทธิภาพในการคงความมีชีวิตของฟันและการกระตุ้นการสร้างเนื้อฟันทั้งในระดับสัตว์ทดลองและการศึกษาทางคลินิกในฟันน้ำนม ในการศึกษาครั้งนี้ มีวัตถุประสงค์เปรียบเทียบประสิทธิภาพของวัสดุเอ็มทีเอและกอนซ์อะซีแมนแนนต่อการคงความมีชีวิตของฟันแท้ที่การสร้างรากยังไม่สมบูรณ์ด้วยการรักษาแบบตัดเนื้อเยื่อโพรงประสาทฟันบางส่วน โดยอาสาสมัครที่มีฟันแท้ที่การสร้างรากยังไม่สมบูรณ์มีรอยทะเลโพรงประสาทฟันจาก การผุหรืออุบัติเหตุ และได้รับการวินิจฉัยว่ามีการอักเสบของเนื้อเยื่อโพรงประสาทฟันแบบผันกลับได้เข้าร่วมโครงการ โดยฟันตัวอย่างจะถูกแบ่งเป็น 2 กลุ่มเท่าๆ กัน คือ กลุ่มที่ปิดรอยทะเลโพรงฟันด้วยสารเอ็มทีเอ หรือ กอนซ์อะซีแมนแนน (n=25) ภายหลังจากการปิดรอยทะเลโพรงฟันจะรองพื้นคาร์ดีด้วยวัสดุกลาสไอโอโนเมอร์ซีเมนต์และบูรณะด้วยวัสดุคอมโพสิตที่แข็งตัวด้วยแสง อาสาสมัครจะได้รับการประเมินทางคลินิกและการถ่ายภาพรังสีซีบีซีที่ทันทีหลังการรักษา (baseline) หลังการรักษาที่ระยะ 6 และ 12 เดือน ข้อมูลจากภาพถ่ายรังสีจะถูกนำมาสร้างภาพเสมือนในเชิงสามมิติ เปรียบเทียบความยาวรากและพื้นที่ปลายรากก่อนและหลังการรักษา และประเมินวิเคระห์ ผลการศึกษาพบร้อยละความสำเร็จในการรักษาของกลุ่มอะซีแมนแนนและเอ็มทีเอที่ระยะเวลา 1 ปี คือ 90.91 และ 95.65 ตามลำดับ ($p>0.05$) ฟันคงความมีชีวิตและมีการสร้างรากอย่างต่อเนื่องเมื่อประเมินจากความยาวรากที่เพิ่มขึ้นและพื้นที่ปลายรากที่ลดลงเปรียบเทียบกับความยาวรากและพื้นที่ปลายรากก่อนการรักษา อย่างมีนัยสำคัญทางสถิติ ($p<0.05$) จากผลการศึกษาสนับสนุนประสิทธิภาพของสารอะซีแมนแนนเพื่อเป็นชีววัสดุปิดรอยทะเลโพรงฟันทางเลือกในการคงความมีชีวิตของฟันแท้ที่รักษาแบบตัดเนื้อเยื่อโพรงประสาทฟันบางส่วน และประโยชน์ในการใช้โปรแกรมสร้างภาพเชิงสามมิติเพื่อเปรียบเทียบและประเมินผลการรักษา

สาขาวิชา ทันตชีววัสดุศาสตร์

ลายมือชื่อนิสิต

ปีการศึกษา 2563

ลายมือชื่อ อ.ที่ปรึกษาหลัก

ษา

5787845420 : MAJOR DENTAL BIOMATERIALS SCIENCE

KEYWORD apexogenesis, acemannan, mineral trioxide aggregate, vital pulp therapy, 3D analysis

D: Thuy Tien Vu :
 COMPARATIVE EVALUATION OF MINERAL TRIOXIDE AGGREGATE AND ACEMANNAM FOR PARTIAL PULPOTOMY IN PERMANENT TEETH WITH INCOMPLETE ROOT FORMATION. Advisor: Professor Pasutha Thunyakitpisal, D.D.S., Ph.D.

Mineral trioxide aggregate (MTA), the standard pulp capping material, has disadvantages, including long setting time and high cost. Along this line, *acemannan*, a polysaccharide extracted from aloe vera, would be a promising biomaterial for vital pulp therapy as it is shown to induce mineralized bridge formation in animal and clinical studies. In this study, the impact of MTA and acemannan sponges on partial pulpotomized permanent teeth has been evaluated. For the research design, fifty immature permanent teeth with caries or accident-induced pulp exposure were collected and assessed. After partial pulpotomy, the teeth were randomly allocated into the treatment group using either acemannan or the MTA group (n = 25). To conduct the study, the patients were examined immediately right after the treatment (baseline) and a follow-up period of 6- and 12-months post-surgery for clinical and Cone beam computed tomography (CBCT) examinations. We also designed and conducted the three-dimensional (3D) analysis to evaluate the apexogenesis impact of the two materials (MTA and acemannan) on the partial pulpotomy treatment, typically for the cases of immature permanent teeth. The evaluation results show that the overall success rate in the acemannan and MTA groups from baseline to 12-month follow-up was 90.91% and 95.65%, respectively, with no significant difference between the two groups when $p > 0.05$. In the success samples in both groups, the root length is increased and the apex size is decreased significantly ($p < 0.05$), indicating the continued root formation. The study then suggests that acemannan is a promising and beneficial alternative pulp capping material with low-cost for partial pulpotomy treatment for immature permanent teeth dedicated to vital pulp therapy in which we utilize the 3D-superimposition and apical foramen area as the novel reliable tools for the evaluations and analyses.

Field of Study:	Dental Biomaterials Science	Student's Signature
Academic Year:	2020	Advisor's Signature

ACKNOWLEDGEMENTS

I would like to send my gratitude to the 90th Anniversary of Chulalongkorn University Fund (Ratchadaphiseksomphot Endowment Fund), Chulalongkorn University (Government Budget), and 100th Anniversary Chulalongkorn University Fund for support fund for this research.

My deepest thanks to Prof. Pasutha Thunyakitpisal, my advisor, who provided his constant support at all times. I will be forever thankful for his mentorship, constant support, and helpful counsel. I would like to express my gratitude and appreciation to Assistant Professor Dujreutai Pongkao Kashima, Professor Chutima Trairatvorakul, Assistant Professor Pisha Pittayapa and Professor Sittichai Koontongkaew for their valuable support and suggestion for this research. With all my gratitude and heartfelt thanks to all the lecturers, staffs and friends of Dental Biomaterials Science Program for their friendship and support during my study in Thailand.

I would like to send my sincere thanks to Prof. Trinh Dinh Hai and Assoc. Prof. Tran Cao Binh and my hospital – Hanoi National Hospital of Odonto Stomatology, Vietnam for their endless support.

My deepest thank is for my beloved husband Nguyen Truong Minh, for his love, understanding and supporting my career. At last but not the least, I will never forget endless love and and kindness of my family.

I would like to dedicate this thesis to those mentioned who are all behind my success.

Thuy Tien Vu

TABLE OF CONTENTS

	Page
ABSTRACT (THAI)	iii
ABSTRACT (ENGLISH).....	iv
ACKNOWLEDGEMENTS.....	v
TABLE OF CONTENTS.....	vi
CHAPTER 1	1
INTRODUCTION	1
1.1 Background and Rationale	1
1.2 Research questions	3
1.3 Research objectives	3
1.4 Research hypothesis	3
CHAPTER II.....	4
LITERATURE REVIEW	4
2.1 Dental pulp.....	4
2.1.1 The living pulp	4
2.1.2 Pulp reaction to caries	5
2.1.3 Correlation between clinical symptoms and actual pulp inflammation	6
2.1.4 Pulp reactions to restorative materials.....	8
2.1.5 Pulp capping with capping material	10
2.2 Radiographic examination and interpretation.....	12
2.2.1 Intraoral radiographs	12
2.2.2 Cone-beam computerized tomography	13
2.3. Vital Pulp therapy	19
2.3.1 Indications for vital pulp therapy	19
2.3.2 Procedures generating mineralized tissue barriers	23
2.3.2.1 Indirect pulp capping.....	23

2.3.2.2 Direct pulp capping	24
2.3.2.3 Partial pulpotomy	25
2.3.2.4 Cervical (full) pulpotomy	27
2.3.3 Materials for vital pulp therapy	28
2.3.3.1 Aqueous calcium hydroxide suspensions	29
2.3.3.2 Hard setting calcium hydroxide cements	30
2.3.3.3 Mineral trioxide aggregate	30
2.3.3.4 Calcium silicate cements(CSCs)	33
2.3.3.5 Acemannan	36
CHAPTER 3	38
MATERIALS AND METHODS	38
3.1 Study design and ethical statement	38
3.2 Sample size	38
3.3 Inclusion and exclusion criteria	39
3.4 Study population	40
3.5 Randomization	41
3.6 Blinding	41
3.7 Acemannan sponge preparation	41
3.8 Intervention.....	43
3.8.1 Clinical procedure	43
3.8.2 Follow-up	44
3.8.3 3D tooth reconstruction, and analysis	45
3.9 Outcomes	47
3.10 Statistical methods	49
CHAPTER IV	51
RESULT	51
4.1 Demographic characteristics	51
4.2 Evaluation of treatment result	54
CHAPTER V	65

DISCUSSION.....	65
CHAPTER VI.....	72
CONCLUSION.....	72
REFERENCES	75
VITA.....	104



จุฬาลงกรณ์มหาวิทยาลัย
CHULALONGKORN UNIVERSITY

CHAPTER 1

INTRODUCTION

1.1 Background and Rationale

The dental pulp contains immune cells that allow it to respond against offending irritants. The pulp also contains odontoblasts, which are specialized to form dentin. In the absence of a vital pulp, the tooth structure is susceptible to infection, and dentin deposition is arrested.¹ Therefore, whenever the pulp tissue is pathologically affected by caries, traumatic injury, or other causes, it is desirable to attempt to maintain the integrity and vitality of the pulp by vital pulp therapies. Especially in young permanent teeth with immature roots, maintenance of healthy pulp is integral to continue apexogenesis.

Apexogenesis is the special goal for treatment of pulp exposure cases with open apices. This is a histological term used to describe the continued physiologic development and formation of the root's apex. Formation of the root apex can be accomplished by implementing the appropriate vital pulp therapy. There are a number of methods that can be used, such as indirect pulp capping, direct pulp capping, partial pulpotomy and full pulpotomy.²

Extensive caries and trauma cases which lead to pulp exposure are indications for partial pulpotomy. Due to expansive bacterial invasion, the pulp is pathologic but still vital, with no loss of vascularity. If the lesion is not treated appropriately, it will cause pulp inflammation and irreversible pulpitis, followed by pulp necrosis. This

arrests normal development of the root, which results in a short-length root with a thin dentin wall. As a result, the teeth are substantially prone to fracture and interfere with endodontic procedure due to the open apex and funnel-shaped canal. To prevent these sequela, partial pulpotomy is performed on the teeth to preserve the pulp's health, after which the physiologic continued root development is encouraged, which leads to apical closure and strengthening of the root structure. In order to achieve this goal, partial pulpotomy needs a critical step-by-step procedure and an ideal pulp capping material.

Recently, Mineral trioxide aggregate (MTA) have been widely used in partial pulpotomy procedure as capping agents. However, this material still possesses some disadvantages such as difficult handling, high cost and other drawbacks. Meanwhile, acemannan, a natural product derived from *Aloe vera* has been reported to induce pulp healing and dentine formation. *Aloe vera* is the common name for *Aloe barbadensis*, the most well-known species of *Aloe* because of its widespread use as a medicinal herb for a long time. It contains many necessary ingredients such as vitamins, amino acids, enzymes and polysaccharides; therefore it has been used to make various medical and cosmetic products³. Acemannan has been shown capability in not only soft but also hard tissue healing⁴. Acemannan stimulates dentin matrix protein expression, growth factor secretion, and mineralization by dental pulp cells⁵. *In vivo*, acemannan induced pulp healing and reparative dentin formation in Lipopolysaccharide-induced reversible pulpitis in canine teeth and caries exposed reversible pulpitis in human primary teeth⁶. Similar to the MTA treatment, the use of acemannan resulted in histological evidence of mineralized bridge formation with normal underlying pulp tissue without enduring inflammation or pulp necrosis⁵. In addition, acemannan functions as a 3D scaffold to enhance the blood clot formation⁶. The neighboring odontoblasts, pulpal fibroblasts,

and progenitor stem cells in the pulp migrate to the scaffold and generate dentin formation. Acemannan is promising material that could be a biological and economic alternative to MTA in partial pulpotomy procedure.

Hence, in this study, we compare the effect of acemannan with MTA in partial pulpotomy in immature permanent teeth.

1.2 Research questions

- Is acemannan an effective capping material in treatment of immature permanent teeth with pulp exposure?
- Is there any difference in effectiveness of acemannan and MTA in treatment of immature permanent teeth with pulp exposure?

1.3 Research objectives

- To evaluate the effectiveness of acemannan as capping material after partial pulpotomy in immature permanent teeth.
- To compare the success rate of acemannan and MTA after partial pulpotomy in immature permanent teeth.

1.4 Research hypothesis

- Acemannan is an effective capping material in treatment of immature permanent teeth with pulp exposure.
- There is no difference in effectiveness of acemannan and MTA in treatment of immature permanent teeth with pulp exposure.

CHAPTER II

LITERATURE REVIEW

2.1 Dental pulp

2.1.1 *The living pulp*

Vital pulp tissue comprises cells including fibroblasts, undifferentiated mesenchymal cells, odontoblasts, macrophages, dendritic cells, and other immunocompetent cells. Odontoblasts form the mineralized predentin-dentin matrix, which includes phosphoproteins, glycoproteins, proteoglycans, and sialoproteins. Repair mechanisms in the pulp are similar to those in normal connective tissue injured by trauma. When the enamel and dentin are challenged and the pulp is exposed to advancing microorganisms, inflammatory changes can induce pulp necrosis, which precedes problems including infection and its complications.^{7,8} The pulp undergoes physiologic, pathologic, and defensive changes during its life.⁹⁻¹¹ These include continued dentin apposition, causing gradual narrowing of the circumference of coronal pulp volume and canal lumen dimensions.¹² Atrophy results in fibrosis, dystrophic calcification, degeneration of odontoblasts, and increased cellular apoptosis.¹³ Aging of human pulp cells is primarily characterized by the formation of reactive oxygen species and senescence-related beta (β)-galactosidase activity.¹⁴ Pain sensitivity is reduced due to a decrease in fast-conducting A delta fibers and diminished pulp repair, partly attributed to decreases in the levels of substances such as alkaline phosphatase.^{15,16} A comparison analysis of gene expression levels reflecting cell function, proliferation, differentiation, and development found them markedly higher in young pulps.¹¹ Young dental pulps show greater cell and tissue differentiation, proliferation, and development

of the lymphatic, hematologic, and immune systems compared to older pulps where the apoptosis pathway is highly expressed.

In summary, the main functions of the dental pulp include dentin formation during development and life of the tooth, the transmission of stimuli via proprio- and pain receptors, and immune responses. The pulp also produces reparative dentin as a defense mechanism against external stimuli, and tissue during the formation and closure of the root apex.

2.1.2 Pulp reaction to caries

When dental caries is left untreated, it will cause pulp necrosis and then tooth loss later. Both bacterial by-products and products from the dissolution of the organic and inorganic constituents of dentin mediate the effects of dental caries on the pulp. When the pulp is exposed, bacterial metabolites, toxins, and cell wall components induce inflammation. Three basic reactions tend to protect the pulp against caries: (1) decreases in dentin permeability due to dentin sclerosis, (2) tertiary dentin formation, and (3) inflammatory and immune reactions in the pulp.¹⁷

While dentin can provide a physical barrier against noxious stimuli, the pulp immune response provides humoral and cellular response to invading pathogens. The early inflammatory response to caries is characterized by the focal accumulation of chronic inflammatory cells. This is mediated initially by odontoblasts and later by dendritic cells. As the most peripheral cell in the pulp, the odontoblast is positioned to encounter foreign antigens first and initiate the innate immune response. Once the odontoblast is stimulated by a pathogen, proinflammatory cytokines, chemokines, and

antimicrobial peptides are elaborated by the odontoblast resulting in recruitment and stimulation of immune effector cells as well as direct bacterial killing.¹⁸

As the carious lesion progresses, the density of the chronic inflammatory infiltrate and well as that of dendritic cells in the odontoblast region increases. Pulp dendritic cells are responsible for antigen presentation and stimulation of T lymphocytes. In the uninfamed pulp, they are scattered throughout the pulp. With caries progression, they aggregate initially in the pulp and subodontoblastic regions then extend into the odontoblast layer and eventually migrate into the entrance to tubules beside the odontoblast process.¹⁹ Evidence suggests that odontoblasts also play a role in the humoral immune response to caries. IgG, IgM, and IgA have been localized in the cytoplasm and cell processes of odontoblasts in human carious dentin.²⁰ In summary, it appears that the odontoblasts play a central role in orchestrating local and chemotactic inflammatory responses to dental caries.

Pulp exposure in primary and immature permanent teeth can lead to a proliferative response or hyperplastic pulpitis. Exuberant inflammatory tissue proliferates through the exposure and forms a “pulp polyp”. It is presumed that a rich blood supply facilitates this proliferative response. Conventional root canal therapy or pulpotomy would be indicated in these cases.

2.1.3 Correlation between clinical symptoms and actual pulp inflammation

From a clinical perspective, it would be most helpful to the clinician to be able to diagnose pulp conditions from symptoms with which a patient presents. If symptoms are not conclusive, a number of objective tests should aid the clinician in reaching a definitive diagnosis of the pulp pathological status. In actuality, such combinations of

subjective and objective findings are frequently insufficient in reaching definitive diagnosis of the status of the dental pulp. This is particularly true in cases of vital inflamed pulp, where it is difficult for the practitioner to determine clinically whether the inflammation is reversible or irreversible. Many practitioners rely on painful symptoms to determine the status of the pulp. Several studies have examined this question in some detail. Some studies showed that in the vital pulp, clinical symptoms generally did not correlate with histopathological findings.²¹⁻²³ Furthermore, carious pulp exposure was associated with severe inflammatory response or necrosis, regardless of symptoms. It was common to find cases with evidence of severe inflammatory responses including partial necrosis histologically, but with little or no clinical symptoms.²¹⁻²⁴ In addition, the incidence of nerve fibers,²⁵ and the vascularity²⁶ in inflamed pulp does not coordinate with clinical symptoms in primary and permanent teeth. It has been reported that the incidence of painless pulpitis that leads to pulp necrosis and asymptomatic apical periodontitis is about 40% to 60% of all pulpitis cases.²⁷ More recently, clinical and histopathological findings in a study showed that the correspondence of the clinical and histologic diagnosis of normal pulp/reversible pulpitis and irreversible pulpitis were 96.6% and 84.4%, respectively.²⁸

Objective clinical findings are essential for determining the vitality of the pulp and whether the inflammation has extended into the periapical tissues. Lack of response to electric pulp testing is generally indicative that the pulp has become necrotic.²³ Thermal pulp testing is valuable in reproducing a symptom of thermal sensitivity, and in allowing the practitioner to assess the reaction of the patient to a stimulus and the duration of the response. However, pulp testing cannot determine the degree of pulp inflammation.^{23,24} These studies show that irreversible pulp inflammation can be

diagnosed with some certainty only in cases where, in addition to being responsive to pulp testing, the pulp develops severe spontaneous symptoms. Pulp necrosis could be predictably diagnosed by a consistent negative response to pulp tests, preferably to both cold and electrical tests to avoid false responses.^{29,30} Recent studies show the accuracy of traditional pulp testing to be about 82% to 84%.³¹

The lack of correlation between the histological status of the pulp and clinical symptoms may be explained by recent advances in the science of pulp biology. In the last few decades, studies have shown that numerous molecular mediators may act in synchrony to initiate, promote, and/or modulate the inflammatory response in the dental pulp. Many of these molecular mediators tend to reduce the pain threshold, either directly by acting on peripheral nerve cells or through promoting the inflammatory process. Thus a number of these mediators were shown to be elevated in human pulp diagnosed with painful pulpitis. These mediators include prostaglandins,³² the vasoactive amine bradykinin,³³ tumor necrosis factor alpha,³⁴ neuropeptides such as SP,³⁵ CGRP and neurokinin A,³⁶ and catecholamines.³⁷ In fact, it was even shown that when patients have painful pulpitis, the crevicular fluid related to the affected teeth has significantly increased neuropeptides compared to the levels in contralateral teeth.³⁶ Studies in both animal and clinical models suggest that opioids exert their analgesic effects not only through activation of receptors in the CNS but also through interaction with peripheral opioid receptors. These receptors are suggested to be present in the human dental pulp,³⁸ and these could play a role in helping us understand why many cases with irreversible pulpitis are asymptomatic.

2.1.4 Pulp reactions to restorative materials

The effects of restorative materials on the dental pulp have been investigated and seem to relate directly to the permeability of the associated dentin. The degree of dentin permeability is governed by several factors, including age and caries status. The permeability (hydraulic conductance) of old normal dentin was only 20% of that obtained in young normal dentin. Young carious dentin was only 14% as permeable as young normal dentin.³⁹ The most important variable in dentin permeability to restorative materials is the cavity remaining dentin thickness.⁴⁰

Although pulp irritation is largely considered to be a negative sequela, the irritant potential of certain restorative materials is central to their usefulness in restorative dentistry. Calcium hydroxide (CH) is one of the oldest and most widely used medicaments for stimulation of dentinal bridge formation subsequent to microscopic or gross pulp exposure. The low-grade pulp irritation that it induces is important for dentinal bridge formation in exposures.^{41,42} The degree of inflammation is dependent on the preparation of calcium hydroxide used. Aqueous suspensions of calcium hydroxide applied to exposed pulps cause superficial necrosis of pulp tissue followed by low-grade inflammatory changes. Within 30 days, the tissue subjacent to the necrotic zone has reorganized and resumed normal architecture. Hard setting calcium hydroxide preparations as well as mineral trioxide aggregates (MTA) are effective in eliciting dentinal bridge formation with a much smaller to nonexistent necrotic zone.⁴³ This is preferable in vital pulp therapies such as the Cvek pulpotomy where maintenance of the maximum amount of vital pulp tissue is desirable and the extent of pulp inflammation is minimal.⁴⁴ Application of calcium hydroxide to intact dentin appears to induce sclerosis by promoting crystal precipitation within the tubules accompanied by reductions in permeability.⁴⁵ However, more recent findings show that calcium

hydroxide over intact dentin does not exert a significant clinical advantage and may be lost due to the action of leakage or dentinal fluid.⁴⁶

While the irritation potential of calcium hydroxide plays a role in its effectiveness, the high pH of this material can act to release bioactive molecules from dentin. Dentin matrix proteins like TGF- β 1 and adrenomedullin, which potentially influence cellular events for dentine repair and regeneration, are released by both calcium hydroxide and MTA.^{47,48} Once liberated, they are able to facilitate hard tissue formation yet again. This offers another explanation for the ability of these materials to induce hard tissue formation *in vivo*.

Findings about the influences of glass ionomer materials have shown that both the lowered pH of the material and the high quantities of released fluoride have cytotoxic effects on dental pulp cells.⁴⁹ The material is more irritating to pulp tissue than calcium hydroxide, which suggests that it is not an appropriate dental material to be used in direct pulp capping for mechanically exposed human pulps.⁵⁰ When applied in deep cavities and in the absence of bacteria, there is a transient inflammatory response and reparative dentin is formed.⁵¹

2.1.5 Pulp capping with capping material

Capping of pulp exposures is indicated in pulps that were previously healthy and exposed by trauma or dental restorative procedures and, more recently, for pulp exposure where the diagnosis is reversible pulpitis.^{52,53} This is particularly true in the cariously exposed immature permanent tooth, where maintenance of pulp vitality is crucial to further tooth development. Although calcium hydroxide has historically been the preferred dressing agent on mechanically exposed pulps, the use of MTA,

Biodentine, and other bioceramic formulations has recently been proposed, even on carious pulp exposures.⁵⁴⁻⁵⁶ Prospective animal studies and human case reports have evaluated the ability of MTA to allow for the formation of a reparative dentin bridge and to maintain continued pulp vitality.^{57,58} Although the results are generally favorable, one concern is of tooth discoloration in cases where the gray MTA formulation is used on anterior teeth. Recent studies have indicated that newer bioceramic materials show less potential for discoloration when used as pulp capping materials.⁵⁹ The bioceramic that has been most intensely studied for pulp capping is MTA. In one clinical study, MTA was used as a pulp capping material for carious pulp exposures.⁶⁰ Forty patients aged 7 to 45 years accepted pulp-capping treatment when they received a diagnosis of reversible pulpitis after undergoing cold testing and radiographic examination. A caries detector dye was used during caries removal. Sodium hypochlorite solution was used for hemostasis and MTA was placed over the exposures and all surrounding dentin. During a second visit, the operator restored the teeth with bonded composite after sensibility testing and confirmed MTA curing. Over an observation period of nine years, 97.96% had favorable outcomes on the basis of radiographic appearance, subjective symptoms and cold testing. All teeth in younger patients that initially had open apices showed completed root formation (apexogenesis). In another clinical study in which dentists and students participated in the treatment, pulp capping of carious pulp exposures was compared between MTA and calcium hydroxide. 122 treated teeth were available for follow-up. A successful outcome was recorded for 78% of teeth (54 of 69) in the MTA group and for 60% of teeth (32 of 53) in the the calcium hydroxide group, which concluded that MTA appears to be more effective than calcium hydroxide for maintaining long-term pulp vitality

after pulp capping.⁵⁶ Randomized trials and consensus reports have shown that tricalcium silicates are significantly better than calcium hydroxide as pulp capping agents in carious pulp exposure.^{61,62}

2.2 Radiographic examination and interpretation

2.2.1 Intraoral radiographs

The radiographic interpretation of a potential endodontic pathosis is an integral part of endodontic diagnosis and prognosis assessment. However, the image should be used only as one sign, providing important clues in the diagnostic investigation. Because treatment planning will ultimately be based on the diagnosis, the potential for inappropriate treatment may frequently exist if the radiograph alone is used for making final diagnosis.

The radiographic appearance of endodontic pathosis can sometimes be highly subjective. Moreover, standard two-dimensional radiography, clinicians basically project radiation through an object and capture the image on a recording medium, either x-ray film or a digital sensor. Thus, the three-dimensional interpretation of the resulting two-dimensional image requires not only knowledge of normality and pathosis but also advanced knowledge of how the radiograph was exposed. Changes in the horizontal or vertical angulation may help elucidate valuable anatomic and pathologic information; it also has the potential to hide important information. An incorrect vertical angulation may cause the buccal roots of a maxillary molar to be masked by the zygomatic arch. An incorrect horizontal angulation may cause roots to overlap with the roots of adjacent teeth, or it may incorrectly create the appearance of a one-rooted tooth, when two roots are actually present.

In general, when endodontic pathosis appears radiographically, it appears as a radiolucency in the area of the periapex. The pathosis may present merely as a widening or break in the lamina dura-the most consistent radiographic finding when a tooth is nonvital⁶³- or it may present as a radiolucent area at the apex of the root or in the alveolar bone adjacent to the exit of a lateral or furcation accessory canal. On occasion no radiographic change can be seen at all, even in the presence of a disease process in the alveolar bone. This is mainly due to the fact that the disease process did not reach the cortical plate of the bone. Two-dimensional dental radiography has two basic shortcomings: the lack of early detection of pathosis in the cancellous bone, because of the density of the cortical plates, and the influence of the superimposition of anatomic structures. Variability in the radiographic expression of an osseous pathosis has much to do with the relative location of the root of the tooth and how it is oriented with respect to the cortical and cancellous bone. Radiographic changes from bone loss will not be detected if the loss is only in cancellous bone.⁶⁴ However, the radiographic evidence of pathosis will be observed once this bone loss extends to the junction of the cortical and cancellous bone. In addition, certain teeth are more prone to exhibit radiographic changes than others, depending on their anatomic location.⁶⁵

Many factors can influence the quality of the radiographic interpretation, including the ability of the person exposing the radiograph, the quality of the radiographic film, the quality of the exposure source, the quality of the film processing, and the skill with which the film is viewed. Controlling all of these variables can be a difficult challenge but is paramount for obtaining an accurate radiographic interpretation.

2.2.2 Cone-beam computerized tomography

Limitations in conventional two-dimensional radiography promulgated a need for three-dimensional imaging, known as cone-beam computerized tomography (CBCT). Most of these machines are similar to a dental panoramic radiographic device, whereby the patient stands or sits as a cone-shaped radiographic beam is directed to the target area with a reciprocating capturing sensor on the opposite side. The resulting information is digitally reconstructed and interpreted to create an interface whereby the clinician can three-dimensionally interpret “slices” of the patient’s tissues in a multitude of planes.^{66,67} The survey of the scans can be interpreted immediately after the scan. Various software applications have been used to enable the images to be sent to other clinicians. This is accomplished either in printed format or with portable and transferable software that can be used interactively by another clinician.

Principles of cone beam computed tomography

Two important parameters of cone beam imaging are described in the following sections:

- Voxel size
- Field of view (FOV)

Voxels and voxel sizes

Voxels are cuboidal elements that constitute a 3D volume, unlike pixels, which are 2D. Data are acquired and represented in three dimensions using voxels. Unlike with medical computerized tomography, typically used in medicine, cone beam units acquire x-ray information using low kV and low mA exposure parameters in a single pass from

180 to 360 degrees of rotation around the anatomy of interest. Medical scanners use higher voltages of 120 kV or more and a current of about 400 mA.

CBCT data have a much higher resolution than medical CT data for hard tissue visualization because of the smaller voxel sizes that medical-grade scanners are incapable of achieving at a significantly lower dose.

Field of view

The FOV ranges from as small as a portion of a dental arch to an area as large as the entire head. The selection of the FOV depends on several factors. Among the most important are the following:

- Diagnostic task
- Type of patient
- Spatial resolution requirements

Diagnostic task

The diagnostic task is the single most important determinant of the FOV in any imaging study. If systemic conditions or generalized disorders are suspected, a larger FOV is sometimes required. For most endodontic purposes, a limited FOV can be used if no signs or symptoms of systemic conditions are reported or noted. Under no circumstances should a screening study be done using a large FOV in the absence of signs and symptoms justifying the procedure. Image quality has a direct impact on the diagnostic outcome; therefore, the choice of a FOV should be made carefully.

Spatial resolution requirements

All endodontic imaging procedures require high spatial resolution. If CBCT is used, the data acquisition should be performed at the smallest voxel size: the smaller the voxel size, the higher the spatial resolution. The absolute maximum voxel size for endodontic imaging should be 0.2 mm.⁶⁸ Units typically use voxel sizes of 0.075 to 0.16 mm for their native image capture.

Indications and Special Applications

The American Association of Endodontists (AAE) and the American Academy of Oral and Maxillofacial Radiology (AAOMR) wrote a joint position paper in 2011.⁶⁹ They made several evidence-based guidelines for CBCT use in endodontic patient care.

- 2D Imaging remains the initial imaging procedure of choice. Endodontic diagnosis depends on evaluation of the patient's chief complaint, the medical and dental history, and the clinical and radiographic examination. According to these AAE/AAOMR recommendations, 2D intraoral imaging remains the imaging procedure of choice for these initial evaluations and most endodontic imaging needs.

Only if the 2D evaluation leaves the diagnosis or the treatment in question does CBCT with its advanced capabilities become indicated. These situations will arise as 2D radiographs have inherent limitations due to the manner in which anatomic structures in three dimensions are compressed onto a 2D image. Interpreting 2D images continues to be a somewhat subjective process. Goldman et al.⁷⁰ showed that the agreement between six examiners was only 47% when evaluating healing of periapical lesions using 2D periapical radiographs.

- Limited FOV CBCT is indicated for cases with contradictory or nonspecific clinical signs and symptoms associated with endodontically untreated or previously treated teeth. CBCT imaging has the ability to detect periapical pathology before it is apparent on 2D radiographs⁷¹ (Figure 1). This capability was validated in clinical studies in which the sensitivity of detecting apical periodontitis on intraoral radiographs versus CBCT images was 20% and 48%, respectively.⁷²

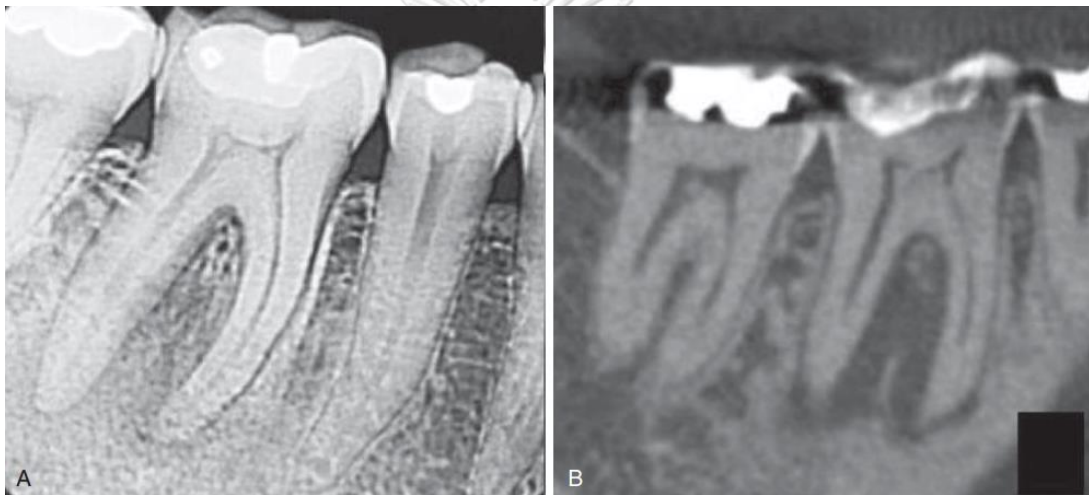

Figure 1. This patient presented with pain to percussion and no response to cold testing on #46. Periodontal probing depths were within normal limits. Root canal therapy was indicated based on the cone beam computed tomography (CBCT) radiographic findings and the clinical tests. A, Periapical radiograph of tooth #46. B, 2D parasagittal CBCT reconstruction. The periapical radiolucency is better delineated demonstrating involvement of the furcation and both the mesial and distal root periapices.

- Limited FOV CBCT should be considered the imaging modality of choice for initial treatment of teeth with the potential for extra canals and suspected complex morphology. The efficacy of CBCT as a modality to accurately explore

tooth anatomy and identify the prevalence of extra or atypical canals is the premise of Recommendation 3. The greater sensitivity at identifying a second mesiobuccal canal in maxillary molars with CBCT in comparison with the gold standard (clinical and histologic sectioning) has been well documented.^{73,74}

- Utilization of Limited FOV CBCT in non-surgical retreatment, surgical treatment planning, assessment of endodontic treatment complications or retreatment of treatment complications: Accurate diagnostic data leads to better treatment decisions and potentially more predictable outcomes.⁷⁵
- Use of limited FOV CBCT to localize root apex/apices and to evaluate the proximity to adjacent anatomic structures. CBCT visualization of periapical disease proximity to vital structures and anatomic landmarks is superior to that of periapical images.

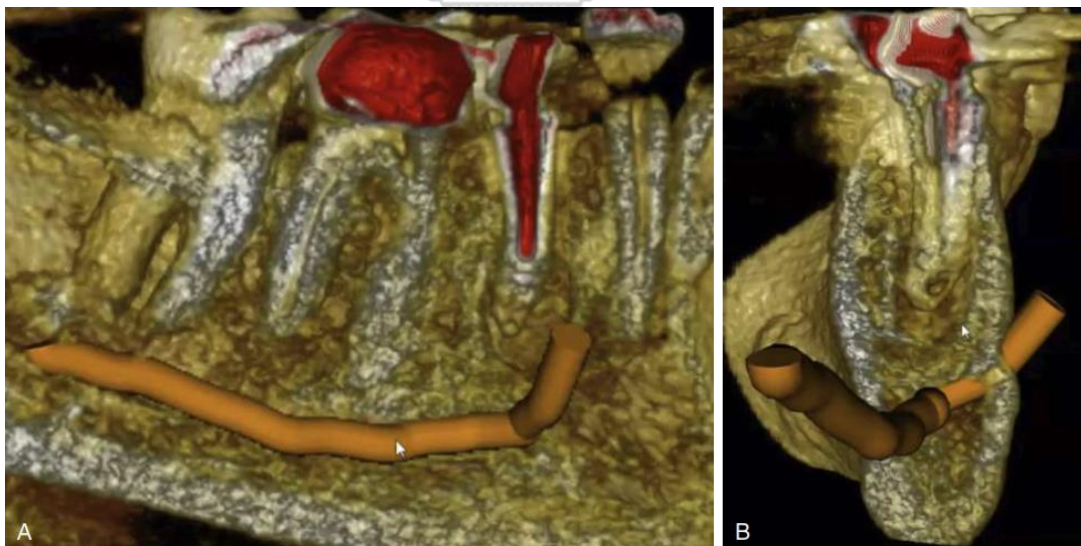


Figure 2. A, 3D rendering demonstrating the relation of the inferior alveolar nerve (IAN) to the periapical defect at the #45 periapical lesion. B, A cropped 3D coronal

rendering demonstrating the mental foramen and the IAN in relation to the base of the periapical defect (arrow). Note the apical root resorption

- Use of CBCT in endodontic diagnosis and detection of resorptive defects
- Use of CBCT in endodontic diagnosis and detection of traumatic dental injuries
- In the 2012 International Association of Dental Traumatology guidelines,⁷⁶ a series of periapical radiographs from different angulations and an occlusal film are recommended for evaluation of traumatic dental injuries. However, 2D imaging has limitations in the evaluation of traumatic dental injuries due to projection geometry, magnification, superimposition of anatomic structures, distortion, and projection errors. The use of CBCT for traumatic dental injuries is now a recommendation of the AAE/AAOMR, particularly traumatic or horizontal root fractures and lateral luxations, for monitoring of healing and or any related complications.

2.3. Vital Pulp therapy

2.3.1 Indications for vital pulp therapy

The penetration of microorganisms and their metabolic products through dentin leads to an inflammation in the pulp. Mediated via cell receptors on odontoblasts, dendritic cells, and pulp fibroblasts, an immune response is initiated. This leads to hyperemia; the reaction is characterized by a decrease in cell number, a flattening of the odontoblasts, and the immigration of lymphocytes and plasma cells.²⁸ Clinically, this correlates with the development of reversible pulpitis, where healing could be facilitated by therapeutic intervention. If the stimulus persists, bacterial colonization in the pulp chamber can be detected, microabscesses and tissue necrosis lined with

polymorphonuclear neutrophilic granulocytes become present, and inflammatory infiltrates are found in the periphery.²⁸ This is considered to be irreversible pulpitis.

Signs of a reversible pulpitis are a positive response to cold sensibility testing with radiating pain. An irreversible pulpitis is diagnosed on the (enhanced) positive sensibility test, on radiating irritant-persistent pain or lingering pain, pain on heat, and possibly on the patient's inability to localize the problem tooth. However, irreversible pulpitis may be asymptomatic. The correct diagnosis of pulp condition before DPC plays an important role in the outcome.

Diagnosis

An accurate clinical/radiographic assessment of pulp vitality is of paramount importance for the correct diagnosis and indication of pulpotomy in cases of young permanent teeth with incomplete root formation. However, this determination of the pulpal condition is more challenging in younger patients.⁷⁷ Establishing a diagnosis of reversible versus irreversible pulpitis in immature teeth can be complicated by subjective symptoms and testing responses that may not accurately reflect pulp histopathology.⁷⁸ A diagnosis of irreversible pulpitis, based on signs and symptoms, along with clinical testing procedures, does not preclude vital pulp therapy options. Regardless of the treatment choice of pulp capping or partial or complete pulpotomy, preservation of the radicular pulp and apical papilla allows for root maturation in cases of trauma or deep caries.⁷⁹⁻⁸²

Patients with deep carious lesions often experience sensitivity to cold, heat, or sweet or acidic foods, and cold tests may evoke a short lingering response of 1 to 2 seconds. This may not be a definitive indicator that the pulp is irreversibly damaged.

Determination of the pulpal condition with the aid of contemporary testing methods can be challenging, even for experienced clinicians, because of possible excessive responses to pulp percussion and palpation testing in children.^{83,84} Cold test has been found more reliable in immature permanent teeth.^{83,85} However, a diagnosis of irreversible pulpitis or pulp necrosis should be considered for teeth that generate pain on percussion. Clinically, the difference between reversible and irreversible pulpitis is often determined on the basis of the duration and intensity of pain. Unprovoked, spontaneous pain of long duration or unrelenting symptoms forcing sleep deprivation are consistent with irreversible pulp inflammation or an acute periapical abscess.

Diagnostic quality intraoral radiographs of the involved tooth must be taken to evaluate accurately the extent of root formation and periradicular or furcation changes associated with the periodontal ligament and supporting bone. Because the faciolingual dimension of most immature roots is greater than the mesiodistal dimension, apical closure may be difficult to determine radiographically.⁸⁶

Another consideration in a patient with displacement trauma is transient apical breakdown, which mimics periapical radiolucencies.⁸⁷ Teeth that experience luxation-type injuries can discolor and may not respond to cold testing for up to 4 months before they recover normal color and vitality. Most clinical investigations clearly indicate that successful outcomes for vital pulp therapy decrease as the patient's age increases. Although aging of the pulp diminishes pulpal volume, vascularity, and host immune responses, functional repair mechanisms can still provide favorable treatment outcomes in older patients.⁸⁸ Hence, the age of the patient seems to play only a minor role in treatment success.⁸⁹⁻⁹⁴

Indication

Maintaining pulp vitality can only be successful if bacterial infection of the tissue during and after the therapy is eliminated. Vital pulp treatments should generally be performed on teeth that do not show pronounced and unprovoked pain symptoms or severe pain on percussion. Vital pulp therapy should not be performed without a response to the sensibility test (in which the pulp status must be verified after pulp exposure) alongside radiographic evidence of periapical disease. In cases diagnosed with irreversible pulpitis, advanced treatment options such as CSC pulpotomy should be considered, especially in younger patients.

The initial pulpal diagnosis can be confirmed after visualization of the exposed pulp and assessed during tissue hemostasis. If no hemorrhaging is seen, this area of the tissue is most likely necrotic and must be removed with a high-speed round diamond bur until bleeding is evident. After hemostasis with NaOCl, a large bulk of CSC can be placed directly against the remaining tissue. Alternatively, if hemorrhage control cannot be achieved after 5 to 10 minutes of direct contact with 3% to 6% NaOCl, the pulp is likely to be irreversibly involved, and a full pulpotomy or pulpectomy is recommended.

In the selection of a specific vital pulp treatment, it is important to consider the remaining tooth structure and future restorative plan. In patients with uncontrolled caries or extensive loss of coronal structure in which full coverage is indicated, pulpotomy rather than pulp capping is recommended.⁹⁵

The introduction of new bioactive materials, along with modified protocols, make more teeth with deep caries, traumatic injuries, and mechanical exposures viable candidates for innovative pulp therapies designed to maintain pulp survival. The

purpose in vital pulp therapy is to avoid or delay root canal treatment and advanced restorative care because these procedures, together, reduce long-term tooth survival compared to teeth with vital pulps.⁹⁶⁻⁹⁸

2.3.2 Procedures generating mineralized tissue barriers

2.3.2.1 Indirect pulp capping

Indirect pulp capping is defined by the American Association for Pediatric Dentistry (AAPD) as “a procedure performed in a tooth with a deep carious lesion approximating the pulp but without signs or symptoms of pulp degeneration. Indirect pulp treatment is indicated in a permanent tooth diagnosed with a normal pulp with no signs or symptoms of pulpitis or with a diagnosis of reversible pulpitis.”⁹⁹ Clinically, during cavity preparation, the demineralized carious tissue is removed and a thin layer of caries is left on the pulpal floor at the deepest site of the cavity, to avoid pulp exposure.

Because only a minimal dentin layer remains above the pulp tissue, there is a risk of irreversible inflammation of the pulp via the dentinal tubules.¹⁰⁰ This can result from remaining bacteria or microorganisms actively entering the tissue and by cytotoxic components from restorative materials diffusing across thin residual dentin. Pulp-nigh dentin should be disinfected and bacteria-sealed with a capping material, stimulating the formation of tertiary dentin.¹⁰¹ The indirect capping thus serves to protect the vital pulp, especially after caries removal. If there is already reversible pulpitis, a favorable environment for pulpal healing should be generated by indirect pulp capping.

Advancing microorganisms and their by-products during the carious process pose a threat to the pulp. Therefore, during caries excavation, the number of microorganisms in the cavity and near the pulp should be reduced, with indirect capping completed under dental dam isolation. To prevent spread of microorganisms, it is recommended to disinfect the clinical crown with NaOCl (1% to 5%) or chlorhexidine digluconate (CHX, 2%) prior to excavation. After caries excavation, the cavity should be cleaned with NaOCl or CHX and water spray.¹⁰² Nevertheless, it remains unclear how much altered dentin can be left while allowing the pulp to heal.¹⁰³ Hence indirect capping materials should eliminate potential residual microorganisms, neutralize any acidic (due to the carious defect) tissues, remineralize dentin, and stimulate the pulp to form tertiary dentin. MTA appears to be more effective than calcium hydroxide for maintaining long-term pulp vitality after indirect pulp capping.¹⁰⁴

2.3.2.2 Direct pulp capping

Direct pulp capping is performed when a small exposure of the pulp is encountered during cavity preparation in teeth with a normal pulp or reversible pulpitis, or following a recently sustained traumatic injury.¹⁰⁵ The aim of this treatment is to maintain pulp vitality by forming a calcified barrier (reparative dentin) to wall off the exposure. When mechanical exposures occur during tooth preparation, the exposed tissue is generally not inflamed. However, in cases of trauma or carious exposure, the degree of inflammation is the key predetermining prognostic factor.

Direct pulp capping should be performed immediately after the exposure to prevent contamination of the pulp. As the extent of the inflammatory process in the pulp cannot be accurately assessed by clinical tests, the diagnosis of reversible pulpitis may

be sometimes incorrect. In some teeth affected by deep caries, pulp inflammation might have reached the stage of irreversible pulpitis without showing clinical signs.

MTA and calcium hydroxide are the most frequently recommended capping materials. The mechanism of action of the two materials in vital pulp treatment are similar, as the main soluble component of MTA is calcium hydroxide.¹⁰⁶ Calcium hydroxide dissolves in an aqueous environment into calcium and hydroxyl ions creating a high pH in the close environment (~12). This alkaline pH is responsible for the antibacterial activity of these materials.¹⁰⁷ The initial effect of calcium hydroxide applied to an exposed pulp tissue is the development of a superficial necrosis as a result of the high pH. This necrosis causes low-grade irritation to the tissue and stimulates the pulp to defense and repair. Contrary to calcium hydroxide, MTA causes mild inflammatory and necrotic changes in the subjacent pulp. Thus it is less caustic than the traditional calcium hydroxide preparations.¹⁰⁸ Calcium ions are released from the capping material, forming inorganic precipitations that have been associated with the mechanism controlling cytological and functional changes in the interacting pulpal cells.⁴²

2.3.2.3 *Partial pulpotomy*

Partial pulpotomy is generally regarded as the treatment of choice for immature teeth with exposed pulp tissue. It is a procedure in which the inflamed pulp tissue beneath an exposure is removed to a depth of one to three millimeters or deeper to reach healthy pulp tissue.² The wound surface is then treated with a capping agent to promote healing and maintain viability of the remaining pulp tissue. Pulp function is preserved, thus allowing dentin bridge generation and natural continued root

development.¹ This goal is achieved by not only sustaining a viable Hertwig's sheath which promotes the root lengthening but also preserving immune cells and odontoblasts which provide the root-wall thickness through dentin formation.¹⁰⁹ In 1978, Cvek first reported that 96% of teeth healed after being treated with partial pulpotomy associated with complicated crown fractures.⁴⁴ The clinical diagnosis of healing was confirmed by histological examination of the pulp after partial pulpotomy.¹¹⁰ Since then, partial pulpotomy has been universally accepted to be applied in traumatically or cariously exposed pulp since this treatment results in favourable treatment outcomes.¹¹¹⁻¹¹⁴

In comparison with cervical pulpotomy, it has been suggested that partial pulpotomy has many advantages, including preservation of the cell-rich coronal pulp tissue, a necessary element for better healing and maintaining the physiologic apposition of dentine in the coronal area.¹¹⁵ Partial pulpotomy also allows better visualization of the working area, compared with full pulpotomy in some typical cases. Meanwhile, cervical pulpotomy removes all the coronal pulp tissue, leaving the crown without the possibility of physiologic apposition of dentine, thereby increasing the risk of cervical fracture. Moreover, a traditional pulpotomy often results in complete obliteration of the root canals, leading to diminished blood supply and then pulp necrosis.¹¹³ Therefore, partial pulpotomy is proved to be a more preferable option for traumatic and carious pulp exposure cases.

Nonetheless, strictly pursuing appropriate criteria is prerequisite for the success of partial pulpotomy. In traumatic cases, the optimal time for treatment is in the first 24 hours when the pulp inflammation is superficial.¹¹⁶ However, inflammation is still confined to the surface 2 to 3 mm of the pulp when traumatically exposed and

left untreated for up to 168 hours.^{117,118} Hence, partial pulpotomy could also be accepted in this situation. For carious cases, the injured teeth should fulfill the following criteria:¹¹⁹

- No pain or short duration of pain that subsided with analgesics
- No reaction to percussion, vestibular swelling, or mobility
- No internal or external resorption or pathologic changes in periodontal ligament or surrounding bone in the radiographic examination
- Pulp exposure during caries removal not exceeding 1 to 2 mm in diameter, with bleeding that stopped within 1 to 2 minutes.¹¹⁹

2.3.2.4 Cervical (full) pulpotomy

Cervical pulpotomy, or complete pulp amputation, is a more intrusive procedure including the removal of the entire coronal portion of the vital pulp to preserve the vitality of the remaining radicular portion. The vital pulp tissue is then capped at the entrance level of the root canal orifice. In mature teeth, this therapy is performed only when irreversible pulpitis is diagnosed, and it should be considered as an emergency treatment. In immature permanent teeth, cervical pulpotomy is performed to allow maturation of the root. This procedure is performed in teeth in which it is assumed that healthy pulp tissue, with a potential to produce a dentin bridge and complete the formation of the root, still remains in the root canal.

The assessment, selection, and amount of tissue removal are dependent on observer experience and completed on a case-by-case basis using magnification. Generally, after necrotic coronal tissue is completely removed, the inflamed pulp can

be partially or completely amputated to the pulp floor or cervical area (pulpotomy) in the case of molars and some premolars.⁸⁰ The AAPD guidelines state, “A pulpotomy is performed in a tooth with extensive caries but without evidence of radicular pathology when caries removal results in a carious or mechanical pulp exposure.”²

2.3.3 Materials for vital pulp therapy

For successful pulp capping outcomes, the removal of noxious stimuli, control of any infection, and the biocompatibility of the capping material are important prerequisites.¹⁰² The presence or absence of microorganisms is the determining factor in the healing of pulp tissue. The tissue reactions following capping (for instance, collagen synthesis and secretion) are those which are expected when connective tissue is wounded.⁴² While excavating a deep caries lesion or during trauma, dentin or pulp tissue areas can be directly exposed, which are particularly permeable due to the structure of dentin. Closer to the pulp chamber, dentinal tubules occur more frequently per square millimeter and have larger diameters than further from the pulp.

Since microorganisms, bacterial toxins (lipopolysaccharides), and many restorative materials can damage the exposed pulp tissue or diffuse via the dentinal tubules, causing irritation, both the pulp and the surrounding dentin should therefore be covered with the indicated capping material. Alternatively, pulp capping materials must create an artificial barrier between the vital pulp and the oral cavity to prevent the ingress of microorganisms. Moreover, the capping material should have antimicrobial properties without being toxic to the pulp. In addition to the disinfection and sealing of dentin, another requirement of the capping material is hard tissue regeneration by pulp

cell induction and thus preservation of pulpal vitality. Medications to treat an exposed pulp should promote the innate capacity of pulpal cells to form hard tissue.⁴²

2.3.3.1 Aqueous calcium hydroxide suspensions

CH has long been considered the universal standard material for vital pulp therapy. Although the material demonstrates many advantageous properties, long-term study outcomes in vital pulp therapy have been inconsistent.¹²⁰⁻¹²³ Desirable characteristics of CH include an initial high alkaline pH, which is responsible for stimulating fibroblasts and enzyme systems. It neutralizes the low pH of acids, shows antibacterial properties, and promotes pulp tissue defense mechanisms and repair. The drawbacks of CH include weak marginal adaptation to dentin, degradation and dissolution over time, and resorption in primary teeth. Histologically, CH demonstrates cytotoxicity in cell cultures and has been shown to induce pulp cell apoptosis.¹²⁴

The slow disintegration of the CH after mineralized tissue formation can allow microleakage, permitting a slow ingress of microorganisms through tunnel defects. This can induce subsequent pulpal degeneration and lead to potential dystrophic calcification and pulp necrosis. Over extended periods, this problematic outcome can complicate any necessary nonsurgical root canal treatment at a later date.¹²⁵

Clinical retrospective investigations have shown variable success rates over 2- to 10-year recall periods for direct CH pulp capping in humans.¹²⁰⁻¹²³ One study included a total of 1,075 permanent teeth directly capped with a calcium hydroxide-based agent. Inclusion criteria were teeth with healthy pulps, pulps with signs of reversible pulpitis, and a pulp chamber roof opening smaller than 2 mm. Pulps with severe degenerative processes or necrosis were excluded. The success rate of direct

capping was 80.1% after 1 year, 68.0% after 5 years, and 58.7% after 9 years.¹²⁶ The results demonstrate increasing failure rates over time, attributable to absorption of the material under permanent restorations proximal to hard tissue bridges with tunnel defects. CH clearly has many favorable characteristics, but it can no longer be considered the preferred agent in vital pulp therapy since MTA provides superior performance and better long-term results as a pulp capping material.^{55,127,128}

2.3.3.2 Hard setting calcium hydroxide cements

In contrast to aqueous CH suspensions, other CH combinations such as cements (calcium salicylate ester cements) as well as liners or putties are less suitable for pulp capping due to a lower release of hydroxyl ions. In these preparations, the resulting pH is lower and the antimicrobial effect is significantly weaker.¹²⁹ In addition, hardening calcium salicylate ester cements are characterized by long-term disintegration.¹³⁰ They also fail to provide permanent support for the final restoration.⁴⁶ New mineralized tissue formation below CH-salicylate ester cements can be slow to generate and be less uniform in shape. Hard tissue regeneration may therefore be weaker using these CH preparations. In addition, inflammation is more common than with CH suspensions. Some additives that harden the CH preparations may even have a toxic effect on the pulp.^{42,46,131} For direct capping or pulpotomy, hard setting CH cements based on calcium salicylate esters cannot be recommended.

2.3.3.3 Mineral trioxide aggregate

MTA was introduced as a pulp capping agent by Torabinejad et al in the mid-1990s. Most preliminary experimental and current clinical data in vital pulp therapy are based on the proprietary material ProRoot MTA . The cement consists of a hydraulic

calcium silicate powder containing oxide compounds, including calcium oxide, ferric oxide, silicon oxide, sodium and potassium oxides, magnesium oxide, and aluminum oxide. Compared with calcium hydroxide-based materials, MTA is more efficient at inducing reparative dentinogenesis in vivo. The available literature suggests that the action of MTA is attributable to the natural wound healing process of exposed pulps, although MTA can stimulate hard-tissue-forming cells to induce matrix formation and mineralization in vitro. Physicochemical analyses have revealed that MTA not only acts as a "calcium hydroxide-releasing" material, but also interacts with phosphate-containing fluids to form apatite precipitates. MTA also shows better sealing ability and structural stability, but less potent antimicrobial activity compared with that of calcium hydroxide.¹³² Soluble cytokines and growth factors that mediate wound repair of the dentin-pulp complex are nested in the extracellular matrix. MTA stimulates reparative hard tissue formation by sequestering these growth factors and cytokines embedded in the surrounding dentin.^{133,134}

CH and calcium silicate hydrate, the principal by-products formed during hydration of mixed MTA, contribute to a sustained alkaline pH.^{135,136} During the setting process, the gradual release of calcium ions encourages reparative barrier formation by promoting signaling molecules, such as VEGF, macrophage colony-stimulating factor, TGF- β , and interleukins IL- β and IL-1 α .^{137,138}

Similar to CH, MTA induces an inflammatory cascade that results from calcium ion release and the creation of an alkaline environment, producing tissue necrosis. MTA activates the migration of progenitor cells (fibroblasts) from the central pulp to the injury site and promotes their proliferation and differentiation into odontoblast-like

cells without inducing pulp cell apoptosis.¹³² MTA also stimulates in vitro the production of messenger RNA and increases protein expression of the mineralized matrix genes and cellular markers crucial for mineralization after matrix formation.

Gray MTA has been shown to enhance cell proliferation and survival of cultured human dental pulp stromal cells.¹³⁸ MTA when placed in direct contact with the cells promoted up-regulated the expression of important odontoblastic genes like osteocalcin and dentin sialoprotein, thereby showing that direct contact of the cells with the MTA is necessary to promote differentiation of the pulp cells into odontoblast-like cells, which in turn are responsible for dentin bridge formation. MTA also induced an increase in the secretion of VEGF when placed in direct contact with the cells.¹³⁹ Odontoblast signaling proteins are essential in the differentiation of progenitor cells into cells responsible for repair and hard tissue deposition.^{138,139} After MTA pulp capping, both sialoprotein and osteopontin have been observed in the mineralized hard tissue matrix at the exposure site during the process of reparative hard tissue formation.¹⁴⁰

Dental pulp cells differentiate into the odontoblastic cell line in the presence of the signaling molecules, such as TGF- β , heme oxygenase-1 enzyme, and bone morphogenetic proteins BMP-2, BMP-4, and BMP-7.¹⁴¹ MTA most likely upregulates fibroblast secretion of BMP-2 and TGF- β 1 and therefore stimulates and promotes mineralization and hard tissue regeneration.¹⁴¹⁻¹⁴³ MTA induced a proinflammatory and pro-wound healing environment through upregulation of a time-dependent proinflammatory cytokine. The biomineralization process occurred simultaneously at the biomaterial-dentin-tissue interface, with the acute inflammatory response. This

promoted the integration of the biomaterial into the environment.¹⁴⁴ MTA does not affect the generation of reactive oxygen species, thereby positively influencing cell survival.

Overall, the data indicate that MTA promotes a biocompatible, noncytotoxic, antibacterial environment and surface morphology that is favorable for reparative calcific bridge formation. MTA stimulates the release of the dentin matrix components necessary for hard tissue repair and regeneration in mechanically exposed healthy and partially inflamed pulps.¹⁴⁵⁻¹⁴⁷

One disadvantage of MTA is that it can lead to discoloration of the hard tooth tissue. This may be problematic, particularly in anterior teeth during trauma management.¹⁴⁸ It is due to heavy metals contained in MTA, such as bismuth oxide used for radiopacity or iron.¹⁴⁹⁻¹⁵¹ The discoloration is mainly induced by the oxidation of these metals after contact with NaOCl or blood components.^{152,153}

2.3.3.4 Calcium silicate cements(CSCs)

A variety of new CSCs have developed since the introduction of MTA. These materials have demonstrated physicochemical and bioinductive properties comparable to MTA, indicating promise for their application in vital pulp therapy.

The main components of MTA and the new CSCs are tricalcium silicate and dicalcium silicate, the major components of Portland cement. Hydraulic tricalcium silicates promote reparative barrier formation by the upregulation of transcription factors after gaining immediate strength on hydration. The cements also encourage hydroxyapatite crystal formation on the cement surface when in contact with calcium-

and phosphate-containing fluids.¹⁵⁴ Moreover, the release of CH from CSCs during hydration has a positive effect on cell regeneration. Osteoblasts, cementoblasts, periodontal ligament cells, and pulp cells are deposited directly on the CSC surface, as the material is recognized as “non-foreign,” which affirms the high biocompatibility of these cements.¹⁵⁵

In addition to CH, silicon is released during CSC cement hardening. The exact function of silicon in the metabolic processes of hard tissue formation is unclear, but it is believed to play a role in the early stages of mineralization.

BioAggregate is a bioinductive tricalcium cement that can induce mineralization in osteoblast cells by increasing levels of osteocalcin, collagen type 1, and osteopontin gene expression.¹⁵⁶

Biodentine is a tricalcium silicate-based cement that also demonstrates exceptional bioactive properties. Whereas MTA is more or less comparable to a refined Portland cement, Biodentine consists mainly of pure tricalcium silicate (about 80%) with calcium carbonate as filler (about 15%). Zirconium oxide is added as radiopacifier (about 5%). Biodentine does not induce genotoxic or cytotoxic effects when measured with the Ames mutagenicity test. It is considered a biocompatible dentin replacement material for use under restorative materials as a base. During setting, Biodentine releases calcium ions forming CH that lead to an alkaline pH in the surrounding tissues, inhibiting the growth of microorganisms.¹⁵⁷ Furthermore, when Biodentine was applied directly onto the pulp, it induced an early form of reparative dentine synthesis, probably due to a modulation of pulp cell TGF-beta1 secretion.¹⁵⁸ In vitro Biodentine induces

proliferation, migration, and differentiation of human dental pulp cells and induces cell proliferation in osteoblasts and periodontal ligament cells.^{159,160}

These factors may explain hard tissue formation after DPC with Biodentine. The material increases biomineralization and encourages hard tissue formation when used as a capping material.¹⁶¹ Histological evaluation in humans revealed complete mineralized tissue formation 6 weeks after DPC with mild to absent pulp inflammatory reactions, comparable to MTA.¹⁶² Success rates of human DPC with Biodentine are between 82.6% and 86% after 1.5 to 2.3 years and thus in the range given for ProRoot MTA.^{62,163-165}

Another promising material for vital pulp therapy is MTA-Angelus, which has a basic formulation of 25% bismuth oxide and 75% Portland cement. The composition eliminates calcium sulfate, providing a short setting time of 15 minutes, preferable for pulp capping or pulpotomy procedures. MTA-Angelus is an effective antifungal agent, and it demonstrates a lower flexural strength than ProRoot MTA.¹⁶⁶⁻¹⁶⁸

Many CSC materials demonstrate acceptable antibacterial products; the most resistant bacteria was *E. faecalis*, which was not susceptible at all, except to Endocem MTA in disc diffusion test.¹⁶⁷ The advantages of these calcium silicate materials over the typically used CH products lie in the higher mechanical strength, lower solubility, and tighter sealing to dentine. Major disadvantages of CH are avoided when using CSCs: dissolution of the capping material as well as the mechanical instability and consequent lack of long-term protection against bacterial microleakage. The new generation of CSCs appear promising when used as vital pulp therapeutic agents, and

current investigations appear to support their future potential and expanded use in vital pulp therapy.

2.3.3.5 Acemannan

Aloe vera L, also known as *Aloe vera Barbadenis*, can be used not only as a natural agent in treatment of skin care such as moisturizing, promoting wound healing, protecting skin from radiation but also as a biological medicament that has anti-inflammatory, antibacterial, antifungal, antiviral and antitumor effects.^{169,170} It demonstrated an importantly biological ability to initiate an immune response against cancerous cells.^{169,171}

Acemannan is a polysaccharide extracted from *Aloe vera* pulp gel through multiple processes including homogenization, centrifugation, alcohol precipitation and lyophilization. It is predominantly comprised of long chain polydispersed β -(1, 4)-linked polymannose, which is highly acetylated according to the mannose monomer/acetyl ratio of approximately 1:1.¹⁷²

As an organic product derived from *Aloe vera*, acemannan generally showed significantly beneficial therapeutic effects. It was reported to accelerate wound healing of biopsy-punch wounds and has defined anti-viral activity against herpes viruses, measles and human immunodeficiency virus.¹⁷³ It also promoted healing of aphthous ulcers in humans¹⁶⁹ and was proved to be an alternative treatment for recurrent aphthous ulcer on patients who prefer non-steroid medication.¹⁷⁴

Recently, a number of both *in vivo* and *in vitro* studies evaluated effects of acemannan on both hard and soft tissue formation and explained the mechanism of

these effects at the molecular level. Some of those were capacities to accelerated alveolar bone, cementum as well as periodontal ligament reconstruction.¹⁷⁵ These periodontal tissues were able to regenerated as the result of acemannan's bioactive activities such as stimulating the proliferation, differentiation and mineralization of periodontal ligament cells (PDL), bone marrow stromal cells (BMSCs). Acemannan was also confirmed to upregulate growth factor and extracellular matrix synthesis, which occupies an important role in the mineral deposition process, through inducing expression of Runx2, GDF-5, BMP-2 in periodontal fibroblasts, VEGF, type I collagen, ALPase activity and mineral deposition.¹⁷⁵⁻¹⁷⁷

Particularly, in dentin formation aspect, acemannan was investigated to trigger the synthesis of BMP-2 in pulpal fibroblasts and then generate the differentiation of these cells into dentin-forming odontoblasts which creates dentin layer later.¹⁷⁶ Another study suggested that acemannan stimulated new DNA synthesis in primary human dental pulp cells (PDPCs), which results in the proliferation of PDPCs.¹⁷⁸ Besides, acemannan enhanced anti-human dentin sialoprotein (DSP) expression, which is considered as an initiator of mineralization,¹⁷⁹ and bone morphogenic protein-2 (BMP-2), which promotes PDPCs differentiation into odontoblast-like cells while activating mineral deposition within the dentin.¹⁷⁸

To summarize, acemannan significantly accelerated new alveolar bone, cementum and periodontal ligament formation in class II furcation defects,¹⁷⁵ promoted bone regeneration in a tooth extraction model,¹⁷⁷ and stimulated dentin formation and pulp healing by reducing inflammation and modulating tissue organization as well as dentine bridge formation.¹⁷⁸

CHAPTER 3

MATERIALS AND METHODS

3.1 Study design and ethical statement

This clinical study will be performed as a clinical controlled trial. It will follow the Consolidated Standards of Reporting Trials (CONSORT).

The study protocol was submitted to and approved by the Ethics Committee of Hanoi National Hospital of Odonto- Stomatology, Vietnam. (Protocol No 217/HĐĐĐ-BVRHMTW. Date:22/07/2015)

3.2 Sample size

The sample size was estimated following the formula of Bouman et al (Figure 3).¹⁸⁰ The success rate of MTA in partial pulpotomy immature permanent molars was 94.4%.¹⁸¹, while the success rate of acemannan in partial pulpotomy immature permanent molars has never been reported. Therefore, the success rate for acemannan was assumed to be not less than that of MTA. Using a 20% non-inferiority limit, 80% test precision, and 5% type I error, the required sample size was 18 teeth per material group. Considering a percentage of 20% drop-out from the study, the sample size was increased to at least 22 eligible teeth for each group.

$$n_A = \kappa n_B \text{ and } n_B = \left(\frac{p_A(1-p_A)}{\kappa} + p_B(1-p_B) \right) \left(\frac{z_{1-\alpha} + z_{1-\beta}}{p_A - p_B - \delta} \right)^2$$

$$1 - \beta = \Phi(z - z_{1-\alpha/2}) + \Phi(-z - z_{1-\alpha/2}) \quad , \quad z = \frac{p_A - p_B - \delta}{\sqrt{\frac{p_A(1-p_A)}{n_A} + \frac{p_B(1-p_B)}{n_B}}}$$

Figure 3. Sample size formula

3.3 Inclusion and exclusion criteria

Inclusion criteria:

Participants will be healthy children with the ages ranged from 6 to 15 years old, good medical health. Their parents allow the subjects to participate in the study. Subjects will be considered eligible if they have a vital immature permanent tooth which has either one of two criteria following:

- Deep carious lesions, which lead to the carious exposed pulp after excavation and diagnosis of reversible pulpitis.
- The teeth have crown fracture that result in pulp exposure after trauma and arrive at the hospital within 48 hours. ^{110,182 183}

Exclusion criteria:

Participants not eligible for the study are those presenting one of the following conditions:

- A history of systemic diseases;

- Clinical signs and symptoms of irreversible pulpitis such as spontaneous throbbing pain, tenderness to percussion, tooth mobility, swelling, or sinus tract;
- Radiographic evidence of internal or external resorption, inter-radicular bone loss, or periapical pathology;
- A non-restorable tooth

After the study begin, the followings will be considered as exclusion criteria:

- Patients who have teeth requiring more than 2 minutes to achieve hemostasis after gently applying moist cotton pellets upon bleeding area during treatment procedure.¹¹⁵
- Patients who does not return for appointments to have clinical and radiographic examination within study period
- Patients who desist from participation in the study for any reason.

During the study, if any symptom of irreversible pulpitis, apical periodontitis, or infection occur, the patients will be offered the appropriate treatment following the institute protocol including regenerative and root canal treatment.

3.4 Study population

All participants will be recruited at the Department of Endodontics and Restoratives, Hanoi National Hospital of Odonto- Stomatology, Vietnam in the period from October 2015 to October 2017. All subjects first will be assessed for the eligibility

criteria. After that, the patients' parents will sign a term of free and informed consent, in which the details of the research are stated before the initiation of clinical procedures.

3.5 Randomization

Participants will be randomly allocated into 2 groups A, B by the envelope draw method. Patients in each group A, B will be treated with MTA and acemannan, respectively.

3.6 Blinding

All recall examinations will be performed by another investigator who is blinded with respect to the type of capping material used.

All periapical radiographs will be examined by an expert who is also blinded regarding the capping materials used.

3.7 Acemannan sponge preparation

Aloe vera (*A. barbadensis* Miller) will be obtained from a local herbal supplier in Thailand. *Aloe vera* will be identified and the specimen will be deposited in the Museum of Natural Medicines, Faculty of Pharmaceutical Sciences, Chulalongkorn University (Bangkok, Thailand).

Acemannan will be extracted as previously described with some modifications. Briefly, fresh mature *Aloe vera* leaves will be washed and the skin will be removed. The *Aloe vera* parenchyma will be washed in running tap water for 30 minutes, and soaked in distilled water for 30 minutes. The parenchyma gels will be homogenized, centrifuged and then alcohol precipitated. The precipitated white opaque

particles will be collected by centrifugation. After lyophilization, the pellets will be ground and kept dry until use.

The molecular weight of the ground powder will be analyzed using high performance liquid chromatography connected to a reflective index detector (RID-10A; Shimadzu, Shimadzu Corporation, Tokyo, Japan). The separation will be performed with a Shodex Sugar KS-804 column and compared with Shodex standard P-82 (Showa Denko K.K., Yokohama, Japan). The monosaccharide compositions will be analyzed using gas chromatography mass spectroscopy and ^{13}C -NMR spectroscopy. The obtained data will be comparable to that of previous studies, indicating that the polysaccharide extracted from fresh *Aloe vera* gel will be acemannan. The yield of acemannan extraction will be approximately 0.04%.

To make acemannan sponges, the acemannan solution of 10% (w/v) will be frozen at -80°C for 16 h, lyophilized for 16 h and sterilized by gamma rays (Thailand Institute of Nuclear Technology, Bangkok, Thailand). All the sponges will be kept in dry condition at room temperature before use.

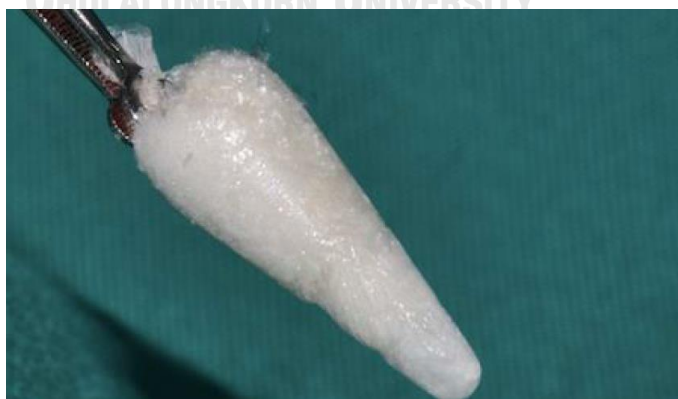

Figure 4. Acemannan sponge

3.8 Intervention

3.8.1 Clinical procedure

Before initiating the treatment procedure, a detailed history of all patients as well as a thorough clinical and radiographic examination will be taken. After the informed consent is signed, the treatment protocol will be initiated. To start with, inferior alveolar nerve block or infiltration of local anesthesia using mepivacaine hydrochloride 3% without vasoconstrictor (Septodont[®], France) will be administered. The tooth will be then isolated with a rubber dam, cleaned with pumice on a rubber cup and washed with 0.12% chlorhexidine. Following the excavation of the infected enamel and dentine, the inflamed pulp tissue will be gently removed following the American Academy of Pediatric Dentistry (AAPD) guideline.² This involves a removal of the superficial inflamed pulp, using an abrasive diamond bur at high-speed with copious sterilized water. After that, the remaining healthy pulp will be rinsed with 2.5% sodium hypochlorite (NaOCl). One or more cotton pellets moistened with saline will be placed over the pulp stumps, and light pressure will be applied for 1–2 minutes to obtain hemostasis. After the hemostasis is achieved, one of two designated materials including MTA or acemannan will be randomly selected to place over the healthy pulp remains. The teeth will then be banded and the permanent restoration will be performed. If there is a continued profuse bleeding found in the amputated-pulp tooth for over 2 minutes, it will be excluded from this study.¹¹⁹

After treatment, a periapical radiograph and CBCT (ProMax 3D; Planmeca, Helsinki, Finland) were immediately taken with ultra-low dose mode (90 kVp, 5.6 mA, and 4 s) to serve as the baseline. The patient will be recalled at 3, 6 and 12 months for clinical and radiographic examination.¹¹³ The clinical examination will include pulp

vitality test using sensitivity response to thermal and pulse oximetry (PO). All recall examinations will be performed by an investigator who will be blinded with respect to the type of capping material used. All radiographs will be examined by an expert who will also be blinded regarding the capping materials used.

3.8.2 Follow-up

The patients and parents were interviewed by phone on day 1 and day 7 post-surgery about any pain or adverse reactions related to the treatment. Paracetamol syrup was prescribed if the patients had pain. No antibiotic was used following the treatment. The patients received a 3-month follow-up clinical and periapical radiographic examination, and 6- and 12-month clinical and CBCT examinations.

The clinical and CBCT examinations were performed by two blinded experienced endodontists. The examiners were trained prior to the study in the evaluation criteria. The clinical examination will include pulp vitality test using sensitivity response to thermal and pulse oximetry (PO). These teeth were examined using pulse oximetry (sat801+, Bitmos, Germany) (Figure 5). When there was a disagreement, both examiners discussed the radiographic findings to achieve a consensus. The intraclass correlation and inter-examiner reliability were 93 and 86%, respectively.

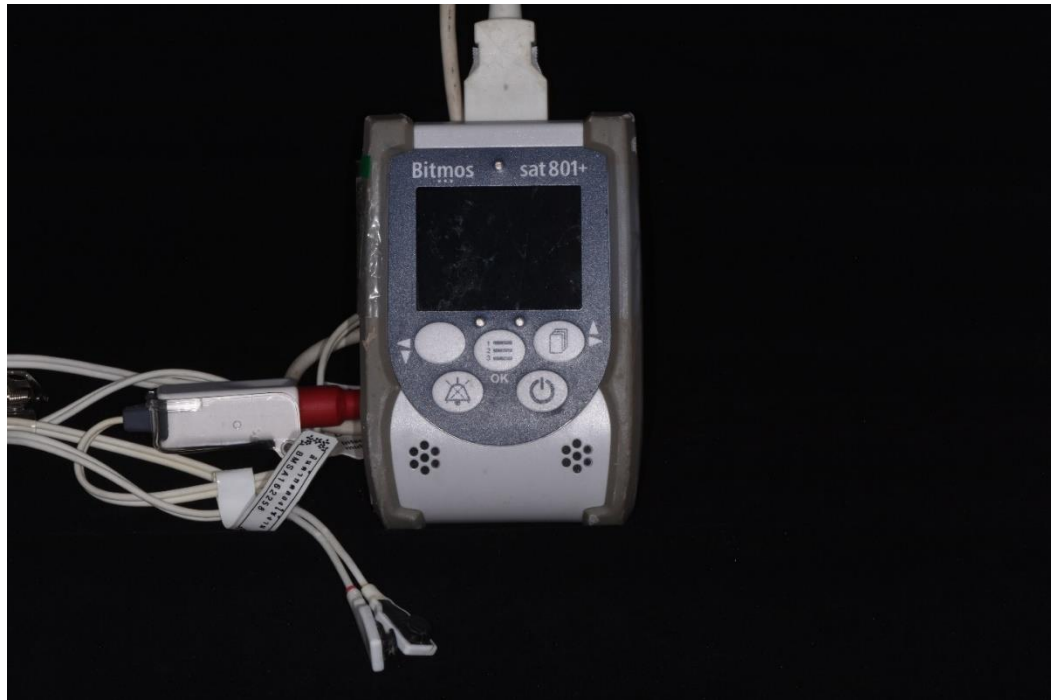

Figure 5. Pulse oximeter

3.8.3 3D tooth reconstruction, and analysis

The data obtained from the CBCT was used to construct the 3D tooth images (Mimics; Materialise, Belgium). A center line (CT line) was created through the center of each root canal. The cemento-enamel junction (CEJ) was generated, and the lowest points of the labial/buccal and lingual/palatal CEJ were used to generate the horizontal plane (CEJ plane). The length of each root was determined from the intersection of the CE line and the CEJ plane to the apical foramen (Figure 6A and B). From the apical view, the apical foramen was located, and measured from the apical foramen area (Figure 6C). The measurements were independently performed three times. If the tooth had more than one root, the mean root length and the mean apical foramen area were calculated to evaluate the changes of those measurements at

immediate, 6- and 12-months post-surgery (Figure 7). The superimposition of the immediate, 6- and 12-months post-surgery 3D tooth images was performed using the 3-Matic program (Materialise, Belgium).

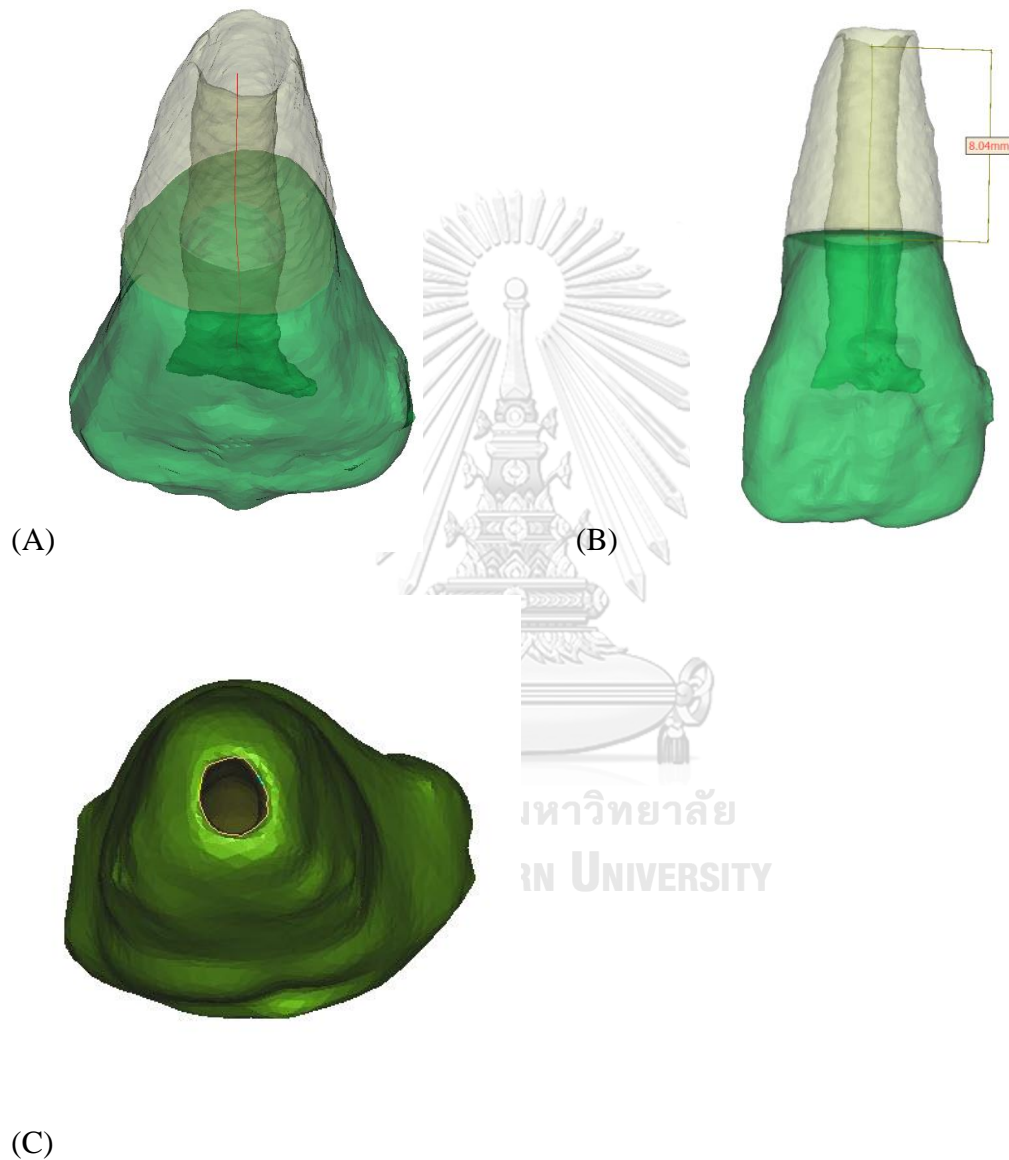


Figure 6. The measurement of root length and apical foramen area of the 3D reconstructed tooth. (A) The center line was created in the center of the root canal. The cementoenamel junction was generated to make the horizontal plane. (B) The

root length was determined from the intersection of the center line and the horizontal plane to the apical foramen. (C). Apical view of the tooth. The apical foramen was outlined and its area was calculated.

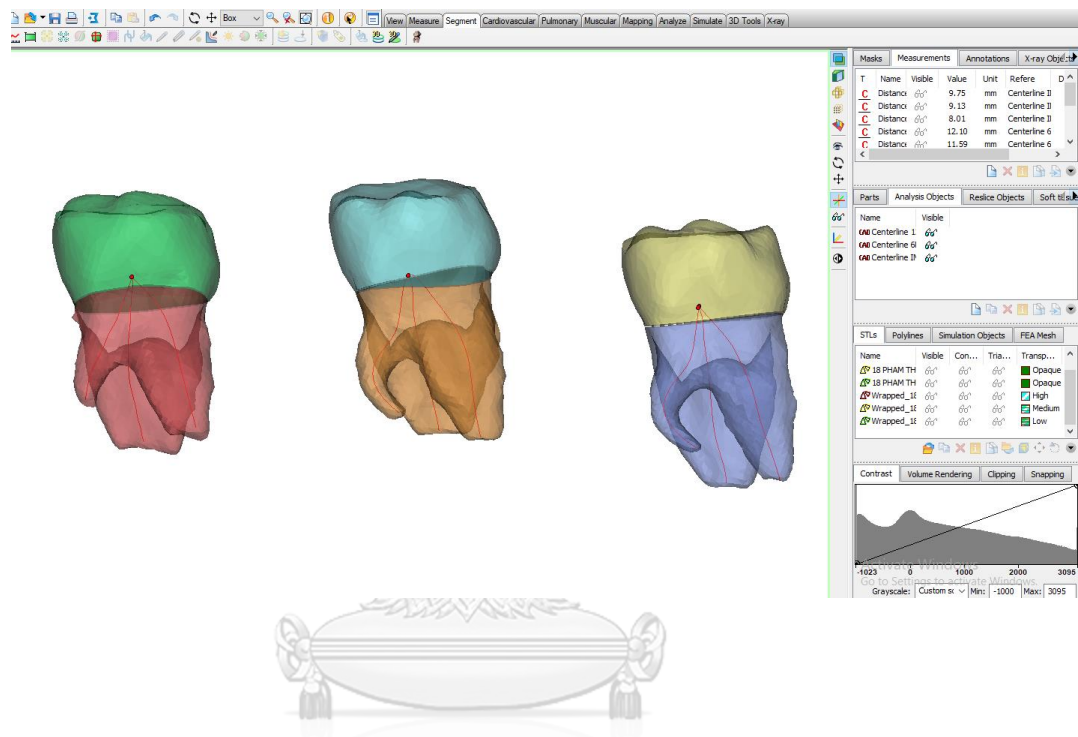


Figure 7. 3D analysis of the reconstructed tooth was done at 3 different observed times: immediate, 6-month, 12-month after surgery

3.9 Outcomes

The criteria for clinical evaluation consists of pain, tenderness to percussion, swelling or abscess, or abnormal tooth mobility. The criteria for radiographic evaluation divides to 1) mild pathologic types (thickening of PDL space and discontinuous of lamina dura) and 2) severe pathologic types (furcation or periapical radiolucency, pathologic external root resorption or internal resorption).

Teeth will be scored as clinical successes if they have no pain either spontaneous or induced by cold, hot, or percussive stimuli; no swelling; no abscess or fistula; and no pathological tooth mobility. ¹⁸⁴

Teeth will be scored as radiographic successes if they show no evidence of periodontal ligament widening, internal resorption, external resorption, inter-radicular bone destruction, or periapical bone destruction. ¹⁸⁴

Periapical bone destruction or periapical radiolucency will be diagnosed if the apical part of the periodontal ligament space is at least twice as wide as in other parts of the root and the lamina dura is absent. ¹⁸⁵

The overall success of treatment in clinic and radiograph will be indicated when absence of any clinical sign and pathologic finding from radiograph. Treatment will be considered as failure when at least one of the clinical signs is presented or the present of severe pathologic finding from radiograph with or without clinical signs.

The radiographic evidence of normal vital activity of the pulp such as continued root growth, physiological narrowing of the pulp chamber and root canals as well as presence of the dentine bridge will also be considered. ^{113,184}

The objective measurements of the root will be done in CBCT image. Root length, apical foramen area and will be measured.

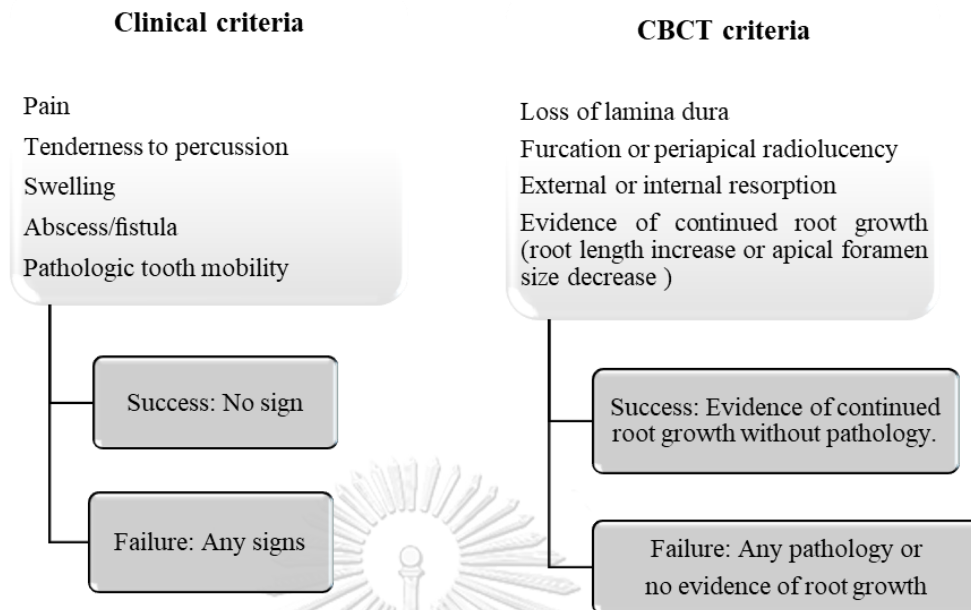


Figure 8. Outcome assessment criteria

3.10 Statistical methods

Statistical analysis will be performed using Statistical Package for Social Sciences version 22.0 (SPSS Inc, Chicago, IL) and the statistician will be blinded to the materials used.

To confirm the reliability of the outcome measurement, 15 teeth will be selected randomly and will be re-measured after the first measurement at least 1 month by the same investigator. The intraclass correlation will be calculated to confirm the reliability of the method.

Descriptive statistics including the mean, standard deviation and range of each group will be shown.

The clinical and radiographic outcome and overall outcome between the MTA and acemannan groups were evaluated and compared using the Fisher exact test. The

mean root length and apical foramen area of each group at baseline, 6-, and 12-month follow-up were calculated and compared using ANOVA repeated measures. A *p* value less than 0.05 was considered significant.



CHAPTER IV

RESULT

4.1 Demographic characteristics

Fifty permanent teeth (23 teeth with trauma exposures and 27 teeth with caries exposures) from 43 patients (23 girls and 20 boys) were used in this study (Table 1). The average age of the patient was 9.2 ± 1.5 (range 7-13) years old. The teeth were randomly divided into an acemannan group (25 teeth: 12 trauma and 13 caries) and an MTA group (25 teeth: 11 trauma and 14 caries) (Table 2, 3). At the 6-month follow-up, 48/50 teeth (24/25 teeth in the acemannan group and 24/25 teeth in the MTA group) from 41 patients (21 girls and 20 boys) were available for clinical and radiographic evaluation. At the 12-month follow-up, 45/48 teeth (22/24 teeth in the acemannan group and 23/24 teeth in the MTA group) from 39 patients (20 girls and 19 boys) were available for clinical and radiographic evaluation. Five teeth (3 acemannan, 2 MTA) from 4 patients were lost to evaluation due to the family moving out of the area. A flowchart of the participants in each stage of the trial is illustrated in Chart 4.

Gender	Number of patients	
	n	%
Male	20	47

Female	23	53
Total	43	100

Table 1. Gender distribution

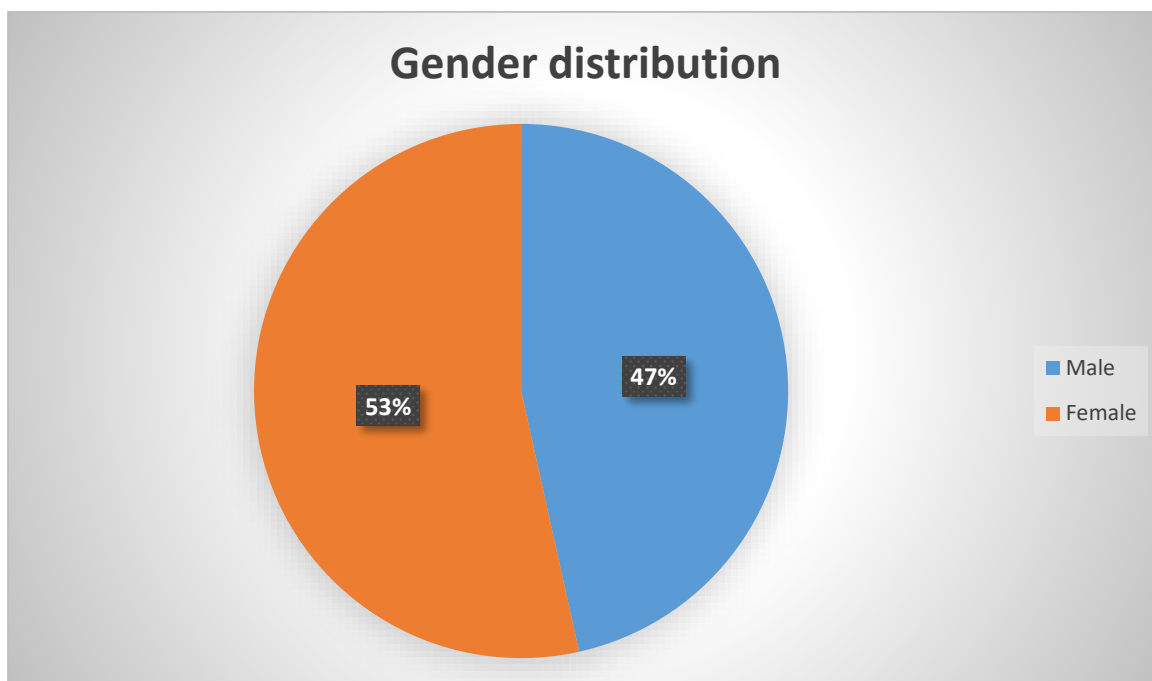


Chart 1. Gender distribution

Group	Number of patients	
	n	%
MTA	25	50
Acemannan	25	50
Total	50	100

Table 2. Group distribution

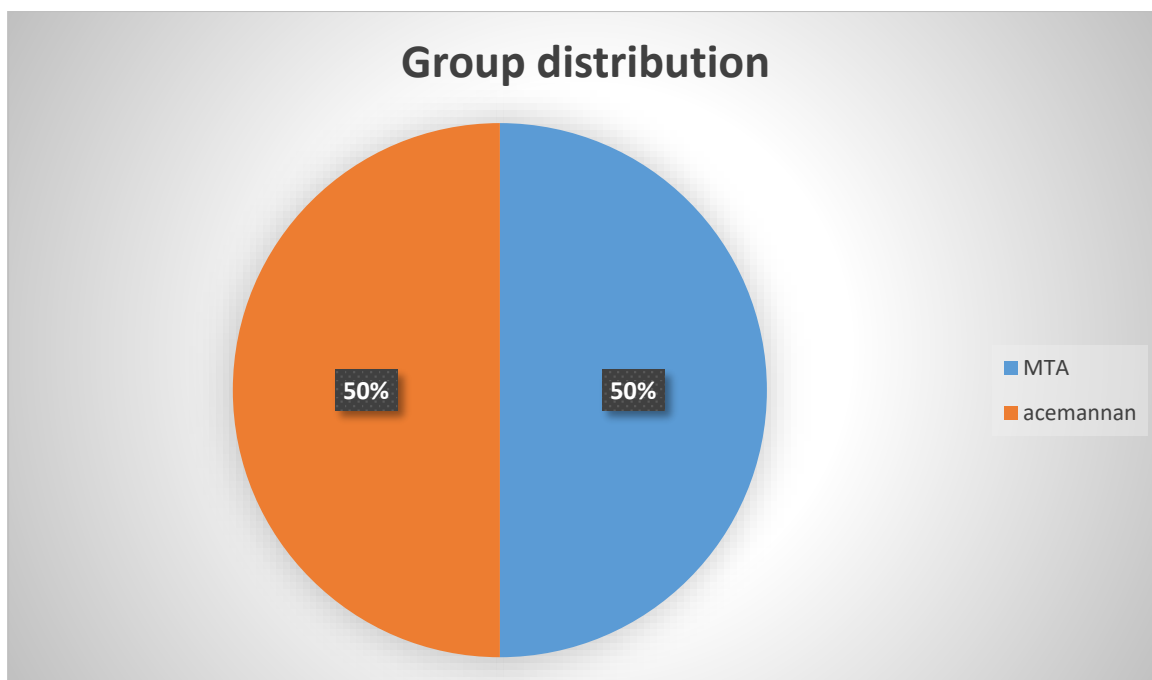


Chart 2. Group distribution

Aetiology	Number of patients	
	n	%
Dental caries	27	54
Trauma	23	46
Total	50	100

Table 3. Aetiology distribution

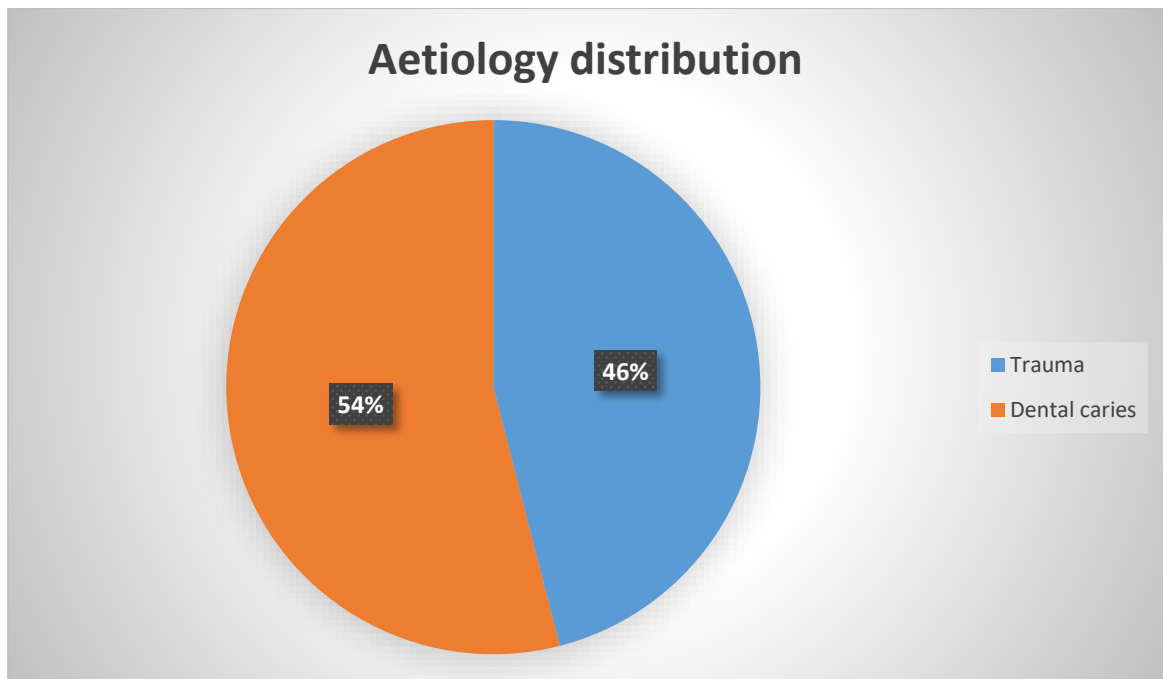


Chart 3. Aetiology distribution

4.2 Evaluation of treatment result

The results of the post-treatment telephone interviews indicated that 3 patients experienced mild pain at day 1. After prescribing paracetamol for pain relief, neither pain nor any adverse effects at day 3 and 7 were reported. The patients with traumatic exposures were re-appointed to evaluate at 4- and 8-weeks post-surgery. The composite splints were removed when the patients passed the evaluation.

At the 6-month follow-up, one patient (trauma case) in the MTA group was diagnosed with irreversible pulpitis due to sharp pain and positive to percussion and a widened periodontal space. One patient (trauma case) in the acemannan group had no symptoms; however, the radiographic evaluation showed a radiolucent area at the tooth apex. Therefore, the clinical success rate, radiographic success rate, and overall

success rate in the acemannan group were 100% (24/24), 95.83% (23/24), and 95.83% (23/24), respectively (Fig. 2). The clinical success rate, radiographic success rate, and overall success rate in the MTA group were 95.83% (23/24), 95.83% (23/24), and 95.83% (23/24), respectively. There was no significant difference between the overall success rates of the acemannan and MTA groups at 6-months post-treatment ($p>0.05$) (Chart 4).

At 12-months post-treatment (from 6 to 12 months), one patient (caries case) in the acemannan group was diagnosed with irreversible pulpitis due to sharp pain and positive to percussion and radiographic evidence of a discontinuous lamina dura of the root. Therefore, the clinical success rate, radiographic success rate, and overall success rate in the acemannan group were 95.45% (21/22), 95.45% (21/22), and 95.45% (21/22), respectively (Chart 4). The clinical success rate, radiographic success rate, and overall success rate in the MTA group were 100% (23/23), 100% (23/23), and 100% (23/23), respectively. There was no significant difference between the overall success rates of the acemannan and MTA groups at 12-months post-treatment ($p>0.05$) (Chart 4).

The total overall success rates of the acemannan and MTA groups from the baseline to 12-month follow-up were 90.91% (20/22) and 95.65% (22/23), respectively (Chart 4). There was no significant difference between the overall success rates in the acemannan and MTA groups from the baseline to the 12-month follow-up ($p>0.05$). The difference between the total overall success rate of each

group was -4.74%, and the 95% confidence interval (CI) was -19.36% and 9.88%.

The lower limit of the 95% CI for the difference between the acemannan and MTA

groups was above the inferiority limit of -20%. Therefore, acemannan was

statistically non-inferior to MTA.

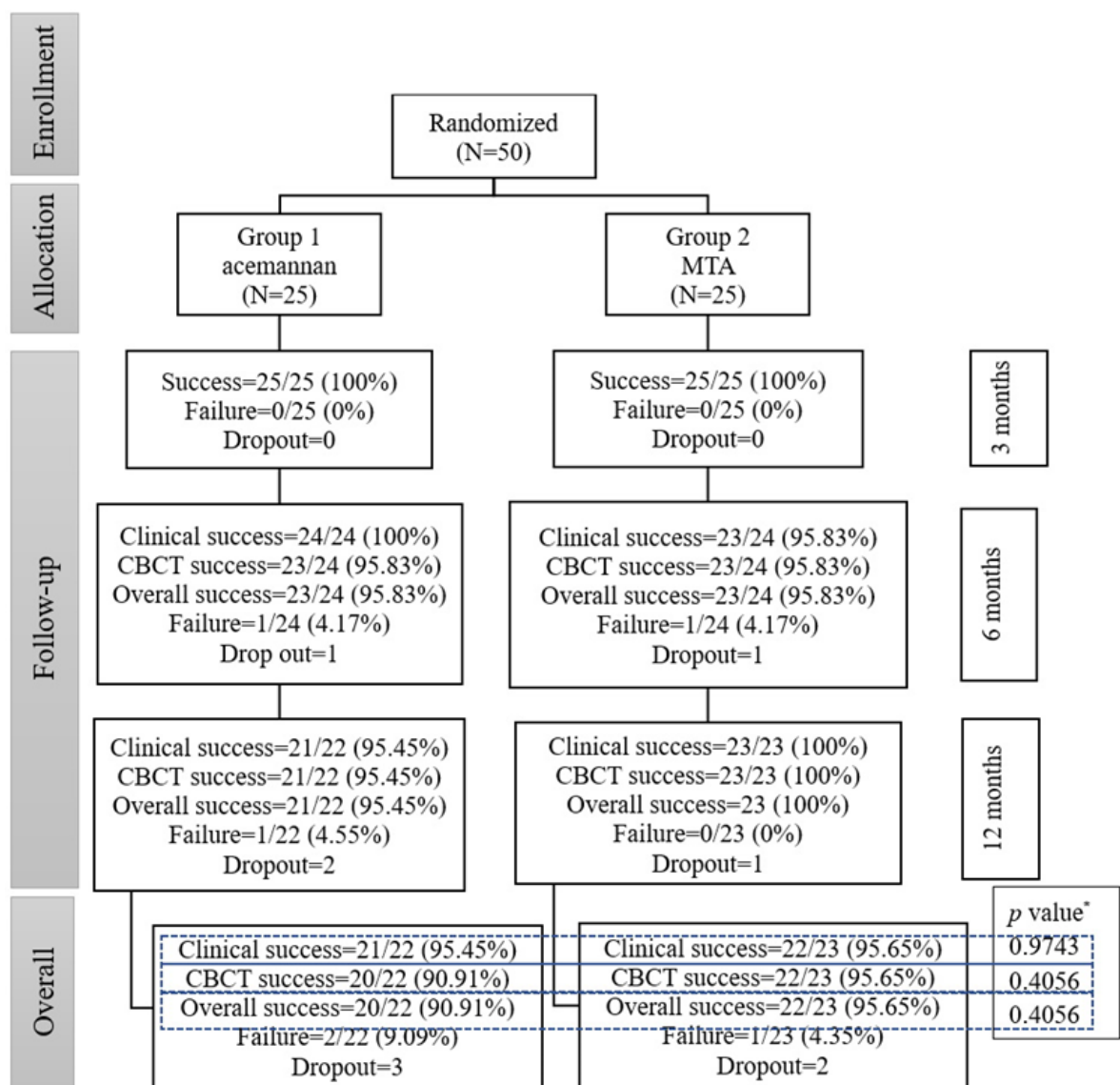


Chart 4. Flowchart of the participants in each stage of the trial

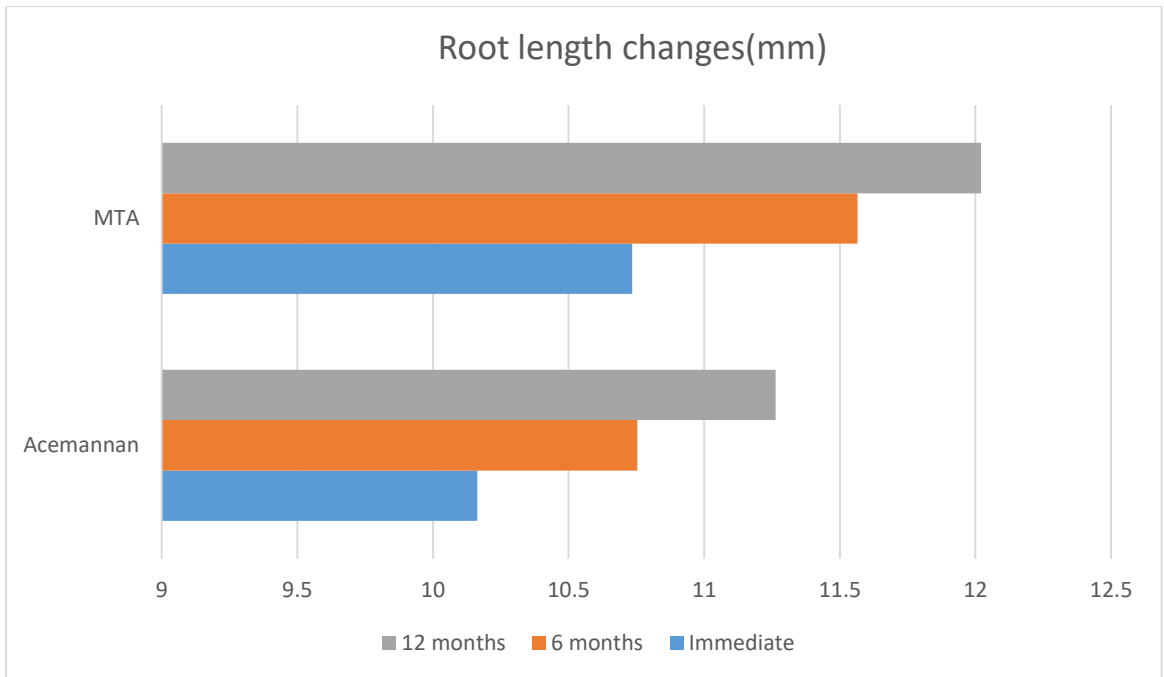


Chart 5. Root length changes in two groups

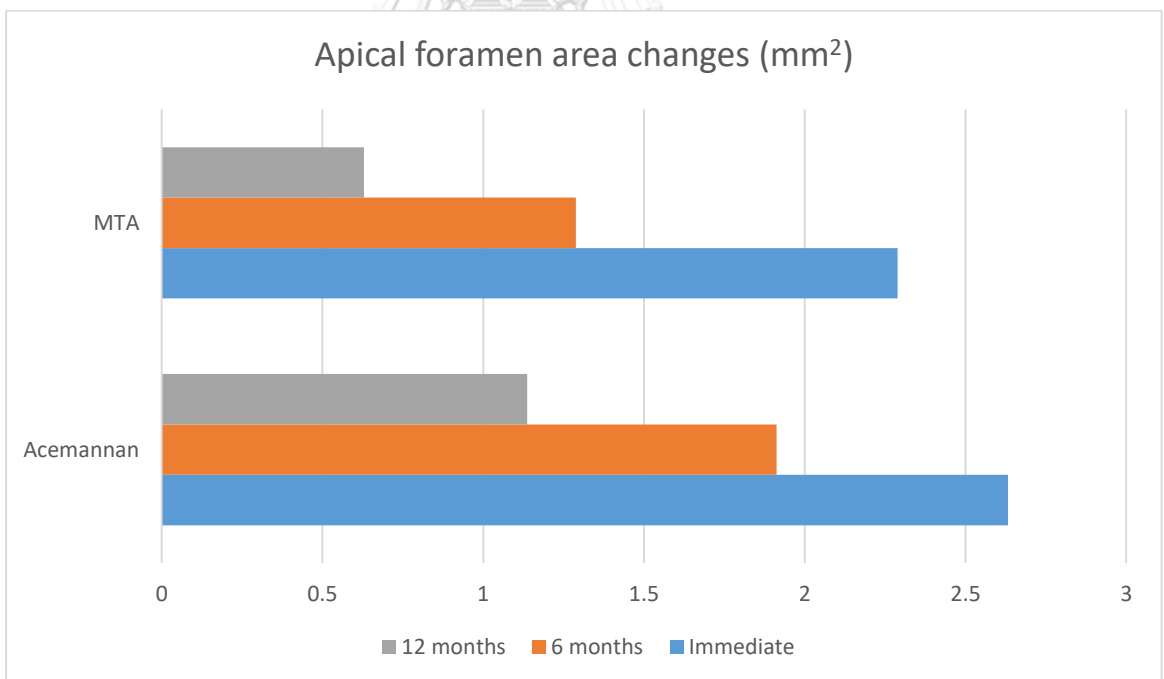
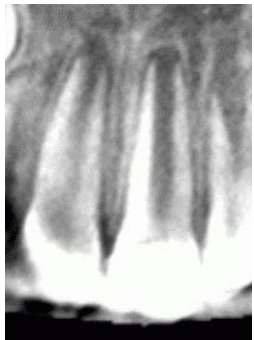
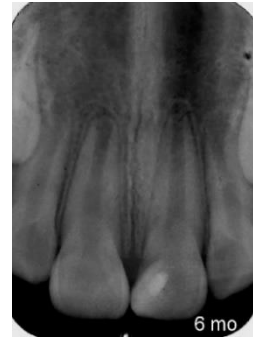
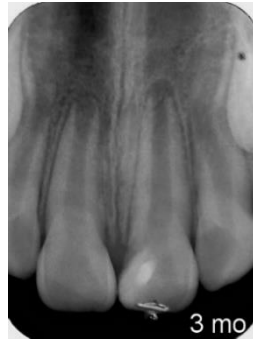
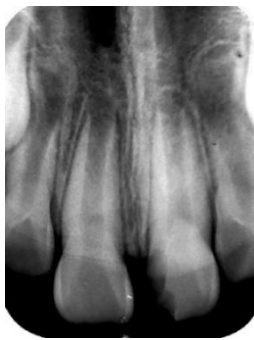Chart 6. Apical foramen area changes in two groups

The mean radiographic root length and apical foramen area in the acemannan and MTA groups at baseline, 6-, and 12-months post-treatment are shown in Table 4. The percentage increase of the mean radiographic root length in the acemannan group at 6- and 12-months post-surgery were 5.81 and 10.82 compared with the baseline value, respectively, and those of the MTA group were 7.72 and 11.98, respectively. A significant increase in the root length in each group was observed at 6- and 12-months post-surgery compared with the baseline value ($p < 0.05$, Table 4A, Chart 5). The apical foramen area in both groups also demonstrated a significant decrease at 6- and 12-months follow up ($p < 0.05$; Table 4B, Chart 6). There was no significant difference in the root length or apical foramen area between the acemannan and MTA groups at the baseline and follow-up evaluations.

A representative superimposed tooth image showing the continued increase in the root length and decreasing apical foramen area is shown in Figure 9, 10, 11.



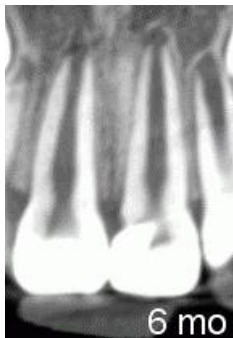A



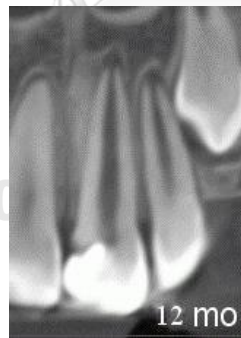
B

C

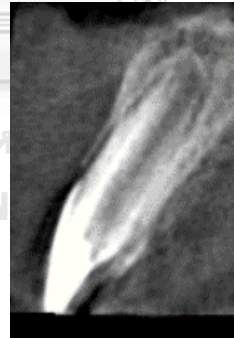
D



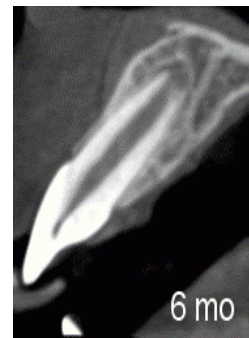
E



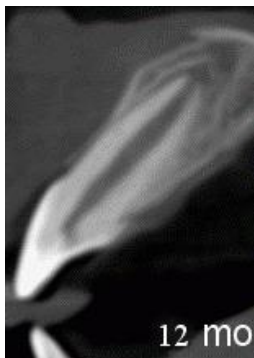F



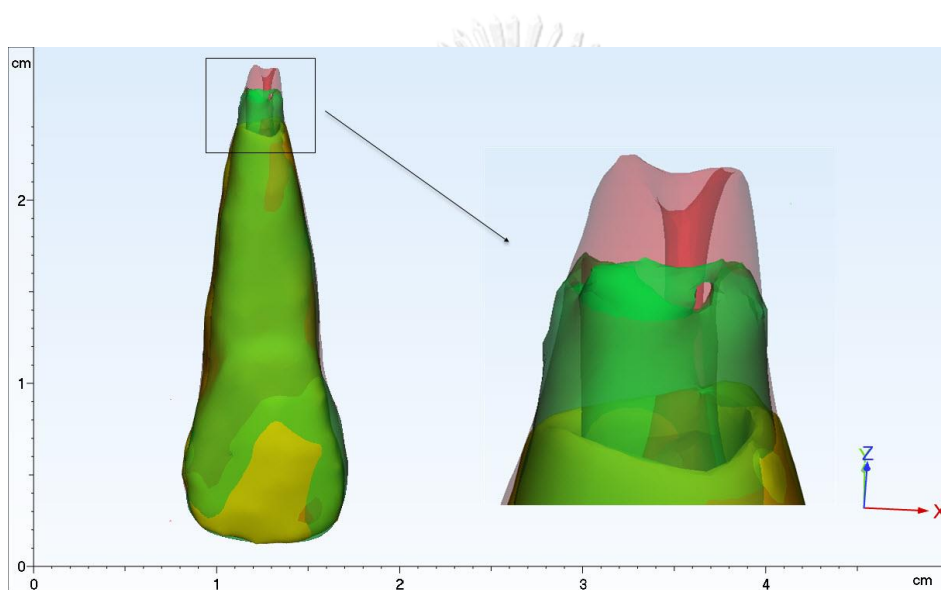
G



H



I



J

จุฬาลงกรณ์มหาวิทยาลัย
CHULALONGKORN UNIVERSITY

Figure 9. Sample case 1. Tooth #21 with pulp exposure due to trauma (A) Diagnostic radiograph. (B-C) Periapical radiograph at 3-month and 6-month follow-ups. (D-F) CBCT sagittal scan at immediate post-treatment at 6-month and 12-month follow-ups. (G-I) CBCT coronal scan at immediate post-treatment at 6-month and 12-month follow-ups. (J) The immediately superimposed 3D tooth (yellow) at 6-month (green) and 12-month post-op (red).

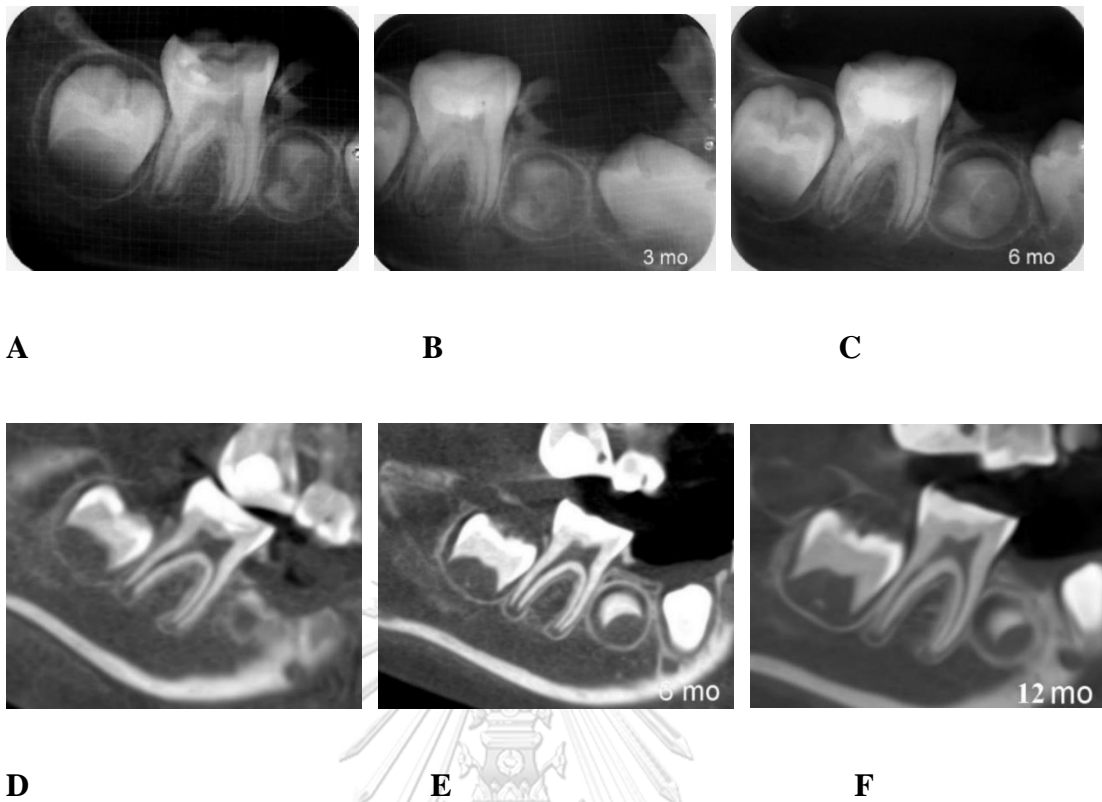
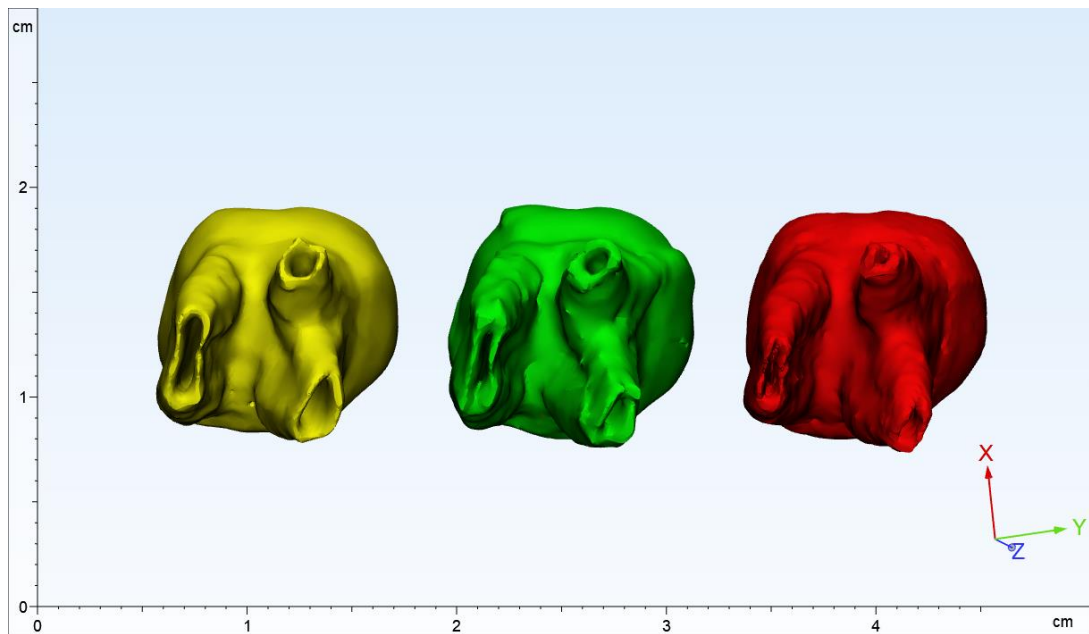
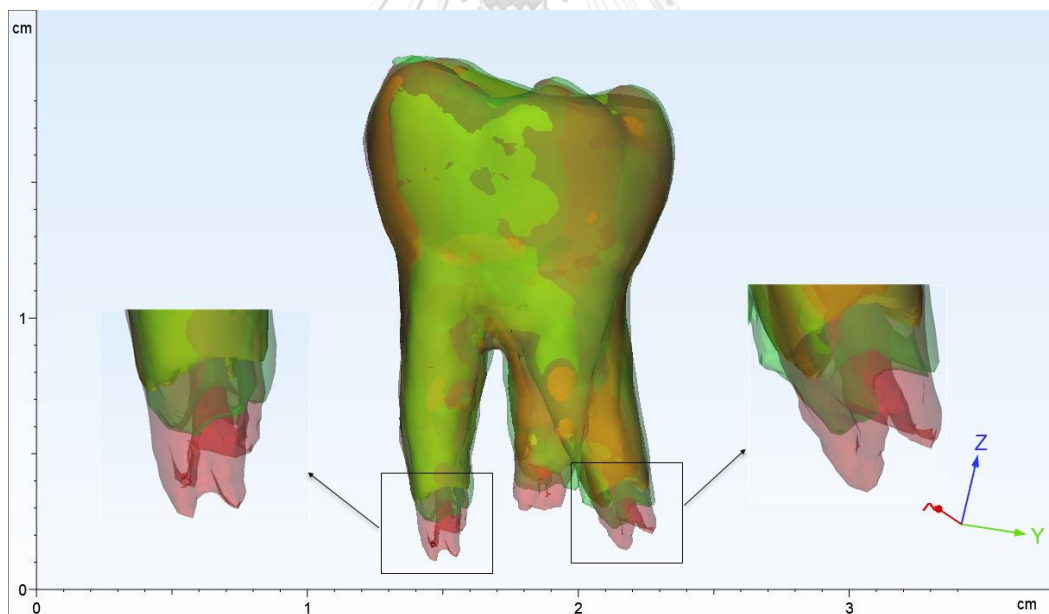


Figure 10. Sample case 2. Tooth #46 had pulp exposure during excavation of dental caries (A) Diagnostic radiograph. (B-C) Periapical radiograph at 3-month and 6-month follow-ups. (D-F) CBCT sagittal scan at immediate post-treatment at 6-month and 12-month follow-ups.

A



B



C

Figure 11. Sample case 2. 3D analysis (A) 3D simulation and analysis at immediate post-op, 6-month post-op, and 12-month post-op (from left to right) (B) The apical

foramen size comparison at immediate (yellow), 6-month (green), and 12-month post-op (red). (C) The superimposed 3D tooth at immediate (yellow), 6-month (green), and 12-month post-op (red).



CHAPTER V

DISCUSSION

Apexogenesis is the goal of vital pulp treatment of immature permanent teeth with open apices for completing root apex formation.⁹⁹ Compared with root canal treatment and conventional pulpotomy, partial pulpotomy has been universally accepted to treat an immature permanent tooth with a traumatic- or caries-induced pulp exposure.¹¹¹ This method conserves the pulp tissue and periapical tissue and maintaining their function to continue root development and dentin formation, resulting in a reduced risk of crown fracture.¹¹⁵ Moreover, in comparison with cervical pulpotomy, it has been suggested that partial pulpotomy has many advantages, including preservation of the cell-rich coronal pulp tissue, a necessary element for better healing and maintaining the physiologic apposition of dentine in the coronal area.¹¹⁵ Partial pulpotomy also allows better visualization of the working area, compared with full pulpotomy in some typical cases. Meanwhile, cervical pulpotomy removes all the coronal pulp tissue, leaving the crown without the possibility of physiologic apposition of dentine, thereby increasing the risk of cervical fracture. Moreover, a traditional vital pulpotomy often results in complete obliteration of the root canals, leading to diminished blood supply and then pulp necrosis.¹¹³ Therefore, partial pulpotomy is proved to be a more preferable option for traumatic and carious pulp exposure cases.

From WHO declaration, people should be received the appropriate treatment without the race or economic restriction. Although MTA and calcium-silicate based

material (Biodentine) are widely used as capping agent for partial pulpotomy¹⁸⁶, the cost of these materials is still high for developing country. Scientists are looking for alternative material with reasonable cost. Although the overall success rate of MTA (95%) was slightly higher compared with the acemannan sponges (91%) at the 12-month follow-up, the success rate of acemannan was not statistically inferior to MTA in this study. The success rate (95%) of MTA in our study corresponds to those in previous studies that report the success rate of MTA in carious- and traumatized-exposure permanent tooth with pulp exposure from 93 to 100%^{60,91,181,187-189}. Bogen et al.⁶⁰ reported the 98% success rate in immature and mature permanent teeth (49 of 53 teeth) at 9 years observation, and all immature teeth (15/15) demonstrated completed root formation. MTA has been proposed as the pulp regenerative material of choice due to its biocompatibility and osteoconductive properties.¹⁸⁶ MTA exhibits favorable physiochemical characteristics that stimulate reparative dentinogenesis by recruiting and activating hard tissue-forming cells, contributing to matrix formation, and mineralization.¹³² MTA also stimulates reparative hard tissue formation by sequestering growth factors and cytokines embedded in the surrounding dentin matrix.¹³⁴

Acemannan is a beta-1,4-polymannose extracted from *Aloe vera* parenchyma. From ¹H- and ¹³C-nuclear magnetic resonance spectroscopy, gas chromatograph-mass spectrometer, and high performance liquid chromatography analysis revealed that acemannan mainly composes of mannose (57-77%), glucose (15-22%), and galactose (5-7%) forming a chain of repeating tetrasaccharide unit: -o-(acetyl mannose)-o-(acetyl mannose)-o-(glucose)-o-(acetyl mannose) with a single-branched galactose at the second or fourth acetylated mannose residue¹⁹⁰⁻¹⁹². The average molecular weight

of acemannan was around 200 kDa¹⁹¹. The acetyl group located on mannose residue has proposed as functional domain of acemannan. The bioactivity of acemannan comes from the 3D architecture of intramolecular and intermolecular structure rather than the building block monosaccharide. The regenerative mechanism of acemannan has not been clearly identified, acemannan has been reported induce pulp healing and dentin formation *in vitro* and *in vivo*.^{6,177} Acemannan stimulates dentin matrix protein expression and growth factor secretion, and mineralization by dental pulp cells.⁵ *In vivo*, acemannan induced pulp healing and reparative dentin formation in LPS-induced reversible pulpitis in canine teeth and caries-exposed reversible pulpitis in human primary teeth.⁶ Similar to MTA treatment, the use of acemannan resulted in histological evidence of mineralized bridge formation with normal underlying pulp tissue without inflammation or pulp necrosis.⁵ In addition, acemannan functions as a 3D scaffold to enhance blood clot formation.⁶ The neighboring odontoblasts, pulpal fibroblasts, and progenitor stem cells in the pulp migrate to the scaffold and generate dentin formation. Our results confirmed that acemannan could be used as an alternative pulp capping material for reversible pulpitis.

Evaluation of pulp status is important step for selecting appropriate vital pulp therapy. An ideal technique should be non-invasive, painless, reliable, standardized, and practical to operation. The traditional methods including electrical pulp test (EPT) and thermal tests, require the sufficient numbers of mature neurons to reach the effective pulp response level. However, due to the fact that both primary and immature permanent teeth are not fully innervated, these methods become less

reliable for pediatric patients ¹⁹³. In addition both EPT and thermal test cause unpleasant stimuli, which may result in uncooperation of children patients and compromise their proper responses to pulp testing ¹⁹⁴. Therefore, EPT and thermal test may be not appropriate to be used in pediatric patients. Recently, the application of pulse oximetry in the diagnosis of pulp status, especially in vital pulp therapy, has been introduced and applied to the newly traumatized permanent teeth in which temporary paresthesia of nerves reduces the effectiveness and reliability of thermal test and EPT approaches. The advantage of this tool lies in its ability to determine the oxygen level (oxygen saturation) in the blood supply of the dental pulp ¹⁹⁵. This is critical since blood supply is the most determinant factor of tissue vitality, especially in vital pulp therapy, which should be regarded as the targeting attempts to assess pulp status ¹⁹⁶. In this study, the electrical pulp test is not included in the evaluation criteria. Although this technique has a high specificity and positive predictive value; its sensitivity and reproducibility are quite low ^{194,197}. This test has been demonstrated to be unreliable and relatively ineffective in primary teeth and immature permanent teeth ¹⁹⁸. False positive responses can occur in anxious and emotional child patients due to anticipating an unpleasant sensation. The immature teeth with incomplete root formation produce a false negative response due to few myelinated nerve fibers in the plexus of Rashkow at the dentin-pulp border. Traumatized teeth also provide false negative results because of nerve rupture and ischemic injury. Therefore, as an auxiliary tool, the pulse oximetry were used in this study along with cold test for pulp vitality test.

CBCT is a radiographic modality that has been proven to be superior to traditional 2D radiographs. Due to CBCT's ability to accurately reproduce the periapical tissues and their three-dimensional relationship to anatomical landmarks, its use is becoming increasingly popular among endodontists¹⁹⁹. Therefore, CBCT can be a powerful tool in endodontic diagnosis, treatment planning, and follow-ups²⁰⁰. With a shorter exposure time (4 sec) and no pain, the child patients cooperate well. However, the radiation dose in CBCT is higher compared with periapical radiographs. In this study, the patients received CBCT examination three times within a year (baseline, 6- and 12-months post-operation) with an ultra-low dose mode for research purposes. For safety, the patients wore lead devices to protect their sensitive tissues; thyroid gland, eye lens, and chest organs from radiation²⁰¹.

Successful vital pulp treatment of immature permanent teeth should result in continued root development as demonstrated by increasing root length and increasing dentin thickness.^{99,202} In some circumstance, such as with nearly complete root formation, apexogenesis can be demonstrated by a narrowing apical foramen. However, this marker has not been used often due to the limitation of 2D radiographs to position the apical foramen; the use of CBCT can overcome this obstacle. Our results revealed that 100% of the successful MTA- and acemannan-treated teeth (45/45) had apical foramen reduction, while only 91.11% of the successful teeth (41/45) showed increasing root length. These findings suggest that a reduced apical foramen area, evaluated via CBCT, can be used as a criterion for apexogenesis, at least, when an increasing root length was undetectable.

The use of CBCT allows for using the same alignment and observation angle of the tooth image at each evaluation time point. However, slight changes/errors in the image angulation obtained at the different time points is unavoidable, resulting in inaccurate and distorted 3D images that can lead to errors in measurement, data interpretation, and comparison between samples.²⁰³ Using the CBCT program, superimposing the 3D tooth images (single-, two- , multiple-roots) at different observation time points allows for comparing and evaluating the continued root formation via root length and apical foramen area. In addition, changes in root morphology, such as size and curvature can be observed. Therefore, this superimposed image can be another useful tool for clinicians to use to evaluate and the patient to understand the treatment outcome. However, the superimposed image construction and analysis still needs to be improved. The process of 3D image superimposition takes time and is technically demanding to perform. Moreover, the contrast and details of the tooth structure can be unclear in the superimposed image due to the colors combine.

The limitation of this study is the restricted observation period of 12-months, which was relatively shorter than that recommended in some studies to evaluate long-term treatment success^{54,204,205}. The success criteria were based on clinical and radiographic data. Although a dentin bridge is considered a favorable response to vital pulp therapy, this cannot be detected in a routine radiograph examination. Some continued root formation of immature permanent teeth receiving vital pulp therapy do not show the formation or increasing thickness of osteodentin bridge formation in conventional radiographs²⁰⁴. Nowika et al. reported that CBCT identified 25 bridges

out of the 37 confirmed by histopathology (67%)²⁰⁵. The similar average density of young dentin and a osteodentin bridge and the artifacts due to the restorations make osteodentin bridge formation difficult to discern radiographically²⁰⁵. In addition, we took the periapical radiograph at 3 month post-op because the Ethic committee would like to make sure the patient can get the new suitable treatment if there is something observed. For the benefit of the patient, waiting for 6 month is risky. In addition, in trauma cases, there have been recommended to take a radiograph at 3 month post-op.



CHAPTER VI

CONCLUSION

Partial pulpotomy is a vital pulp therapy method that is generally regarded as the treatment choice for immature permanent teeth with exposed pulp tissue. Currently, mineral trioxide aggregate (MTA) is widely used as a capping agent for partial pulpotomy. However, this material has some disadvantages, typically long setting time and high cost that *acemannan*, a natural polysaccharide extracted from *aloe vera*, could be an efficient alternative material. Specifically, acemannan would be a promising biomaterial for vital pulp therapy as it is shown to induce mineralized bridge formation in animal and clinical studies.

In this paper, we study, evaluate, and analyze the impacts of MTA and acemannan sponges on partial pulpotomized permanent teeth. In particular, through the clinical success and continued root formation in the apexogenesis procedure, we show that acemannan achieves a comparable efficiency as of the traditional widely used materials, e.g., MTA, in partial pulpotomy, but with a lower cost. Our 12-month follow-up on clinical evaluations and Cone beam computed tomography (CBCT) data showed that MTA (n=23) and acemannan (n=22) have similar success rates on apexogenesis in immature permanent teeth. We also found out that CBCT can provide the data of apical foramen area as a marker of success, which has not been attained due to the limitation of 2D radiographs being used in conventional partial pulpotomy treatment for apical foramen location. The study also suggests that decreasing the apical foramen area could be further applied for evaluations in apexogenesis.

Besides, by utilizing three-dimensional (3D) imaging for the tooth reconstruction design and analyses, we show that although this integrated method of 3D and CBCT has not been clearly considered for vital pulp therapy, particularly in the case of immature permanent teeth, the proposed approach can facilitate the partial pulpotomy treatment with higher accuracy and efficiency, in terms of outcome assessment and follow-ups.

This research study is critical since compared with MTA, acemannan resulted in a non-inferior and comparable success rate with a similar tendency when used as capping material for pulp exposure in immature permanent teeth. Acemannan then realizes a promising alternative to MTA in developing countries, provided that MTA endures high cost and other drawbacks. Together, the proposed 3D superimposition of tooth images at different time points and apical foramen areas would also be used as novel reliable tools for evaluating the partial pulpotomy treatment of immature permanent teeth



จุฬาลงกรณ์มหาวิทยาลัย
CHULALONGKORN UNIVERSITY

REFERENCES



จุฬาลงกรณ์มหาวิทยาลัย
CHULALONGKORN UNIVERSITY

1. Shabahang S. Treatment options: apexogenesis and apexification. *Journal of endodontics*. 2013;39(3 Suppl):S26-29.
2. American Academy on Pediatric Dentistry Clinical Affairs Committee-Pulp Therapy s, American Academy on Pediatric Dentistry Council on Clinical A. Guideline on pulp therapy for primary and young permanent teeth. *Pediatric dentistry*. 2008;30(7 Suppl):170-174.
3. Senthilnathan S. A CASE STUDY ON SAFETY AND EFFICACY OF ALOE VERA EXTRACT IN PRIMARY DYSLIPIDEMIC PATIENTS.
4. Chantarawatit P, Sangvanich P, Banlunara W, Soontornvipart K, Thunyakitpibal P. Acemannan sponges stimulate alveolar bone, cementum and periodontal ligament regeneration in a canine class II furcation defect model. *J Periodontal Res*. 2014;49(2):164-178.
5. Songsiripradubboon S, Kladkaew S, Trairatvorakul C, et al. Stimulation of Dentin Regeneration by Using Acemannan in Teeth with Lipopolysaccharide-induced Pulp Inflammation. *Journal of endodontics*. 2017;43(7):1097-1103.
6. Songsiripradubboon S, Banlunara W, Sangvanich P, Trairatvorakul C, Thunyakitpibal P. Clinical, radiographic, and histologic analysis of the effects of acemannan used in direct pulp capping of human primary teeth: short-term outcomes. *Odontology*. 2016;104(3):329-337.
7. Brannstrom M, Lind PO. Pulpal response to early dental caries. *Journal of dental research*. 1965;44(5):1045-1050.

8. Chogle SM, Goodis HE, Kinaia BM. Pulpal and periradicular response to caries: current management and regenerative options. *Dental clinics of North America*. 2012;56(3):521-536.
9. Lin LM, Rosenberg PA. Repair and regeneration in endodontics. *International endodontic journal*. 2011;44(10):889-906.
10. Morse DR. Age-related changes of the dental pulp complex and their relationship to systemic aging. *Oral surgery, oral medicine, and oral pathology*. 1991;72(6):721-745.
11. Tranasi M, Sberna MT, Zizzari V, et al. Microarray evaluation of age-related changes in human dental pulp. *Journal of endodontics*. 2009;35(9):1211-1217.
12. Morse DR, Esposito JV, Schoor RS. A radiographic study of aging changes of the dental pulp and dentin in normal teeth. *Quintessence international*. 1993;24(5):329-333.
13. Domine L, Holz J. [The aging of the human pulp-dentin organ]. *Schweizer Monatsschrift fur Zahnmedizin = Revue mensuelle suisse d'odontostomatologie = Rivista mensile svizzera di odontologia e stomatologia*. 1991;101(6):725-733.
14. Lee YH, Kim GE, Cho HJ, et al. Aging of in vitro pulp illustrates change of inflammation and dentinogenesis. *Journal of endodontics*. 2013;39(3):340-345.
15. Shiba H, Nakanishi K, Rashid F, et al. Proliferative ability and alkaline phosphatase activity with in vivo cellular aging in human pulp cells. *Journal of endodontics*. 2003;29(1):9-11.

16. Matysiak M, Dubois JP, Ducastelle T, Hemet J. [Morphometric analysis of human pulp myelinated fibers during aging]. *Journal de biologie buccale*. 1986;14(1):69-79.
17. Cohen S. Dentinal pulpal reaction to dental caries. *The Alpha omegan*. 1967;60(2):119-125.
18. Keller JF, Carrouel F, Colomb E, et al. Toll-like receptor 2 activation by lipoteichoic acid induces differential production of pro-inflammatory cytokines in human odontoblasts, dental pulp fibroblasts and immature dendritic cells. *Immunobiology*. 2010;215(1):53-59.
19. Yoshida N, Yoshida K, Nakamura H, Iwaku M, Ozawa H. Immunohistochemical localization of HLA-DR-positive cells in unerupted and erupted normal and carious human teeth. *Journal of dental research*. 1996;75(8):1585-1589.
20. Okamura K, Maeda M, Nishikawa T, Tsutsui M. Dentinal response against carious invasion: localization of antibodies in odontoblastic body and process. *Journal of dental research*. 1980;59(8):1368-1373.
21. Hasler JE, Mitchell DF. Painless pulpitis. *Journal of the American Dental Association*. 1970;81(3):671-677.
22. Mitchell DF, Tarplee RE. Painful pulpitis; a clinical and microscopic study. *Oral surgery, oral medicine, and oral pathology*. 1960;13:1360-1370.
23. Seltzer S, Bender IB, Ziontz M. The dynamics of pulp inflammation: correlations between diagnostic data and actual histologic findings in the pulp. *Oral surgery, oral medicine, and oral pathology*. 1963;16:846-871 contd.

24. Dummer PM, Hicks R, Huws D. Clinical signs and symptoms in pulp disease. *International endodontic journal*. 1980;13(1):27-35.
25. Rodd HD, Boissonade FM. Innervation of human tooth pulp in relation to caries and dentition type. *Journal of dental research*. 2001;80(1):389-393.
26. Rodd HD, Boissonade FM. Vascular status in human primary and permanent teeth in health and disease. *European journal of oral sciences*. 2005;113(2):128-134.
27. Michaelson PL, Holland GR. Is pulpitis painful? *International endodontic journal*. 2002;35(10):829-832.
28. Ricucci D, Loghin S, Siqueira JF, Jr. Correlation between clinical and histologic pulp diagnoses. *Journal of endodontics*. 2014;40(12):1932-1939.
29. Peters DD, Baumgartner JC, Lorton L. Adult pulpal diagnosis. I. Evaluation of the positive and negative responses to cold and electrical pulp tests. *Journal of endodontics*. 1994;20(10):506-511.
30. Petersson K, Soderstrom C, Kiani-Anaraki M, Levy G. Evaluation of the ability of thermal and electrical tests to register pulp vitality. *Endodontics & dental traumatology*. 1999;15(3):127-131.
31. Mainkar A, Kim SG. Diagnostic Accuracy of 5 Dental Pulp Tests: A Systematic Review and Meta-analysis. *Journal of endodontics*. 2018;44(5):694-702.
32. Cohen JS, Reader A, Fertel R, Beck M, Meyers WJ. A radioimmunoassay determination of the concentrations of prostaglandins E2 and F2alpha in painful and asymptomatic human dental pulps. *Journal of endodontics*. 1985;11(8):330-335.

33. Lepinski AM, Hargreaves KM, Goodis HE, Bowles WR. Bradykinin levels in dental pulp by microdialysis. *Journal of endodontics*. 2000;26(12):744-747.
34. Kokkas AB, Goulas A, Varsamidis K, Mirtsou V, Tziafas D. Irreversible but not reversible pulpitis is associated with up-regulation of tumour necrosis factor-alpha gene expression in human pulp. *International endodontic journal*. 2007;40(3):198-203.
35. Bowles WR, Withrow JC, Lepinski AM, Hargreaves KM. Tissue levels of immunoreactive substance P are increased in patients with irreversible pulpitis. *Journal of endodontics*. 2003;29(4):265-267.
36. Awawdeh L, Lundy FT, Shaw C, Lamey PJ, Linden GJ, Kennedy JG. Quantitative analysis of substance P, neurokinin A and calcitonin gene-related peptide in pulp tissue from painful and healthy human teeth. *International endodontic journal*. 2002;35(1):30-36.
37. Nup C, Rosenberg P, Linke H, Tordik P. Quantitation of catecholamines in inflamed human dental pulp by high-performance liquid chromatography. *Journal of endodontics*. 2001;27(2):73-75.
38. Jaber L, Swaim WD, Dionne RA. Immunohistochemical localization of mu-opioid receptors in human dental pulp. *Journal of endodontics*. 2003;29(2):108-110.
39. Tagami J, Hosoda H, Burrow MF, Nakajima M. Effect of aging and caries on dentin permeability. *Proceedings of the Finnish Dental Society Suomen Hammaslaakariseuran toimituksia*. 1992;88 Suppl 1:149-154.

40. About I, Murray PE, Franquin JC, Remusat M, Smith AJ. Pulpal inflammatory responses following non-carious class V restorations. *Operative dentistry*. 2001;26(4):336-342.
41. Cvek M, Granath L, Cleaton-Jones P, Austin J. Hard tissue barrier formation in pulpotomized monkey teeth capped with cyanoacrylate or calcium hydroxide for 10 and 60 minutes. *Journal of dental research*. 1987;66(6):1166-1174.
42. Schroder U. Effects of calcium hydroxide-containing pulp-capping agents on pulp cell migration, proliferation, and differentiation. *Journal of dental research*. 1985;64 Spec No:541-548.
43. Heys DR, Cox CF, Heys RJ, Avery JK. Histological considerations of direct pulp capping agents. *Journal of dental research*. 1981;60(7):1371-1379.
44. Cvek M. A clinical report on partial pulpotomy and capping with calcium hydroxide in permanent incisors with complicated crown fracture. *Journal of endodontics*. 1978;4(8):232-237.
45. Mjor IA, Finn SB, Quigley MB. The effect of calcium hydroxide and amalgam on non-carious, vital dentine. *Archives of oral biology*. 1961;3:283-291.
46. Cox CF, Suzuki S. Re-evaluating pulp protection: calcium hydroxide liners vs. cohesive hybridization. *Journal of the American Dental Association*. 1994;125(7):823-831.
47. Graham L, Cooper PR, Cassidy N, Nor JE, Sloan AJ, Smith AJ. The effect of calcium hydroxide on solubilisation of bio-active dentine matrix components. *Biomaterials*. 2006;27(14):2865-2873.

48. Tomson PL, Grover LM, Lumley PJ, Sloan AJ, Smith AJ, Cooper PR. Dissolution of bio-active dentine matrix components by mineral trioxide aggregate. *J Dent.* 2007;35(8):636-642.
49. Kanjevac T, Milovanovic M, Volarevic V, et al. Cytotoxic effects of glass ionomer cements on human dental pulp stem cells correlate with fluoride release. *Medicinal chemistry.* 2012;8(1):40-45.
50. do Nascimento AB, Fontana UF, Teixeira HM, Costa CA. Biocompatibility of a resin-modified glass-ionomer cement applied as pulp capping in human teeth. *American journal of dentistry.* 2000;13(1):28-34.
51. Costa CA, Giro EM, do Nascimento AB, Teixeira HM, Hebling J. Short-term evaluation of the pulpo-dentin complex response to a resin-modified glass-ionomer cement and a bonding agent applied in deep cavities. *Dental materials : official publication of the Academy of Dental Materials.* 2003;19(8):739-746.
52. Aguilar P, Linsuwanont P. Vital pulp therapy in vital permanent teeth with cariously exposed pulp: a systematic review. *Journal of endodontics.* 2011;37(5):581-587.
53. Swift EJ, Jr., Trope M. Treatment options for the exposed vital pulp. *Practical periodontics and aesthetic dentistry : PPAD.* 1999;11(6):735-739; quiz 740.
54. Barrieshi-Nusair KM, Qudeimat MA. A prospective clinical study of mineral trioxide aggregate for partial pulpotomy in cariously exposed permanent teeth. *Journal of endodontics.* 2006;32(8):731-735.
55. Hilton TJ, Ferracane JL, Mancl L, Northwest Practice-based Research Collaborative in Evidence-based D. Comparison of CaOH with MTA for

- direct pulp capping: a PBRN randomized clinical trial. *Journal of dental research*. 2013;92(7 Suppl):16S-22S.
56. Mente J, Geletneky B, Ohle M, et al. Mineral trioxide aggregate or calcium hydroxide direct pulp capping: an analysis of the clinical treatment outcome. *Journal of endodontics*. 2010;36(5):806-813.
57. Faraco IM, Jr., Holland R. Response of the pulp of dogs to capping with mineral trioxide aggregate or a calcium hydroxide cement. *Dental traumatology : official publication of International Association for Dental Traumatology*. 2001;17(4):163-166.
58. Ford TR, Torabinejad M, Abedi HR, Bakland LK, Kariyawasam SP. Using mineral trioxide aggregate as a pulp-capping material. *Journal of the American Dental Association*. 1996;127(10):1491-1494.
59. Kohli MR, Yamaguchi M, Setzer FC, Karabucak B. Spectrophotometric Analysis of Coronal Tooth Discoloration Induced by Various Bioceramic Cements and Other Endodontic Materials. *Journal of endodontics*. 2015;41(11):1862-1866.
60. Bogen G, Kim JS, Bakland LK. Direct pulp capping with mineral trioxide aggregate: an observational study. *Journal of the American Dental Association*. 2008;139(3):305-315; quiz 305-315.
61. European Society of Endodontology developed b, Duncan HF, Galler KM, et al. European Society of Endodontology position statement: Management of deep caries and the exposed pulp. *International endodontic journal*. 2019;52(7):923-934.

62. Kundzina R, Stangvaltaite L, Eriksen HM, Kerosuo E. Capping carious exposures in adults: a randomized controlled trial investigating mineral trioxide aggregate versus calcium hydroxide. *International endodontic journal*. 2017;50(10):924-932.
63. Kaffe I, Gratt BM. Variations in the radiographic interpretation of the periapical dental region. *Journal of endodontics*. 1988;14(7):330-335.
64. Bender IB, Seltzer S. Roentgenographic and direct observation of experimental lesions in bone: I. 1961. *Journal of endodontics*. 2003;29(11):702-706; discussion 701.
65. Bender IB, Seltzer S. Roentgenographic and direct observation of experimental lesions in bone: II. 1961. *Journal of endodontics*. 2003;29(11):707-712; discussion 701.
66. Deepak BS, Subash TS, Narmatha VJ, Anamika T, Snehil TK, Nandini DB. Imaging techniques in endodontics: an overview. *Journal of clinical imaging science*. 2012;2:13.
67. Durack C, Patel S. Cone beam computed tomography in endodontics. *Brazilian dental journal*. 2012;23(3):179-191.
68. Carter L, Farman AG, Geist J, et al. American Academy of Oral and Maxillofacial Radiology executive opinion statement on performing and interpreting diagnostic cone beam computed tomography. *Oral surgery, oral medicine, oral pathology, oral radiology, and endodontics*. 2008;106(4):561-562.
69. American Association of E, American Academy of O, Maxillofacial R. Use of cone-beam computed tomography in endodontics Joint Position Statement of

- the American Association of Endodontists and the American Academy of Oral and Maxillofacial Radiology. *Oral surgery, oral medicine, oral pathology, oral radiology, and endodontics*. 2011;111(2):234-237.
70. Goldman M, Pearson AH, Darzenta N. Endodontic success--who's reading the radiograph? *Oral surgery, oral medicine, and oral pathology*. 1972;33(3):432-437.
71. de Paula-Silva FW, Wu MK, Leonardo MR, da Silva LA, Wesselink PR. Accuracy of periapical radiography and cone-beam computed tomography scans in diagnosing apical periodontitis using histopathological findings as a gold standard. *Journal of endodontics*. 2009;35(7):1009-1012.
72. Patel S, Wilson R, Dawood A, Mannocci F. The detection of periapical pathosis using periapical radiography and cone beam computed tomography - part 1: pre-operative status. *International endodontic journal*. 2012;45(8):702-710.
73. Michetti J, Maret D, Mallet JP, Diemer F. Validation of cone beam computed tomography as a tool to explore root canal anatomy. *Journal of endodontics*. 2010;36(7):1187-1190.
74. Blattner TC, George N, Lee CC, Kumar V, Yelton CD. Efficacy of cone-beam computed tomography as a modality to accurately identify the presence of second mesiobuccal canals in maxillary first and second molars: a pilot study. *Journal of endodontics*. 2010;36(5):867-870.
75. Liang YH, Li G, Wesselink PR, Wu MK. Endodontic outcome predictors identified with periapical radiographs and cone-beam computed tomography scans. *Journal of endodontics*. 2011;37(3):326-331.

76. Diangelis AJ, Andreasen JO, Ebeleseder KA, et al. International Association of Dental Traumatology guidelines for the management of traumatic dental injuries: 1. Fractures and luxations of permanent teeth. *Dental traumatology : official publication of International Association for Dental Traumatology*. 2012;28(1):2-12.
77. Souza RA, Gomes SC, Dantas Jda C, Silva-Sousa YT, Pecora JD. Importance of the diagnosis in the pulpotomy of immature permanent teeth. *Brazilian dental journal*. 2007;18(3):244-247.
78. Camp JH. Diagnosis dilemmas in vital pulp therapy: treatment for the toothache is changing, especially in young, immature teeth. *Pediatric dentistry*. 2008;30(3):197-205.
79. Fuks AB, Gavra S, Chosack A. Long-term followup of traumatized incisors treated by partial pulpotomy. *Pediatric dentistry*. 1993;15(5):334-336.
80. Fuks AB. Pulp therapy for the primary and young permanent dentitions. *Dental clinics of North America*. 2000;44(3):571-596, vii.
81. Gutmann JL, Heaton JF. Management of the open (immature) apex. 1. Vital teeth. *International endodontic journal*. 1981;14(3):166-172.
82. Shabahang S, Torabinejad M. Treatment of teeth with open apices using mineral trioxide aggregate. *Practical periodontics and aesthetic dentistry : PPAD*. 2000;12(3):315-320; quiz 322.
83. Fulling HJ, Andreasen JO. Influence of maturation status and tooth type of permanent teeth upon electrometric and thermal pulp testing. *Scandinavian journal of dental research*. 1976;84(5):286-290.

84. Karibe H, Ohide Y, Kohno H, et al. [Study on thermal pulp testing of immature permanent teeth]. *Shigaku = Odontology; journal of Nihon Dental College*. 1989;77(3):1006-1013.
85. Fuss Z, Trowbridge H, Bender IB, Rickoff B, Sorin S. Assessment of reliability of electrical and thermal pulp testing agents. *Journal of endodontics*. 1986;12(7):301-305.
86. Kim YJ, Chandler NP. Determination of working length for teeth with wide or immature apices: a review. *International endodontic journal*. 2013;46(6):483-491.
87. Andreasen FM. Transient apical breakdown and its relation to color and sensibility changes after luxation injuries to teeth. *Endodontics & dental traumatology*. 1986;2(1):9-19.
88. Mjor IA. Pulp-dentin biology in restorative dentistry. Part 5: Clinical management and tissue changes associated with wear and trauma. *Quintessence international*. 2001;32(10):771-788.
89. Asgary S, Eghbal MJ, Bagheban AA. Long-term outcomes of pulpotomy in permanent teeth with irreversible pulpitis: A multi-center randomized controlled trial. *American journal of dentistry*. 2017;30(3):151-155.
90. Asgary S, Eghbal MJ, Fazlyab M, Baghban AA, Ghoddusi J. Five-year results of vital pulp therapy in permanent molars with irreversible pulpitis: a non-inferiority multicenter randomized clinical trial. *Clinical oral investigations*. 2015;19(2):335-341.

91. Kang CM, Sun Y, Song JS, et al. A randomized controlled trial of various MTA materials for partial pulpotomy in permanent teeth. *J Dent.* 2017;60:8-13.
92. Linsuwanont P, Wimonstuthikul K, Pothimoke U, Santiwong B. Treatment Outcomes of Mineral Trioxide Aggregate Pulpotomy in Vital Permanent Teeth with Carious Pulp Exposure: The Retrospective Study. *Journal of endodontics.* 2017;43(2):225-230.
93. Marques MS, Wesselink PR, Shemesh H. Outcome of Direct Pulp Capping with Mineral Trioxide Aggregate: A Prospective Study. *Journal of endodontics.* 2015;41(7):1026-1031.
94. Taha NA, Ahmad MB, Ghanim A. Assessment of Mineral Trioxide Aggregate pulpotomy in mature permanent teeth with carious exposures. *International endodontic journal.* 2017;50(2):117-125.
95. Tinanoff N, Douglass JM. Clinical decision making for caries management in children. *Pediatric dentistry.* 2002;24(5):386-392.
96. Caplan DJ, Cai J, Yin G, White BA. Root canal filled versus non-root canal filled teeth: a retrospective comparison of survival times. *Journal of public health dentistry.* 2005;65(2):90-96.
97. Torbjorner A, Karlsson S, Odman PA. Survival rate and failure characteristics for two post designs. *The Journal of prosthetic dentistry.* 1995;73(5):439-444.
98. Caplan DJ, Kolker J, Rivera EM, Walton RE. Relationship between number of proximal contacts and survival of root canal treated teeth. *International endodontic journal.* 2002;35(2):193-199.

99. Guideline on Pulp Therapy for Primary and Immature Permanent Teeth. *Pediatric dentistry*. 2016;38(6):280-288.
100. Murray PE, Smith AJ, Windsor LJ, Mjor IA. Remaining dentine thickness and human pulp responses. *International endodontic journal*. 2003;36(1):33-43.
101. Ricucci D, Loghin S, Lin LM, Spangberg LS, Tay FR. Is hard tissue formation in the dental pulp after the death of the primary odontoblasts a regenerative or a reparative process? *J Dent*. 2014;42(9):1156-1170.
102. Cao Y, Bogen G, Lim J, Shon WJ, Kang MK. Bioceramic Materials and the Changing Concepts in Vital Pulp Therapy. *Journal of the California Dental Association*. 2016;44(5):278-290.
103. Schwendicke F. Contemporary concepts in carious tissue removal: A review. *Journal of esthetic and restorative dentistry : official publication of the American Academy of Esthetic Dentistry [et al]*. 2017;29(6):403-408.
104. Akhlaghi N, Khademi A. Outcomes of vital pulp therapy in permanent teeth with different medicaments based on review of the literature. *Dental research journal*. 2015;12(5):406-417.
105. Cvek M. [Calcium hydroxide in the treatment of traumatized teeth]. *Revue francaise d'endodontie : publication officielle de la Societe francaise d'endodontie*. 1989;8(3):11-27.
106. Parirokh M, Torabinejad M. Mineral trioxide aggregate: a comprehensive literature review--Part I: chemical, physical, and antibacterial properties. *Journal of endodontics*. 2010;36(1):16-27.

107. Tronstad L, Andreasen JO, Hasselgren G, Kristerson L, Riis I. pH changes in dental tissues after root canal filling with calcium hydroxide. *Journal of endodontics*. 1981;7(1):17-21.
108. Witherspoon DE. Vital pulp therapy with new materials: new directions and treatment perspectives--permanent teeth. *Pediatric dentistry*. 2008;30(3):220-224.
109. Rafter M. Apexification: a review. *Dental traumatology : official publication of International Association for Dental Traumatology*. 2005;21(1):1-8.
110. Cvek M, Lundberg M. Histological appearance of pulps after exposure by a crown fracture, partial pulpotomy, and clinical diagnosis of healing. *Journal of endodontics*. 1983;9(1):8-11.
111. P. Chailertvanitkul, J. Paphangkorakit, N. Sooksantisakoonchai, N. Pumas, W. Pairojamornyoot, Abbott NL-aPV. Randomized control trial comparing calcium hydroxide and mineral trioxide aggregate for partial pulpotomies in cariously exposed pulps of permanent molars. *International endodontic journal*. 2014;47:835-842.
112. Mejare I, Cvek M. Partial pulpotomy in young permanent teeth with deep carious lesions. *Endodontics & dental traumatology*. 1993;9(6):238-242.
113. Mass E, Zilberman U. Clinical and radiographic evaluation of partial pulpotomy in carious exposure of permanent molars. *Pediatric dentistry*. 1993;15(4):257-259.
114. Nosrat IV, Nosrat CA. Reparative hard tissue formation following calcium hydroxide application after partial pulpotomy in cariously exposed pulps of permanent teeth. *International endodontic journal*. 1998;31(3):221-226.

115. Fong CD, Davis MJ. Partial pulpotomy for immature permanent teeth, its present and future. *Pediatric dentistry*. 2002;24(1):29-32.
116. Martin Trope, Noah Chivian, Asgeir Sigurdsson, William F.Vann, Jr. Traumatic Injuries. *Pathway of The Pulp*. 2002;eighth edition:603-649.
117. Ashraf F. Fouad, Smith AJ. Protecting the pulp and promoting tooth maturation. *Principles and Practice of Endodontics*. 2015:21-36.
118. M.Hargreaves K. Pediatric endodontics. *Pathway of The Pulp*. 2002;eighth edition:823-833.
119. Mass E, Zilberman U. Long-term radiologic pulp evaluation after partial pulpotomy in young permanent molars. *Quintessence Int*. 2011;42(7):547-554.
120. Horsted P, Sandergaard B, Thylstrup A, El Attar K, Fejerskov O. A retrospective study of direct pulp capping with calcium hydroxide compounds. *Endodontics & dental traumatology*. 1985;1(1):29-34.
121. Barthel CR, Rosenkranz B, Leuenberg A, Roulet JF. Pulp capping of carious exposures: treatment outcome after 5 and 10 years: a retrospective study. *Journal of endodontics*. 2000;26(9):525-528.
122. Baume LJ, Holz J. Long term clinical assessment of direct pulp capping. *International dental journal*. 1981;31(4):251-260.
123. Ausschill TM, Arweiler NB, Hellwig E, Zamani-Alaei A, Sculean A. [Success rate of direct pulp capping with calcium hydroxide]. *Schweizer Monatsschrift fur Zahnmedizin = Revue mensuelle suisse d'odonto-stomatologie = Rivista mensile svizzera di odontologia e stomatologia*. 2003;113(9):946-952.
124. Goldberg M, Lasfargues JJ, Legrand JM. Clinical testing of dental materials--histological considerations. *J Dent*. 1994;22 Suppl 2:S25-28.

125. Mohammadi Z, Dummer PM. Properties and applications of calcium hydroxide in endodontics and dental traumatology. *International endodontic journal*. 2011;44(8):697-730.
126. Willershausen B, Willershausen I, Ross A, Velikonja S, Kasaj A, Blettner M. Retrospective study on direct pulp capping with calcium hydroxide. *Quintessence international*. 2011;42(2):165-171.
127. Eskandarizadeh A, Shahpasandzadeh MH, Shahpasandzadeh M, Torabi M, Parirokh M. A comparative study on dental pulp response to calcium hydroxide, white and grey mineral trioxide aggregate as pulp capping agents. *Journal of conservative dentistry : JCD*. 2011;14(4):351-355.
128. Mente J, Hufnagel S, Leo M, et al. Treatment outcome of mineral trioxide aggregate or calcium hydroxide direct pulp capping: long-term results. *Journal of endodontics*. 2014;40(11):1746-1751.
129. Fisher FJ, McCabe JF. Calcium hydroxide base materials. An investigation into the relationship between chemical structure and antibacterial properties. *British dental journal*. 1978;144(11):341-344.
130. Barnes IE, Kidd EA. Disappearing Dycal. *British dental journal*. 1979;147(5):111.
131. Guven EP, Yalvac ME, Sahin F, Yazici MM, Rizvanov AA, Bayirli G. Effect of dental materials calcium hydroxide-containing cement, mineral trioxide aggregate, and enamel matrix derivative on proliferation and differentiation of human tooth germ stem cells. *Journal of endodontics*. 2011;37(5):650-656.

132. Okiji T, Yoshiba K. Reparative dentinogenesis induced by mineral trioxide aggregate: a review from the biological and physicochemical points of view. *International journal of dentistry*. 2009;2009:464280.
133. Koh ET, Torabinejad M, Pitt Ford TR, Brady K, McDonald F. Mineral trioxide aggregate stimulates a biological response in human osteoblasts. *Journal of biomedical materials research*. 1997;37(3):432-439.
134. Tziafas D, Pantelidou O, Alvanou A, Belibasakis G, Papadimitriou S. The dentinogenic effect of mineral trioxide aggregate (MTA) in short-term capping experiments. *International endodontic journal*. 2002;35(3):245-254.
135. Camilleri J. Characterization of hydration products of mineral trioxide aggregate. *International endodontic journal*. 2008;41(5):408-417.
136. Fridland M, Rosado R. MTA solubility: a long term study. *Journal of endodontics*. 2005;31(5):376-379.
137. Matsumoto S, Hayashi M, Suzuki Y, Suzuki N, Maeno M, Ogiso B. Calcium ions released from mineral trioxide aggregate convert the differentiation pathway of C2C12 cells into osteoblast lineage. *Journal of endodontics*. 2013;39(1):68-75.
138. Paranjpe A, Zhang H, Johnson JD. Effects of mineral trioxide aggregate on human dental pulp cells after pulp-capping procedures. *Journal of endodontics*. 2010;36(6):1042-1047.
139. Paranjpe A, Smoot T, Zhang H, Johnson JD. Direct contact with mineral trioxide aggregate activates and differentiates human dental pulp cells. *Journal of endodontics*. 2011;37(12):1691-1695.

140. Kuratate M, Yoshiba K, Shigetani Y, Yoshiba N, Ohshima H, Okiji T. Immunohistochemical analysis of nestin, osteopontin, and proliferating cells in the reparative process of exposed dental pulp capped with mineral trioxide aggregate. *Journal of endodontics*. 2008;34(8):970-974.
141. Guven G, Cehreli ZC, Ural A, Serdar MA, Basak F. Effect of mineral trioxide aggregate cements on transforming growth factor beta1 and bone morphogenetic protein production by human fibroblasts in vitro. *Journal of endodontics*. 2007;33(4):447-450.
142. D'Anto V, Di Caprio MP, Ametrano G, Simeone M, Rengo S, Spagnuolo G. Effect of mineral trioxide aggregate on mesenchymal stem cells. *Journal of endodontics*. 2010;36(11):1839-1843.
143. Seo MS, Hwang KG, Lee J, Kim H, Baek SH. The effect of mineral trioxide aggregate on odontogenic differentiation in dental pulp stem cells. *Journal of endodontics*. 2013;39(2):242-248.
144. Reyes-Carmona JF, Santos AS, Figueiredo CP, et al. Host-mineral trioxide aggregate inflammatory molecular signaling and biomineralization ability. *Journal of endodontics*. 2010;36(8):1347-1353.
145. Min KS, Park HJ, Lee SK, et al. Effect of mineral trioxide aggregate on dentin bridge formation and expression of dentin sialoprotein and heme oxygenase-1 in human dental pulp. *Journal of endodontics*. 2008;34(6):666-670.
146. Nair PN, Duncan HF, Pitt Ford TR, Luder HU. Histological, ultrastructural and quantitative investigations on the response of healthy human pulps to experimental capping with mineral trioxide aggregate: a randomized controlled trial. *International endodontic journal*. 2008;41(2):128-150.

147. Reyes-Carmona JF, Santos AR, Figueiredo CP, Felipe MS, Felipe WT, Cordeiro MM. In vivo host interactions with mineral trioxide aggregate and calcium hydroxide: inflammatory molecular signaling assessment. *Journal of endodontics*. 2011;37(9):1225-1235.
148. Mozynska J, Metlerski M, Lipski M, Nowicka A. Tooth Discoloration Induced by Different Calcium Silicate-based Cements: A Systematic Review of In Vitro Studies. *Journal of endodontics*. 2017;43(10):1593-1601.
149. Berger T, Baratz AZ, Gutmann JL. In vitro investigations into the etiology of mineral trioxide tooth staining. *Journal of conservative dentistry : JCD*. 2014;17(6):526-530.
150. Dettwiler CA, Walter M, Zaugg LK, Lenherr P, Weiger R, Krastl G. In vitro assessment of the tooth staining potential of endodontic materials in a bovine tooth model. *Dental traumatology : official publication of International Association for Dental Traumatology*. 2016;32(6):480-487.
151. Shokouhinejad N, Nekoofar MH, Pirmoazen S, Shamshiri AR, Dummer PM. Evaluation and Comparison of Occurrence of Tooth Discoloration after the Application of Various Calcium Silicate-based Cements: An Ex Vivo Study. *Journal of endodontics*. 2016;42(1):140-144.
152. Camilleri J. Color stability of white mineral trioxide aggregate in contact with hypochlorite solution. *Journal of endodontics*. 2014;40(3):436-440.
153. Lenherr P, Allgayer N, Weiger R, Filippi A, Attin T, Krastl G. Tooth discoloration induced by endodontic materials: a laboratory study. *International endodontic journal*. 2012;45(10):942-949.

154. Han L, Okiji T. Uptake of calcium and silicon released from calcium silicate-based endodontic materials into root canal dentine. *International endodontic journal*. 2011;44(12):1081-1087.
155. Torabinejad M, Parirokh M. Mineral trioxide aggregate: a comprehensive literature review--part II: leakage and biocompatibility investigations. *Journal of endodontics*. 2010;36(2):190-202.
156. Yuan Z, Peng B, Jiang H, Bian Z, Yan P. Effect of bioaggregate on mineral-associated gene expression in osteoblast cells. *Journal of endodontics*. 2010;36(7):1145-1148.
157. Bhavana V, Chaitanya KP, Gandi P, Patil J, Dola B, Reddy RB. Evaluation of antibacterial and antifungal activity of new calcium-based cement (Biodentine) compared to MTA and glass ionomer cement. *Journal of conservative dentistry : JCD*. 2015;18(1):44-46.
158. Laurent P, Camps J, About I. Biodentine(TM) induces TGF-beta1 release from human pulp cells and early dental pulp mineralization. *International endodontic journal*. 2012;45(5):439-448.
159. Araujo LB, Cosme-Silva L, Fernandes AP, et al. Effects of mineral trioxide aggregate, BiodentineTM and calcium hydroxide on viability, proliferation, migration and differentiation of stem cells from human exfoliated deciduous teeth. *Journal of applied oral science : revista FOB*. 2018;26:e20160629.
160. Pedano MS, Li X, Li S, et al. Freshly-mixed and setting calcium-silicate cements stimulate human dental pulp cells. *Dental materials : official publication of the Academy of Dental Materials*. 2018;34(5):797-808.

161. Zanini M, Sautier JM, Berdal A, Simon S. Biodentine induces immortalized murine pulp cell differentiation into odontoblast-like cells and stimulates biomineralization. *Journal of endodontics*. 2012;38(9):1220-1226.
162. Nowicka A, Lipski M, Parafiniuk M, et al. Response of human dental pulp capped with biodentine and mineral trioxide aggregate. *Journal of endodontics*. 2013;39(6):743-747.
163. Harms CS, Schafer E, Dammaschke T. Clinical evaluation of direct pulp capping using a calcium silicate cement-treatment outcomes over an average period of 2.3 years. *Clinical oral investigations*. 2019;23(9):3491-3499.
164. Jang Y, Song M, Yoo IS, Song Y, Roh BD, Kim E. A Randomized Controlled Study of the Use of ProRoot Mineral Trioxide Aggregate and Endocem as Direct Pulp Capping Materials: 3-month versus 1-year Outcomes. *Journal of endodontics*. 2015;41(8):1201-1206.
165. Lipski M, Nowicka A, Kot K, et al. Factors affecting the outcomes of direct pulp capping using Biodentine. *Clinical oral investigations*. 2018;22(5):2021-2029.
166. Kangarlou A, Sofiabadi S, Asgary S, et al. Assessment of antifungal activity of Proroot mineral trioxide aggregate and mineral trioxide aggregate-Angelus. *Dental research journal*. 2012;9(3):256-260.
167. Kim RJ, Kim MO, Lee KS, Lee DY, Shin JH. An in vitro evaluation of the antibacterial properties of three mineral trioxide aggregate (MTA) against five oral bacteria. *Archives of oral biology*. 2015;60(10):1497-1502.

168. Basturk FB, Nekoofar MH, Gunday M, Dummer PM. Effect of various mixing and placement techniques on the flexural strength and porosity of mineral trioxide aggregate. *Journal of endodontics*. 2014;40(3):441-445.
169. Shamimul Hasan, Sarah Asif, Quadri S. Aloe Vera : General and dental implications- Overview of literature *Journal of Orofacial and Health Sciences* 2014(5(1)):1-5.
170. Priyanka Sharma, Amit C Kharkwal, Harsha Kharkwal, M Z Abdin, Varma A. A review on pharmacological properties of Alovera. *International Journal of Pharmaceutical Sciences Review and Research*. 2014;29(2):31-37.
171. King GK, Yates KM, Greenlee PG, et al. The effect of Acemannan Immunostimulant in combination with surgery and radiation therapy on spontaneous canine and feline fibrosarcomas. *Journal of the American Animal Hospital Association*. 1995;31(5):439-447.
172. Fogleman RW, Chapdelaine JM, Carpenter RH, McAnalley BH. Toxicologic evaluation of injectable acemannan in the mouse, rat and dog. *Veterinary and human toxicology*. 1992;34(3):201-205.
173. Zhang L, Tizard IR. Activation of a mouse macrophage cell line by acemannan: the major carbohydrate fraction from Aloe vera gel. *Immunopharmacology*. 1996;35(2):119-128.
174. Bhalang K, Thunyakitpisal P, Rungsirisatean N. Acemannan, a polysaccharide extracted from Aloe vera, is effective in the treatment of oral aphthous ulceration. *Journal of alternative and complementary medicine*. 2013;19(5):429-434.

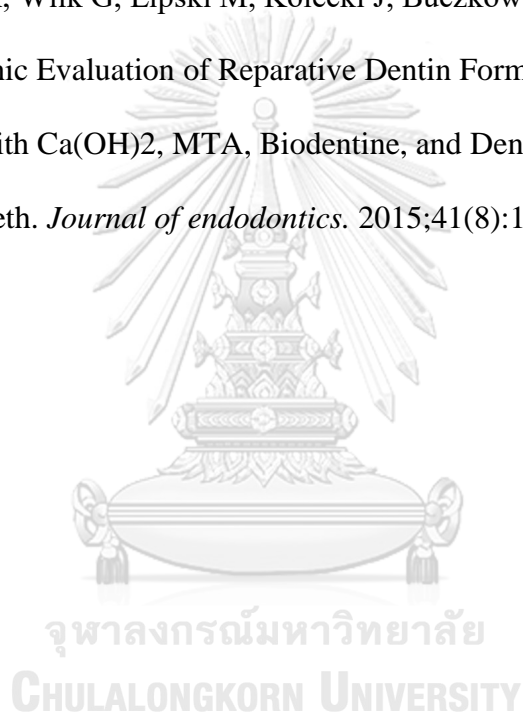
175. Chantarawatit P, Sangvanich P, Banlunara W, Soontornvipart K, Thunyakitpibal P. Acemannan sponges stimulate alveolar bone, cementum and periodontal ligament regeneration in a canine class II furcation defect model. *Journal of periodontal research*. 2014;49(2):164-178.
176. Nawaporn Jittapiromsak, Suwimon Jettanacheawchankit, Peechanika Lardungdee, Polkit Sangvanich, Thunyakitpibal P. Effect of Acemannan on BMP-2 expression in primary pulpal fibroblasts and periodontal fibroblasts, in vitro study. *Journal of Oral Tissue Engineering*. 2007;4(3):149-154.
177. Boonyagul S, Banlunara W, Sangvanich P, Thunyakitpibal P. Effect of acemannan, an extracted polysaccharide from Aloe vera, on BMSCs proliferation, differentiation, extracellular matrix synthesis, mineralization, and bone formation in a tooth extraction model. *Odontology / the Society of the Nippon Dental University*. 2014;102(2):310-317.
178. Jittapiromsak N, Sahawat D, Banlunara W, Sangvanich P, Thunyakitpibal P. Acemannan, an extracted product from Aloe vera, stimulates dental pulp cell proliferation, differentiation, mineralization, and dentin formation. *Tissue engineering Part A*. 2010;16(6):1997-2006.
179. Suzuki S, Sreenath T, Haruyama N, et al. Dentin sialoprotein and dentin phosphoprotein have distinct roles in dentin mineralization. *Matrix biology : journal of the International Society for Matrix Biology*. 2009;28(4):221-229.
180. Bouman AC, ten Cate-Hoek AJ, Ramaekers BL, Joore MA. Sample Size Estimation for Non-Inferiority Trials: Frequentist Approach versus Decision Theory Approach. *PloS one*. 2015;10(6):e0130531.

181. Ozgur B, Uysal S, Gungor HC. Partial Pulpotomy in Immature Permanent Molars After Carious Exposures Using Different Hemorrhage Control and Capping Materials. *Pediatric dentistry*. 2017;39(5):364-370.
182. Heide S, Mjor IA. Pulp reactions to experimental exposures in young permanent monkey teeth. *International endodontic journal*. 1983;16(1):11-19.
183. Ojeda-Gutierrez F, Martinez-Marquez B, Arteaga-Larios S, Ruiz-Rodriguez MS, Pozos-Guillen A. Management and followup of complicated crown fractures in young patients treated with partial pulpotomy. *Case reports in dentistry*. 2013;2013:597563.
184. Keswani D, Pandey RK, Ansari A, Gupta S. Comparative Evaluation of Platelet-rich Fibrin and Mineral Trioxide Aggregate as Pulpotomy Agents in Permanent Teeth with Incomplete Root Development: A Randomized Controlled Trial. *Journal of endodontics*. 2014;40(5):599-605.
185. Bjorndal L, Reit C, Bruun G, et al. Treatment of deep caries lesions in adults: randomized clinical trials comparing stepwise vs. direct complete excavation, and direct pulp capping vs. partial pulpotomy. *European journal of oral sciences*. 2010;118(3):290-297.
186. Mente J, Leo M, Panagidis D, et al. Treatment outcome of mineral trioxide aggregate in open apex teeth. *Journal of endodontics*. 2013;39(1):20-26.
187. El-Meligy OA, Avery DR. Comparison of mineral trioxide aggregate and calcium hydroxide as pulpotomy agents in young permanent teeth (apexogenesis). *Pediatric dentistry*. 2006;28(5):399-404.
188. Parinyaprom N, Nirunsittirat A, Chuveera P, et al. Outcomes of Direct Pulp Capping by Using Either ProRoot Mineral Trioxide Aggregate or

- Biodentine in Permanent Teeth with Carious Pulp Exposure in 6- to 18-Year-Old Patients: A Randomized Controlled Trial. *Journal of endodontics*. 2018;44(3):341-348.
189. Koyuncuoglu G, Gorken FN, Ikikarakayali G, et al. Management of open apices in thirteen traumatized permanent incisors using mineral trioxide aggregate: Case series. *Pediatric Dental Journal*. 2013;23(1):51-56.
190. Tai-Nin Chow J, Williamson DA, Yates KM, Goux WJ. Chemical characterization of the immunomodulating polysaccharide of Aloe vera L. *Carbohydrate research*. 2005;340(6):1131-1142.
191. Chokboribal J, Tachaboonyakiat W, Sangvanich P, Ruangpornvisuti V, Jettanacheawchankit S, Thunyakitpisal P. Deacetylation affects the physical properties and bioactivity of acemannan, an extracted polysaccharide from Aloe vera. *Carbohydrate polymers*. 2015;133:556-566.
192. Jittapiromsak N, Jettanacheawchankit S, Lardungdee P, Sangvanich P, Thunyakitpisal PD. Effect of Acemannan on BMP-2 Expression in Primary Pulpal Fibroblasts And Periodontal Fibroblasts, *in vitro* Study. *Journal of Oral Tissue Engineering*. 2007;4(3):149-154.
193. Goho C. Pulse oximetry evaluation of vitality in primary and immature permanent teeth. *Pediatric dentistry*. 1999;21(2):125-127.
194. Gopikrishna V, Pradeep G, Venkateshbabu N. Assessment of pulp vitality: a review. *International journal of paediatric dentistry*. 2009;19(1):3-15.
195. Mills RW. Pulse oximetry--a method of vitality testing for teeth? *British dental journal*. 1992;172(9):334-335.

196. Bargrizan M, Ashari MA, Ahmadi M, Ramezani J. The use of pulse oximetry in evaluation of pulp vitality in immature permanent teeth. *Dental traumatology : official publication of International Association for Dental Traumatology*. 2016;32(1):43-47.
197. Chen E, Abbott PV. Dental pulp testing: a review. *International journal of dentistry*. 2009;2009:365785.
198. R G, Gopakumar M. Diagnostic Aids in Pediatric Dentistry. *International journal of clinical pediatric dentistry*. 2011;4(1):1-7.
199. Low KM, Dula K, Burgin W, von Arx T. Comparison of periapical radiography and limited cone-beam tomography in posterior maxillary teeth referred for apical surgery. *Journal of endodontics*. 2008;34(5):557-562.
200. Patel S, Durack C, Abella F, Shemesh H, Roig M, Lemberg K. Cone beam computed tomography in Endodontics - a review. *International endodontic journal*. 2015;48(1):3-15.
201. Li G. Patient radiation dose and protection from cone-beam computed tomography. *Imaging science in dentistry*. 2013;43(2):63-69.
202. Mehrvarzfar P, Abbott PV, Mashhadiabbas F, Vatanpour M, Tour Savadkouhi S. Clinical and histological responses of human dental pulp to MTA and combined MTA/treated dentin matrix in partial pulpotomy. *Australian endodontic journal : the journal of the Australian Society of Endodontology Inc*. 2018;44(1):46-53.
203. Meschi N, EzEldeen M, Torres Garcia AE, Jacobs R, Lambrechts P. A Retrospective Case Series in Regenerative Endodontics: Trend Analysis Based

- on Clinical Evaluation and 2- and 3-dimensional Radiology. *Journal of endodontics*. 2018;44(10):1517-1525.
204. Waterhouse PJ, Whitworth JM. *Pediatric Endodontics: Endodontic Treatment for the Primary and Young Permanent Dentition*. In *Cohen's Pathways of the Pulp Expert Consult – E-book, 11st ed.*; Berman, L.H., Hargreaves, K.M. Eds.; Elsevier: St. Louis, Missouri, USA; e1-44. .
205. Nowicka A, Wilk G, Lipski M, Kołdecki J, Buczkowska-Radlińska J. Tomographic Evaluation of Reparative Dentin Formation after Direct Pulp Capping with Ca(OH)₂, MTA, Biodentine, and Dentin Bonding System in Human Teeth. *Journal of endodontics*. 2015;41(8):1234-1240.



VITA

NAME Tien Thuy Vu

DATE OF BIRTH 22 December 1986

PLACE OF BIRTH Vietnam

**INSTITUTIONS
ATTENDED** School of Odonto Stomatology, Hanoi Medical University,
Vietnam

HOME ADDRESS 87 Tran Xuan Soan Street, Hai Ba Trung District, Hanoi,
Vietnam



จุฬาลงกรณ์มหาวิทยาลัย
CHULALONGKORN UNIVERSITY